



ISSN NO. 2320-5407

Journal homepage: <http://www.journalijar.com>

INTERNATIONAL JOURNAL  
OF ADVANCED RESEARCH

## RESEARCH ARTICLE

## Some Clinicopathological and haematological Studies on Copper deficiency in sheep in South Sinai region of Egypt.

Galbat S.A.<sup>1</sup>, Abdel- Fattah, Sh. M<sup>2</sup> and Yehia .H. A<sup>2</sup>

1. Department of Animal Medicine, Assiut University, Faculty of Veterinary Medicine, New Valley branch, New Valley Governorate, Egypt

2. Food Toxins and Contaminants Department, National Research Center, Dokki, Giza, Egypt

### Manuscript Info

#### Manuscript History:

Received: 15 September 2015

Final Accepted: 22 October 2015

Published Online: November 2015

#### Key words:

Copper deficiency – Anemia –  
Clinicopathological –  
Haematological - Sheep - enzootic  
ataxia.

#### \*Corresponding Author

Galbat S.A.

### Abstract

A general complain from the sheep herd owners in South Sinai region of Egypt is enzootic ataxia among sheep raised in the South Sinai was described. Copper (Cu) deficiency was diagnosed in 3 herds of 80, 45, 38 sheep, among of which 6, 3, 2 respectively presented characteristic clinical symptoms of enzootic ataxia. The symptoms began 35 days after birth, with a clinical condition that included difficult locomotion, tremors, limb ataxia, and continual falls. Blood sample was collected to determine plasmatic Cu. The laboratory results showed that the animals presented low copper concentrations in the plasma, without difference between the clinically healthy animals and those affected by enzootic ataxia. Animals clinically affected by enzootic ataxia showed a low number of red blood cells (RBC) and variations in RBC size and shape. The values found for hemoglobin in the Control Group were  $10.77 \pm 0.35$  g.dL<sup>-1</sup> while the levels of the affected by enzootic ataxia Group were  $7.15 \pm 0.35$  g.dL<sup>-1</sup>. The kids from the Problem Group presented an important increase in monocytes, neutrophils and leukocytes, The anemia of these animals was hypochromic and macrocytic.

Copy Right, IJAR, 2015.. All rights reserved

## INTRODUCTION

Copper is one of the most important elements for the development of the embryo and the foetus<sup>1</sup> Insufficiency of this in the pregnant animals inevitably leads to its deficiency in the foetuses (Hidiogrou, et al.,1981). Therefore neonatal enzootic ataxia of the newborn invariably results from grazing pregnant animals in pasture areas poor in copper (Saba et al., 2000). Copper is one of the key trace minerals and is critical for life. Copper is needed for a healthy nervous and immune system and healthy wool development and is stored in a sheep's liver. (Schoenian, 2009). In the low-rainfall areas of Africa and Asia, small ruminant production represents the principal economic output, contributing a large share of the income of farmers (Ben Salem and Smith, 2008); Throughout the tropics, mineral deficiencies and imbalances exert a significant effect on health and productivity of livestock (Aregheore et al., 2007).

Copper is involved in enzymatic activities related to iron metabolism, collagen and elastin formation, melanin and eratin production and the central nervous system integrity (Jones,H. B.et al 1984).

Minerals have been recognized as potent nutrients and deficiency can impair utilization of other nutrients (Szefer and Nriagu, 2007) and thereby animal performance, Minerals play an important role in growth, health and reproduction functions of livestock (Gonul et al., 2009). Consequently, mineral deficiencies and imbalances can affect the productivity of ruminants (Kincaid, 1999).

Suboptimal mineral deficiency that affects growth and production is more serious than the manifested mineral deficiency showing clinical signs that can be corrected (Underwood, 1977). Only rarely can pasture forages completely satisfy all mineral requirements of grazing ruminants (McDowell et al., 1993).

Environmental copper deficiency is due to the presence of molybdenum and sulphates in the soil, which consequently affects the plants. The rumens of these herbivores contain sulphide-generating bacteria that can form thiomolybdate complexes, which naturally have strong affinity for copper ions. Plants with little copper content serve no useful purpose to the animals since these thiomolybdate complexes easily form insoluble super-complexes with this little copper, thereby rendering it unabsorbable (Nederbragt and Wensvoort, 1984; Grace et al., 1999 and Unny, et al., 2002), embryonic and foetal copper deficiency results with the attendant embryonic death or disturbances in the growth of the newborn, pathological changes in the central nervous system, the skeleton and disturbances in metabolism (Widdowson, 1974). Studies in Australia in 1937 established that the enzootic neonatal ataxia in lambs resulted from the pregnant sheep grazing in copper-poor pastures (Bennetts and Chapman, 1937). The neurological disturbances connected with copper deficiency in lambs have been described as 'swayback' (swaying, swinging caused by congenital deficiency of copper), enzootic ataxia (ataxia with a delayed beginning) and cerebral oedema (Cordy, 1971; Chalmers, 1974; Jubb, and Kennedy, 1985; and Geisel, et al., 1997).

Sheep and goats depend on natural forages, salt licks and occasionally commercial supplements for their mineral requirements. However, there is considerable variability in the level of minerals in forages and mineral mixes (Corah, 1996).

Copper is one of the key trace minerals and is critical for life. Copper is needed for a healthy nervous and immune system and healthy wool development and is stored in a sheep's liver. (Schoenian, 2009) Copper is required for the activity of enzymes associated with iron metabolism, elastin and collagen formation, melanin production, and the integrity of the central nervous system. It is required for normal red blood cell formation by allowing iron absorption from the small intestine and release of iron in the tissue into the blood plasma. Ceruloplasmin is the copper-containing transport protein. The process of normal hair and wool pigmentation requires copper. It is believed that copper is a component of polyphenyl oxidase which catalyzes the conversion of tyrosine to melanin and for the incorporation of disulfide groups into keratin in wool and hair. (Blezinger, 2004).

Among the minerals, Cu is an essential microelement that presents a variety of functions in animal organisms. It plays a part in the active center of more than 20 metalloenzymes, cofactors, and metalloproteins that are connected with destruction of free radicals, synthesis of connective tissues, formation of myelin and bones, pigmentation and formation of fur and wool. It also acts indirectly in hematopoiesis (McDowell, 1999 and Ortolani, et al., 2003). Lack or low quantities of copper animal feed may cause a shortage of this microelement (Suttle, 2010). Cu deficiency is taken to be a severe nutritional problem in tropical regions, because of the low Cu concentrations in animals' diets and/or because of high concentrations of elements that are antagonistic towards Cu, such as molybdenum (Mo), sulfur (S), and iron (Fe) (Cardoso et al., 1977 and Marques, et al., 2003).

Low Cu levels have been found in foraging animals and in the livers of ruminants in different regions (McDowell, 1999; Garrick, 2003 and Dos Santos, et al., 2006). Enzootic ataxia is the maximum expression of Cu deficiency in lambs up to the age of 180 days and is characterized by demyelination of the central nervous system and by the symptoms of lack of coordination of the hind legs and, to a lesser extent, the forelegs, unsteadiness while walking, flaccid or spastic paralysis, and total incapacity to walk and death (Suttle, 2010 and Brewer, 1983).

Two types of enzootic ataxia have been described, based on the lesion site and the chronology of the condition. The congenital form is marked by destruction of the cerebral white matter and affects neonates in their first days of life. The late form is characterized by lesions of the brain stem and spinal cord motor tracts, with occurrences after the third week of life (Suttle, 2010).

Copper (Cu) is an essential microelement that plays a variety of biochemical and metabolic roles in animals (Grace, 1983). Cu deficiency causes various syndromes in domestic ruminants (MacPherson, 1989) that have also been described in deer (Audige et al. 1995; Wilson and Grace 2001). Cu deficiency may be primary, associated with low Cu intake, or secondary, when Cu absorption or metabolism is adversely affected due to high levels of molybdenum (Mo), iron (Fe), sulphur (S) or zinc (Zn) in the diet (Grace, 1983). According to Suttle (1991) and Smith et al. (2006) a dietary excess of Mo is one of the most common reasons for secondary Cu deficiency.

The objective of the present study was to report on the clinical and epidemiological characteristics of an outbreak of the late form of enzootic ataxia among sheep in south Sinai region of Egypt.

## 2. MATERIALS AND METHODS

### 2.1. Animals

Twenty two sheep kids aged between 1 and 2 months were considered in this study. All animals were in the weaning period and they were obtained from 3 herds from north Sinai. Eleven animals constituted the Control Group and

only healthy kids were included. Another eleven animals constituted the Problem Group and only kids with initial symptoms of copper deficiency were included.

**2.2. Samples**

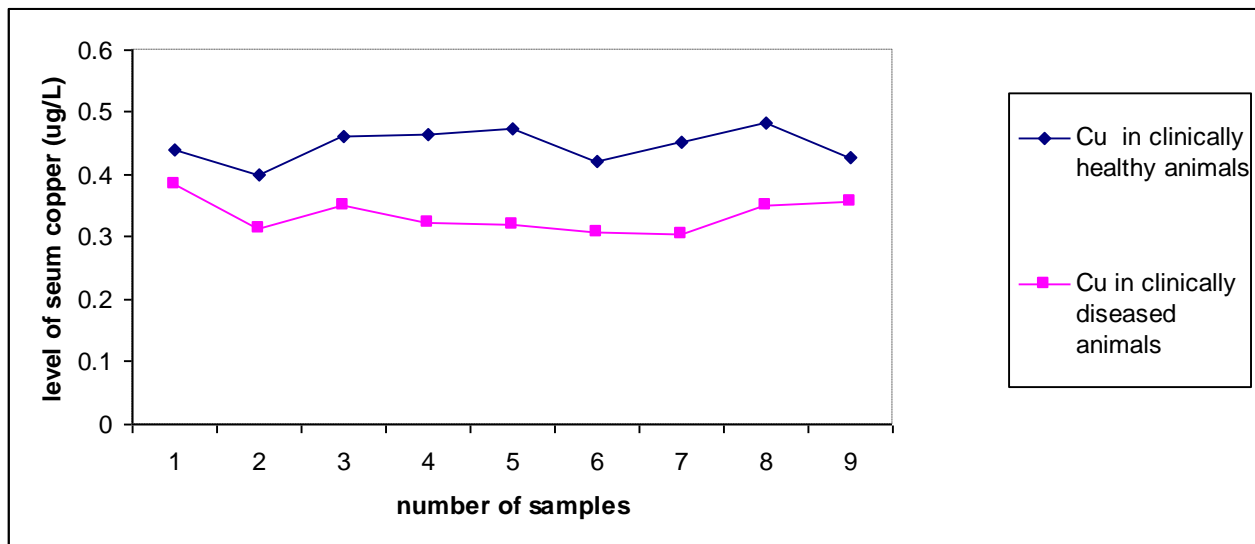
Five ml of blood samples were collected from the jugular vein of each animal, each blood sample divided into two portions. The 1<sup>st</sup> portion (2ml) was anticoagulated by (EDTA) and was used for hemogram investigation (Feldman et al., 2000). The 2<sup>nd</sup> portion (3ml) were allowed to clot, and then centrifuged at 3000 rpm for 10 minutes for serum separation. Copper content in the plasma was determined by atomic absorption spectroscopy using Hitachi Z-500 equipment. The value reported for copper content in the plasma was the mean value obtained from 3 measurements.

**2.3. Statistical analyses**

Statistical differences were calculated according to the Student t-test with significance level at P<0.05. All results were analyzed using the procedure of (SAS, 2004).

**3. Results and Discussion**

At the clinical attendance on the farm, the owner reported that after the first month of life, six sheep in the herd had started to present a condition of difficulty in walking, falls, and tremors. After the symptoms started, the condition worsened, with apathy, weight loss, and death. The clinical manifestation occurred only in sheep aged from 1 to 2 months. In the physical examination on the clinically affected animals, the following symptoms were observed: difficulty in rising to a standing position; lack of coordination; frequent falls; ataxia in the hind legs and, with less severity, in the forelegs; weight loss and progressive apathy. The animals also presented difficulty in suckling, rough cote, little pigmentation, and limited body development. Among the six animals with clinical symptoms, three of them died between 10 and 20 days after the initial diagnosis. The animal that survived continued to present sequel such as difficulty in walking and poor body development.



Erythrogame of animal all over the experiment period. ( mean + SE )		
Kids affected by enzootic ataxia	Healthy kids	
5.66±0.52	14.18±1.20	RBCs(x10/ml)
7.25±0.15	10.77±0.35	Hb ( g/dl )
26.9±1.60	31.69±1.40	pcv (%)
13.98±0.62	7.66±0.32	TLCx10/Ul)
10.78±0.20	3.21±1.63	Neutrophil(10/ul)
4.21±0.62	6.76±0.54	lymphocyte(x10ul)
0.19±0.08	0.17±0.01	Monocyte (x10/ul)
0.26±0.08	0.22±0.11	Esinophile (x10/ul)
0.07±0.0	0.01 ±0.0	Basophil (x10/ul)

**S\* = significant at  $p < 0.05$ .**

**N S\* = not significant at  $p < 0.05$ .**

Copper contents in plasma from clinically affected kids are shown in Figure 1, and Table I shows blood values from the kids with copper deficiency (Problem Group) and from the clinically healthy Group. The animals from the Problem Group showed a low number of red blood cells (RBC). Variations in RBC size and shape. Normal values accepted for hemoglobin are comprised between 8–12 g.dL<sup>-1</sup>, and the Control Group showed  $10.77 \pm 0.35$  g.dL<sup>-1</sup>. We found hemoglobin values from ole kids with copper deficiency of  $7.25 \pm 0.15$  g.dL<sup>-1</sup>, these values were close to the lower range of the normal values. Kids from the clinically affected kids Group presented an important increase in neutrophils and leukocytes; precursor cells of neutrophils were also observed. These increases could be related to any infectious disease. Monocyte counts were also higher than the normal values obtained for the Control Group. Plasma copper is recognized to be a more sensitive measure of copper status in animals than whole blood copper (Claypool et al 1975).

The clinical condition presented was similar to what has been described in the literature for late enzootic ataxia in lambs (Radostits, et al., 2002 and Dos Santos et al., 2006). Mineral supplementation containing 0.01% of Cu is required in order to meet these animals' needs (Riet-Correa, 2004).

High concentrations of Zn and Mo can interfere with copper metabolism, however hepatic zinc values were below normal for the species (110–220 ppm), probably due to inefficient mineral supplementation given to the animals (Tokarnia, 1999; Minervino, 2009 and Suttle, 2010). Further studies with complete mineral profile in all seasons are required to better understanding of the mineral antagonism present in the region. In cases of zoonotic ataxia, it is not uncommon for anemia to be present but we did not find any anemia among the animals of the present study. Biochemical and hematological evaluation were not useful to diagnose copper deficiency (Radostits et al., 2002).

The animals in the herd of the present study all had low plasma Cu levels, and not just the ones that were clinically affected, which suggests that this herd presented a severe Cu deficiency. This corroborates the findings from the study by Tokarnia et al., (1999).

Plasma copper is recognized to be a more sensitive measure of copper status in animals than whole blood copper but much less than other parameters (ceruloplasmin activity) (Claypool et al., 1974). Copper concentrations in plasma obtained from kids included in the Problem Group were lower than the normal values accepted in goats (Faye and Grillet, 1984) or in sheep (Blood et al., 1987 and Tschopp et al., 1998). Generally data from sheep (Fraser and Stamp, 1989) are used as the standard because the copper content from the healthy caprine herd was not fully standardized. Church (1993) determined that for lambs. In the present work, we obtained blood copper levels in sheep kids at about 0.3 mg. mL<sup>-1</sup>, together with a clinical expression of enzootic ataxia. Apparently sheep kids are more sensitive to copper deficiency than the goats that were considered in the study carried out by Faye and Grillet (1984).

The primary copper deficiency is due to an insufficient supply on ranges, while the secondary copper deficiency is due to a marked excess of molybdenum in grasslands. Galbraith et al. (1997). The animals included in the Problem Group presented weakness and paleness in their mucous membranes, which were related to low values of red cells. The anemia observed in clinically affected from the Problem Group could be a ferropenic-type anemia, which is hypochromic and macrocytic (Church and Pond, 1998 and Merck, 1993). The bioavailable copper must be in adequate levels for the formation of red cells. On the contrary, ceruloplasmin concentration is directly related to copper absorption and usefulness; therefore a decrease of ceruloplasmin induces anemia [Lee, Cartwright and Wintrobe, 1968]. The kids seriously affected with copper deficiency, have difficulty in surviving since no treatment gives satisfactory results. When the deficiency is incipient, the kids can receive products containing bioavailable copper as a treatment. The copper requirement of a sheep fetus almost increases 6 times between the first third and the second third of gestation and this last level is duplicated in the final third (Moss et al 1974). Williams et al. (1978) reported that in the non-liver compartment of fetal lambs at the end of pregnancy a little more than 2 mg Cu is deposited/kg live-weight gain.

Sheep are very sensitive to copper toxicity, which therefore explains the small concentration of their salt blocks (Blood et al., 1987). Goats are very sensitive to copper deficiency and resistant to the toxicity of this metal; for these reason goats should receive mineralized salt for bovines (Merck 1993, and Soli and Nafstad, 1978).

Our results represent the information on copper deficiency in lambs in south Sinai. However, a prevention program on copper deficiency may be practiced in the governorate.

## Conclusion

The clinical symptoms, observed among lambs, were compatible with what has been described in the literature for the late form of enzootic ataxia.

The finding of organic Cu levels lower than the normal range for sheep, confirmed the diagnosis of enzootic ataxia.

In rearing systems in the semiarid zone of south Sinai Egypt, additional copper supplementation may be necessary for metaphylactic treatment of enzootic ataxia, especially for extensive raised sheep where the soil and plant mineral concentration are unknown.

## References

- Aregheore, E.M.; Hunter, D.; Perera, D. and Mautoatasi, M.T. (2007): The soil-plant-animal phenomena: Serum mineral status of Fuji fantastic sheep grazing Batiki grass (*Ischaemum aristatum* Var. *indicum*) and Pangola grass (*Digitaria decumbens*) in Samoa. *J. Anim. Vet. Adv.*, 6: 349-357.
- Audige LJM; Wilson, PR; Morris, RS; and Davidson, GW (1995): Osteochondrosis, skeletal abnormalities and enzootic ataxia associated with copper deficiency in a farmed red deer (*Cervus elaphus*) herd. *New Zealand Veterinary Journal* 43, 70–76.
- Ben Salem, H. and Smith, T. (2008): Feeding strategies to increase small ruminant production in dry environments. *Small Ruminant Res.*, 77: 174-194.
- Bennetts, H. and Chapman, F. (1937): Copper deficiency in sheep in western Australia: a preliminary account of the aetiology of enzootic ataxia of lambs and anaemia of the ewe. *Australian Veterinary Journal* 13: 138-149.
- Blezinger, Stephen B. (2004): High Levels of Sulfur in a Cow's Diet Can Affect Copper Absorption. *Cattle Today*, Inc., 2004.
- Blood, D.C.; Henderson, J.A.; and Radostits, O.M. (1987): *Medicina Veterinaria*, 5a edición, Editorial Interamericana, México, D.F., pp. 924–933.
- Brewer, B.D. (1983): Neurologic disease of sheep and goats. *Veterinary Clinics of North America: Large Animal Practice*, 5(3):677–700.
- Cardoso, EC; McDowell LR; Vale WG, et al. (1997): Cooper and molybdenum status of cattle and buffaloes in Marajo Island, Brazil. *International Journal Animal Science*. 1997, 12:57–60.
- Chalmers, G. (1974): Swayback (Enzootic ataxia) in Alberta lambs. *Can. J. Comp Path.*, 38 :111-117.
- Church, C.D. (1993): *El rumiante: fisiología digestiva y nutrición*, Editorial Acribia S.A., Zaragoza, España, pp. 397–408.
- Church, C.D. and Pond, W.G. (1998): *Fundamentos de nutrición y alimentación de animales*, Editorial Limusa S.A. de C.V. Grupo Noriega Editores, México, D.F., pp. 189–192.
- Claypool, D.W.; Adams, F.W.; Pendell, H.W.; Hartmann, N.A., and Bone, J.F. (1975): Relationship between the level of copper in the blood plasma and liver of cattle, *J. Anim. Sci.* 41: 911–914.
- Corah, L. (1996): Trace mineral requirements of grazing cattle. *Anim. Feed Sci. Technol.*, 59: 61-70.
- Cordy, D. (1971): Enzootic ataxia in California lambs. *JAVMA*, 158 (11):1940- 1942.
- Dos Santos, N. V. M.; JSarkis, E. D. S.; J. L. Guerra et al. (2006): Epidemiological, clinical, etiological and histopathological evaluation of delayed enzootic ataxia outbreaks in kids and lambs,” *Ciencia Rural*, 36 (4): 1207–1213.
- Faye, B. and Grillet, C. (1984): La carence en cuivre chez les ruminants domestiques de la région d’Awash (Ethiopie), *Rev. Elev. Méd. Vét. Pays Trop.*, 37: 42–60.
- Feldman, B.F.; Zinkl, J.G.; Jain, N.C. and Schalm, S. (2000): *Veterinary hematology*. 5. ed. Lippincott Williams & Wilkins, pp: 787.
- Fraser A.; Stamp, J.T., and Ganado, ovino (1989): *Producción y enfermedades*, Ediciones Mundi-Prensa, Madrid, España, pp: 275–276.
- Galbraith, H.; Chigwada, W.; Scaife, J.R., and Humphries, W.R. (1997): The effect of dietary molybdenum supplementation on tissue copper concentrations, mohair fibre and carcass characteristics of growing Angora goats, *Animal Feed Sci. Technol.* 67: 83–90.
- Garrick, MD; Dolan, KG; Horbinski, C. et al. (2003): DMT1: a mammalian transporter for multiple metals. *BioMetals*, 16 (1): 41–54.
- Geisel, O.; Betzl, E., Dahme, E.; Schmahl, W.; and Hermanns, W. (1997): Enzootische spinale Ataxie bei Dam und Rotwild in Gehegen in Oberbayern. *Tierarztl Prax*, 25: 598-604.
- Gonul, R.; Kayar, A.; Bilal, T.; Erman, O.R.M.; Parkan, D.V.M.; Dodurka, H.T.; Gulyasar, T. and Barutcu, B. (2009): Comparison of mineral levels in bone and blood serum of cattle in Northwestern Turkey. *J. Anim. Vet. Adv.*, 8: 1263- 267.

- Grace, ND (1983): Copper. In: Grace ND (ed.): The Mineral Requirements of Grazing Ruminants. New Zealand Society of Animal Production, Occasional Publication 9: 56–66.
- Grace, N.; Rounce, J.; Knowles, S.; Lee, J. (1999): Effect of increasing elemental sulphur and copper intakes on the copper status of grazing sheep. *Proceedings of the New Zealand Grassland Association*, 60: 271- 274.
- Hidiroglou, M. and Knipfel, J. (1981): Maternal fetal relationships of copper, manganese and sulphur in ruminants .*A Review Journal of Dairy Science*, 64: 1637-1647.
- Jones, HB; Gooneratne, SR; and Howell, J. J. (1984): X-ray microanalysis of liver and kidney in copper loaded sheep with and without thiomolybdate administration. *Research in Veterinary Science*, 37(3):273–282.
- Jubb, K. and Kennedy, P. (1999): *Pathology of domestic animals*, 3:127-130.
- Kincaid, R.I. (1999): Assessment of trace mineral status of ruminants: A review. *Proceedings of the American Society of Animal Science*, pp: 1-10.
- Lee, G.R.; Cartwright, G.E.and Wintrobe, M.M. (1968): Heme biosynthesis in copper deficient swine, *Proc. Soc. Exp. Biol. Med.* 127: 977–981.
- MacPherson, A (1989): Trace element deficiency in ruminants. *Outlook on Agriculture* 18: 124–132.
- Marques, AP; Riet-Correa, F; Soares, MP; Ortolani, EL and Giuliadori, MJ. (2003): Sudden deaths in cattle associated with copper deficiency. *Pesquisa Veterinaria Brasileira.*, 23 (1): 21–32.
- McDowell, L. R. (1999): Minerals for Ruminants under Pasture in Tropical Regions, *Empathizing Brazil*, UNESP, Sˆao Paulo, Brazil.
- McDowell, L.R.; Conrad, J.H. and Hembry, F.G. (1993): Minerals for grazing Ruminants in Tropical Regions. *Animal science department, University of Florida*, pp: 2-70.
- Merck, (1993): *El Manual de Veterinaria Merck & Co., Inc., 4a edici3n*, Oci3ano / Centrum, Barcelona, Espa˜na, pp. 1285–1288, 1892–1894.
- Minervino, AHH; Barreto Junior, RA; Ferreira, RNF, et al. (2009): Clinical observations of cattle and buffalos with experimentally induced chronic copper poisoning. *Research in Veterinary Science*, 87(3):473–478.
- Moss, B.R.; Madsen, F.; Hansard, S.L.and Gamble, C.T.(1974): Maternal-Fetal Utilization of copper by sheep, *J. Anim. Sci.*, 38: 475–479.
- Nederbragt, H.and Wensvoort, P. (1984): Pathobiology of copper toxicity. *Vet. Q.* 6: 179-185.
- Ortolani, EL; Machado and Sucupira, CH (2003): Assessment of some clinical and laboratory variables for early diagnosis of cumulative copper poisoning in sheep. *Veterinary and Human Toxicology*, 45(6):289–293.
- Radostits, OM and Gay, CC. (2002): Hinchcliff KW, Blood DC. *Veterinary Medicine: A Textbook of the Diseases of Cattle, Horses, Sheep, Pigs and Goat*. 9th edition. Rio de Janeiro, Brazil: Guanabara Koogan.
- Riet-Correa, F. (2004): Mineral supplementation in small ruminants in the semiarid region. *Veterinary Science in the Tropics*, 7:112–130.
- Saba, L., Bombik, T., Bombik, A., Nowakowicz-Debek B. “Mineral deficiency in dairy cows”. *Medycyna Weterynaryjna* 56, 125-128, 2000.
- SAS (2004): *Statistical Analysis Systems. Version 9.2*. SAS institute Cary, NC.
- Schoenian, S. (2009): *Copper Toxicity in Sheep*. Small Ruminant Info Sheet. University of Maryland Extension. This article talks about copper toxicity in sheep.
- Smith, LC; Hawke, MF; Morton, JD and Catto, WD (2006): The effectiveness of copper fertiliser in maintaining the copper status of deer at moderate to high pasture molybdenum contents. *New Zealand Journal of Agricultural Research*, 49: 45–54.
- Soli, N.E.and Nafstad, I.(1978): Effects of daily oral administration of copper to goats, *Acta Vet. Scand.* 19: 561–568.
- Suttle, N. F.(2010): *Mineral Nutrition of Livestock*, Cabi Publishing, Wallingford, UK, 4th edition.
- Suttle, NF (1991): The interactions between copper, molybdenum, and sulfur in ruminant nutrition. *Annual Review of Nutrition* 11: 121–140.
- Szefer, P. and Nriagu, J.O. (2007): *Mineral components in Foods*. CRC press, Taylo and Francis Group, USA, pp: 123.
- Tokarnia, C. H.; ˆobereiner, J. D; Moraes, S. S. and Peixoto, P. V. (1999): Mineral deficiencies and imbalances in cattle and sheep— a review of Brazilian studies made between 1987 and 1998. *Pesquisa Veterinaria Brasileira*, 19 (2): 47–62.
- Tschopp, J.C.; Althaus, R.L.; Gervasio, S. and Malinskas, G. (1998): Aplicaci3n de la bioquímica sanguínea como método complementario para el análisis del estado nutricional de un rodeo de ovinos con signos de hipocupremia, *Therios*, 144: 332–334.
- Underwood, E.J. (1977): *Trace elements in humans and animal nutrition*, 3rd and 4th Edn., Academic Press, New York.

- Unny, N.; Pandey, N. and Dwivedi, S. (2002): Biochemical studies on experimental secondary copper deficiency in goats. *Indian Journal of Animal Sciences*, 72:52- 54.
- Widdowson, E.; Dauncey, J. and Shaw, J. (1974): Trace elements in foetal and early postnatal development. *Proceedings of the Nutrition Society*, 33: 275-284.
- Williams, R.B.; McDonald, I. and Bremner, I. (1978): The accretion of copper and of zinc by the fetuses of prolific ewes, *Br. J. Nutr.*, 40: 377–386.
- Wilson, P and Grace, ND (2001): A review of tissue reference values used to assess the trace element status of farmed red deer (*Cervus elaphus*). *New Zealand Veterinary Journal*, 49:126–132.