



ISSN NO. 2320-5407

Journal Homepage: - www.journalijar.com
**INTERNATIONAL JOURNAL OF
 ADVANCED RESEARCH (IJAR)**

Article DOI: 10.21474/IJAR01/1812
 DOI URL: <http://dx.doi.org/10.21474/IJAR01/1812>



CASE REPORT

PRIMARY CUTANEOUS ASPERGILLOSIS- TINEA PEDIS CAUSED BY *ASPERGILLUS NIGER* IN AN IMMUNOCOMPETENT ADULT INDIVIDUAL RESIDING IN SILK CITY OF KANCHEEPURAM DISTRICT.

Prasanna S*¹, Karthika Jayakumar² and Jayashree V¹.

1. Assistant Professor, Department of Microbiology, Shri Sathya Sai Medical College and Research Institute, Kancheepuram, Tamil Nadu, India.
2. Professor, Department of Microbiology, Shri Sathya Sai Medical College and Research Institute, Kancheepuram, Tamil Nadu, India.

Manuscript Info

Manuscript History

Received: 12 August 2016
 Final Accepted: 16 September 2016
 Published: October 2016

Key words:-

Cutaneous aspergillosis, Tinea pedis, *Aspergillus niger*, immunocompetent host.

Abstract

Primary cutaneous aspergillosis is a rare disease usually caused by *Aspergillus fumigatus*, *Aspergillus flavus*, *Aspergillus terreus* and rarely *Aspergillus niger*. It is usually seen in immunocompromised hosts, even though some case reports are also seen in immunocompetent hosts. We present a case of Primary cutaneous aspergillosis- Tinea pedis caused by *Aspergillus niger* in an immunocompetent adult individual residing in silk city of Kancheepuram district. The characteristic features of *A.niger* with radiating phialides and conidiospores with black pigmentation were found in skin lesions on fungus isolated in culture. The patient showed excellent response to antifungal therapy.

Copy Right, IJAR, 2016,. All rights reserved.

Introduction:-

Cutaneous aspergillosis is a rare form of a locally invasive disease among immunocompetent host and in immunocompromised host the most common causes of aspergillosis are *Aspergillus fumigatus*, *Aspergillus flavus*, and *Aspergillus terreus* [1]. The patients with severe debilitating illnesses and immunocompromised states with neutropenia are at risk for cutaneous aspergillosis and also those who are receiving long-term corticosteroids, antibiotics or cytotoxic drugs. It also occurs in patients suffering from malignancies, tuberculosis, silicosis and diabetes. The skin injuries like trauma, occlusive dressing, burns or surgery and intravenous cannulation can lead to primary cutaneous aspergillosis. The widespread hematogenous seedling leads to the secondary cutaneous lesions [2,3]. Till now, only a few cases of Tinea pedis caused by non-dermatophytic etiology have been reported. The objective of this case report was to present "Primary cutaneous aspergillosis- Tinea pedis caused by *Aspergillus niger* in an immunocompetent adult individual residing in silk city of Kancheepuram district".

Case Description:-

A 45 year old male presented to dermatology OPD with hyper pigmented plaque like scaly lesion over the right sole for about three weeks. He was a farmer and does cultivation of vegetables. There was no history of contact with infected persons and pets. There was no evidence of skin lesions anywhere else on the body. The patient was immunocompetent, non-diabetic and not on immunosuppressive drugs. On clinical examination, he was found to have hyper pigmented; scaly, sharply marginated 3-4 lesions with slightly raised borders over the right sole (Fig. 1).

Corresponding Author:- Prasanna S.

Address:- Assistant Professor, Department of Microbiology, Shri Sathya Sai Medical College and Research Institute, Kancheepuram, Tamil Nadu, India.

The Gram stain showed the absence of bacteria and no acid fast bacilli by Ziehl Neelsen stain. The microscopic examination of skin scraping after treatment with 10% KOH revealed the presence of septate hyaline hyphae. The material was cultured in Sabouraud dextrose agar (SDA) slant tubes with and without cycloheximide. SDA without cycloheximide grew smooth, white colonies initially and matures to velvety, jet black center with characteristic white apron or brim and no reverse pigment after about 7 days (Fig. 2). Lactophenol cotton blue (LCB) mount showed hyphae with black colour, erect conidiophores terminated with radiating phialides covering entire vesicles (Fig. 3). The fungus was identified as *Aspergillus niger* with the help of cultural characteristics and the typical microscopic features of hyphae with black colour, erect conidiophores terminated with radiating phialides covering entire vesicles on LCB mounts. The same fungus was isolated again from repeat sample of skin scrapings. The patient was put on oral fluconazole 150 mg initially with topical 1% terbinafine cream twice daily and tablet cetirizine 10 mg one tablet at night for 10 days. He was switched over to oral itraconazole and continued with terbinafine cream and cetirizine. He was assessed for therapeutic success after 4 weeks and had shown significant improvement. Itraconazole and topical terbinafine was discontinued after 6 weeks and the lesions showed complete resolution in the next follow up.

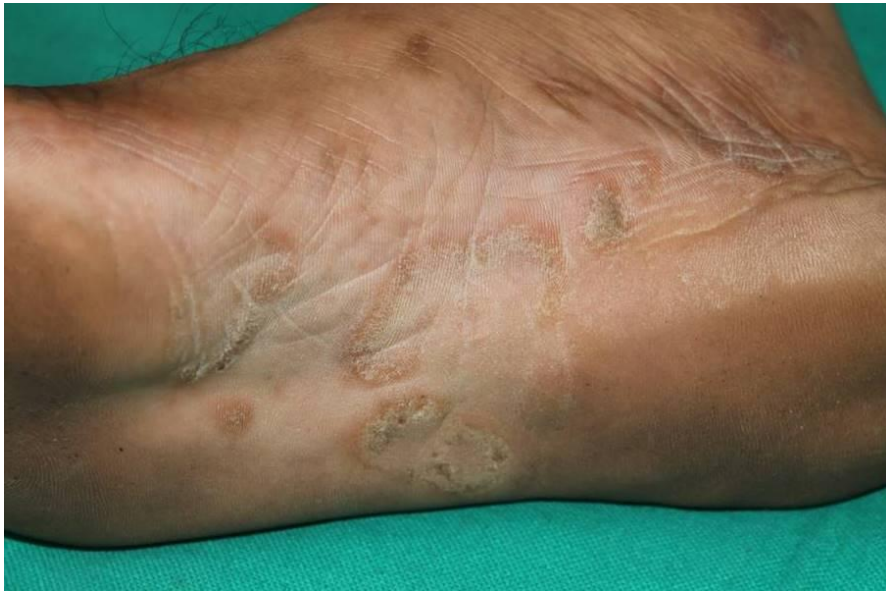

Fig 1:- Tinea pedis over right sole showing hyper pigmented; scaly, sharply margined 3-4 lesions with slightly raised borders.




Fig 2:- A- Sabouraud Dextrose agar showing smooth, white colonies initially and matures to velvety, jet black center with characteristic white apron or brim (left); B- Sabouraud Dextrose agar showing side view with no reverse pigment (right).

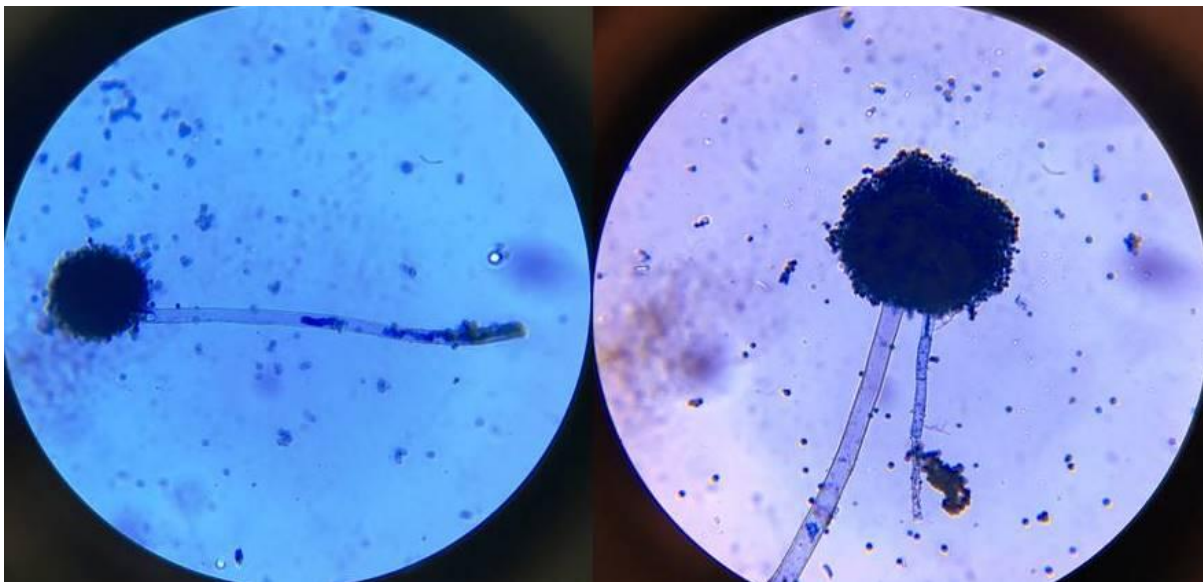


Fig 3:- Lactophenol cotton blue (LCB) mount hyphae with black colour, erect conidiophores terminated with radiating phialides covering entire vesicles by 40X magnification.

Discussion:-

Aspergillus species affects the lungs, central nervous system, naso-orbital area, skin and disseminates to the systemic circulation to cause invasive aspergillosis. It is the most common ubiquitous fungi seen in soil, water and decaying vegetation. Cutaneous aspergillosis is usually occurs associated with immunocompromised patients, but

also reported cases in immunocompetent individuals. The most common causative agents of cutaneous aspergillosis are *A.flavus*, *A.fumigatus*, and rarely by *A.niger*. Clinically, the lesion varies from superficial scaly macules; papules to hyper pigmented or hypo pigmented plaques or nodules, which may progress into necrotic ulcers then to black eschar [4]. Our patient was not immunocompromised and the cutaneous aspergillosis is also common in immunocompetent patients [5,6]. There was a study carried out by Burik *et al*, in which 6% of lesions caused by *A.niger* in patients not infected with HIV [7]. Early diagnosis, reporting and treatment of such fungi are necessary to prevent deep or systemic spread.

The first line of treatment for superficial or localized lesions is itraconazole [7]. The superficial cutaneous aspergillosis can be treated with effective oral antifungal with topical antifungals and a combination of surgical debridement and multi-drug antifungal chemotherapy for deep or ulcerative lesions [8]. A case of cutaneous aspergillosis had shown complete clearance of the lesion with oral itraconazole treatment was reported by Ajith *et al* [9]. It has to be changed to intravenous amphotericin B if the lesion worsened or if there was other evidence of clinical failure. Tinea pedis caused by *A.niger* was not deeply extensive in our patient and was managed with the itraconazole and topical 1% terbinafine cream. There was no evidence of drug resistance because of good clinical response with the treatment.

Conclusion:-

We report "Primary cutaneous aspergillosis- Tinea pedis caused by *Aspergillus niger* in an immunocompetent adult individual residing in silk city of Kancheepuram district".

The treatment of *Aspergillus* infection is generally ineffective with antibiotics as the fungus does not respond to antibiotics traditionally intended for skin infection. So proper clinical evaluation, categorization into superficial or deep infection cutaneous aspergillosis is very important, diagnosis after culture and microscopy leads to a positive clinical outcome

References:-

1. John PU, Shadomy HJ (1987). Deep fungal infections. In: Fitzpatrick TB, Eisen AZ, Wolff K, *et al*. editors. Dermatology in general medicine. 3rd edition. New York: McGraw - Hill; p. 2266-8.
2. Chakrabarti A, Gupta V, Biswas G, Kumar B, Sakhuja VK (1998). Primary cutaneous aspergillosis: Our experience in 10 years. J Infect; 37:24-7.
3. Zhang QQ, Li L, Zhu M, Zhang CY, Wang JJ (2005). Primary cutaneous aspergillosis due to *Aspergillus flavus*: A case report. Chin Med J Engl. 118:255-7.
4. Stevans DA, Kan VL, Judson MA, Morrison VA, Dummer S, Denning DW, *et al* (2000). Practice guidelines for diseases caused by *Aspergillus*. Clin Infect Dis; 30:696-709.
5. Romano C, Miracco C (2003). Primary cutaneous aspergillosis in an immunocompetent patient. Mycoses; 46:56-9.
6. Domergue V, Orlandini V, Begueret H, Couprie B, Huerre M, *et al* (2008). Cutaneous, pulmonary and bone aspergillosis in a patient presumed immunocompetent presenting subacute cutaneous lupus erythematosus. Ann Dermatol Venereol; 135:217-21.
7. van Burik JA, Colven R, Spach DH. Cutaneous aspergillus (1998). J Clin Microbiol; 36:3115-21.
8. Heo CY, Eun SC, Baek RM, Minn KW (2008). Free flap coverage of soft tissue defect in cutaneous aspergillosis: A case report. J Korean Med Sci; 23:920-3.
9. Ajith C, Dogra S, Radotra BD, Chakrabarti A (2006). Primary cutaneous aspergillosis in an immunocompetent individual. J Eur Acad Dermatol Venerol; 20:738-9.