



ISSN NO. 2320-5407

Journal Homepage: -www.journalijar.com

INTERNATIONAL JOURNAL OF ADVANCED RESEARCH (IJAR)

Article DOI:10.21474/IJAR01/10288
DOI URL: <http://dx.doi.org/10.21474/IJAR01/10288>



INTERNATIONAL JOURNAL OF
ADVANCED RESEARCH (IJAR)
ISSN 2320-5407
Journal Homepage: <http://www.journalijar.com>
Journal DOI:10.21474/IJAR01

RESEARCH ARTICLE

PAROTITIS IN LIPOID PROTEINOSIS

Chiguer Meriem, Ouadi Zahra, Amal Said and Hocar Ouafa

Departments of Dermatology, Cadi Ayyad University, CHU Mohammed VI BP2360 Principal, Avenue Ibn Sina, Marrakech, Morocco.

Manuscript Info

Manuscript History

Received: 23 November 2019

Final Accepted: 25 December 2019

Published: January 2020

Key words:-

Urbach-Wiethe Disease, Lipoid Proteinosis, Parotitis

Abstract

Lipoid proteinosis is a rare autosomal recessive multisystem disorder caused by mutations in the extracellular matrix protein 1 gene. It is characterized by infiltration of amorphous hyaline in the dermis and submucosal connective tissue. We report the case of 36-year-old woman with history of hoarseness since infancy and multiple episodes of right parotitis. Dermatological examination found bead-like papules on the margins of the eyelids, thickened skin lesions on the elbows and knees, enlargement of the tongue with dental impressions and lingual frenulum infiltration. Skin biopsy showed histopathological findings of lipoid proteinosis. The patient was treated by acitretin for 6 months with no improvement of the skin lesions. Three months later, patient presented a left parotitis with a cutaneous fistula through which abscess was discharged. The objective of the present report is to describe this rare entity and report that lipoid proteinosis may be associated with recurrent parotitis caused by infiltration and stenosis of Stensen's duct.

Copy Right, IJAR, 2020., All rights reserved.

Introduction:-

Lipoid proteinosis (LP) is a rare genodermatosis characterized by infiltration of amorphous hyaline in the dermis and submucosal connective tissue (Bhattacharjee et al., 2018). It was first described by the dermatologist Urbach and the otolaryngologist Wiethe in 1929 (McGrath, 2015).

Case report:-

A 36-year-old female born of a consanguineous marriage with history of hoarseness since infancy and multiple episodes of right parotitis occurring within a six years period.

Cutaneous examination revealed multiple beaded papules lining the free edge of eyelids (Fig 1.a), verrucous papules over the dorsum of hands, hyperpigmented scars over elbows and knees (Fig 1.b) and a mild frontal alopecia (Fig 1.c).

Lips were infiltrated and commissures presented small waxy papules. Examination of the oral cavity showed some white papules on the inner surfaces of the lips with a hypertrophy of Stensen's duct orifice (Fig 2.a). The tongue was hypertrophied and showed dental impressions (Fig 2.b). The lingual frenulum was thickened and seemed to impair tongue mobility (Fig 2.c). The clinical findings along with the histopathological examination of skin supported the diagnosis of LP. No neuropsychiatric abnormalities were reported. MRI of the head has not revealed calcifications. Laryngoscopic examination and ophthalmologic evaluation were within normal limits.

Corresponding Author:- Chiguer Meriem

Address:- CHU Mohammed VI BP2360 Principal, Avenue Ibn Sina, Marrakesh.

Acitretin was started at 0.5 mg/kg/day. After 6 months of treatment, no improvement of the skin lesions was noted, and the treatment was discontinued.

Three months later, patient presented an increasingly painful swelling and reddening in the area of the left parotid gland. A cutaneous fistula was developed through which abscess was being discharged (fig 3.a).

Ultrasound of parotid glands revealed a swelling of the left gland with duct dilatation and heterogeneous parenchyma with a hypochoic zone in deep lobe. No image of calculus was observed.

Antibiotic therapy was given for 10 days, Subsiding the swelling and pus discharge. It persists a scar tissue on the left cheek on anterosuperior region of the angle of mandible. A small pinpoint opening was seen just above the scar from which watery fluid discharged spontaneously.

A week later healing was complete. The skin orifice has disappeared leaving behind trivial scarring. There was no residual swelling, no pain and no recurrence of the fistula. The patient was referred to Ear Nose and Throat department (fig 3.b).

Discussion:-

LP is an autosomal recessive disorder caused by mutations in the extracellular matrix protein 1 gene (ECM1) located on chromosome 1q21. ECM1 is expressed in several tissue. It is involved in extracellular matrix formation and its mutation is responsible for deposition of non-collagenous proteins and glycoproteins in the skin and mucosa (Pinna et al., 2000; Ghazawi et al., 2019).

The most consistent clinical feature is hoarseness of voice due to laryngeal infiltration, often from birth or infancy (Larkin et al., 2018). The classical cutaneous symptom is moniliform blepharosis; it is a pathognomonic sign characterized by presence of multiple papules that line up on the eyelid margins (Belliveau et al., 2015).

Infiltration and thickening of oral mucosa may lead to upper submandibular gland inflammation as well as recurrent episodes of parotitis (Al-Ekrish and Al-Sadhan, 2012), caused by infiltration and stenosis of Stensen's duct, and led to xerostomia (Epple et al., 2018). A dry mouth and repeated trauma owing to macroglossia may lead to the development of lingual ulcer (Sabater-Abad et al., 2019).

There is no curative therapy available for LP. Various treatment alternatives including acitretin, D-penicillamine, laser treatment have been tried in literature with no uniformly success (Dertlioglu et al., 2014).

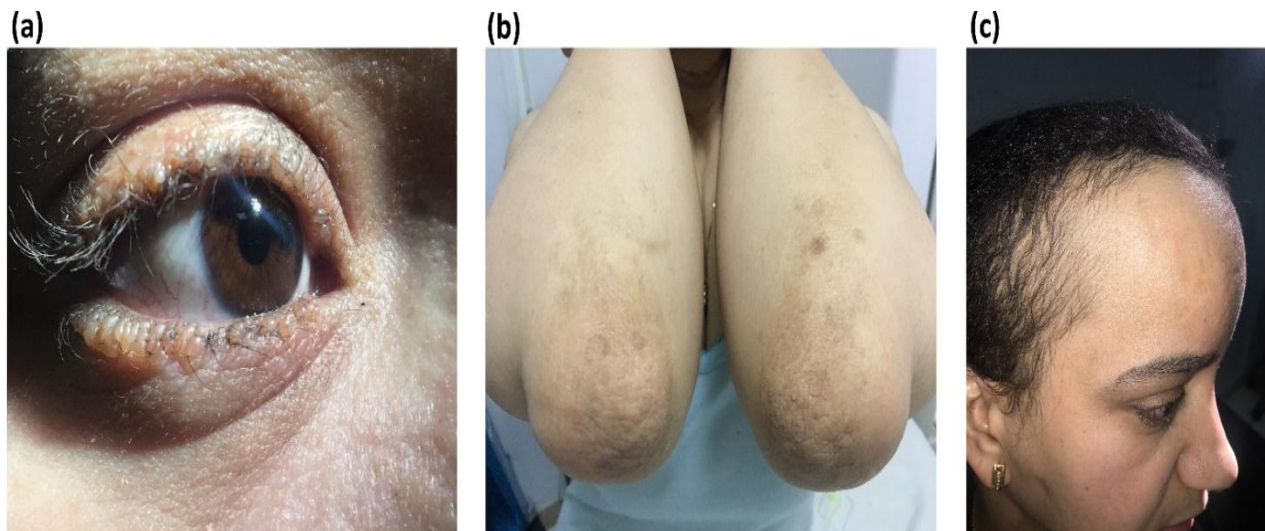


Figure 1:- (a) Moniliform blepharosis. (b) Elbow skin thickening with hyperpigmented scars. (c) Frontal alopecia.

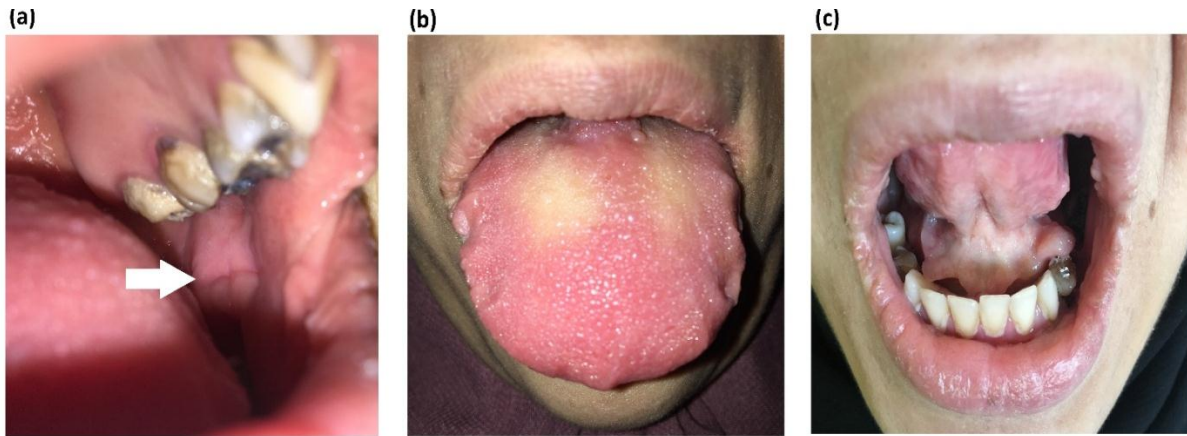


Figure 2:- (a) Hypertrophy of Stensen's duct orifice. (b) Enlargement of the tongue with dental impressions. (c) Lingual frenulum infiltration.

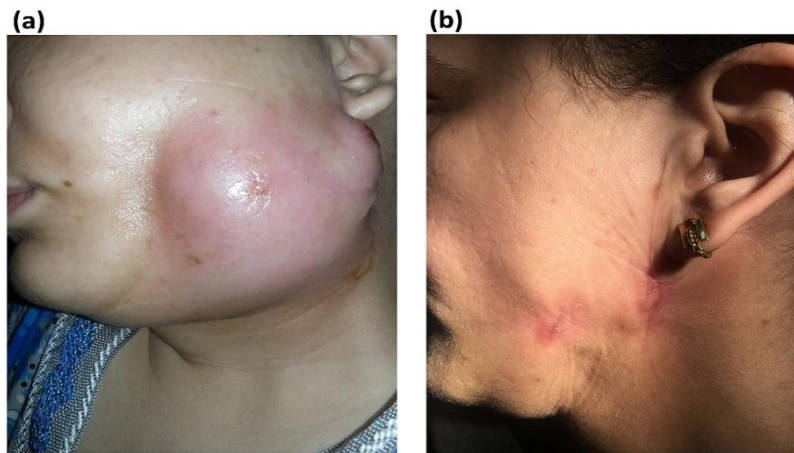


Figure 3:- (a) Left parotitis with swelling in the preauricular region. (b) Scarring after disappearance of the cutaneous fistula.

References:-

1. Al-Ekrish Aa, Al-Sadhan Re. Lipoid proteinosis: A case report with recurrent parotitis and intracranial calcifications. *King Saud University Journal of Dental Sciences* 2012;3(1):13-16.
2. Belliveau MJ, Alkhotani A, Ali A. Moniliform Blepharosis of Lipoid Proteinosis. *JAMA Ophthalmol.*2015;133(7):e150688.
3. Bhattacharjee R, Chatterjee D, Vinay K. Lipoid Proteinosis. *JAMA Dermatol.* 2018;154(12):1479–1480.
4. Dertlioglu S.B., Calik M., Cicek D. Demographic, clinical and radiologic signs and treatment responses of lipoid proteinosis patients: a 10-case series from Sanliurfa. *Int Dermatol.* 2014;53:516–523.
5. Epple A, Hoxha E, Schneiderbauer R et al. Hyalinosis cutis et mucosae: A clinical investigation with special regard to mucosal changes. *J Dtsch Dermatol Ges.* 2018 Feb;16(2):211-213.
6. Ghazawi FM, Proulx ES, Jafarian F. A novel nonsense mutation in exon 9 in the extracellular matrix protein 1 gene associated with lipoid proteinosis: A case report. *SAGE Open Med Case Rep.* 2019;7:2050313X19850359.
7. Larkin S, Blixt EK, Kumar N et al. Lipoid proteinosis: Unfamiliar skin findings delay diagnosis. *JAAD Case Rep.* 2018 Jun 28;4(6):609-611.
8. McGrath JA. Lipoid proteinosis. *Handb Clin Neurol* 2015;132:317-22.
9. Pinna R, Cocco F, Campus G et al. Genetic and developmental disorders of the oral mucosa: Epidemiology; molecular mechanisms; diagnostic criteria; management. *Periodontol* 2000. 2019;80(1):12-27.
10. Sabater-Abad J, Matellanes-Palacios M, Pont-Sanjuan V et al. Oral Ulcer-A Disabling Manifestation in a Patient with Lipoid Proteinosis. *JAMA Dermatol.* 2019 Jun 12.