



Journal Homepage: -www.journalijar.com
**INTERNATIONAL JOURNAL OF
 ADVANCED RESEARCH (IJAR)**

Article DOI:10.21474/IJAR01/5451
 DOI URL: <http://dx.doi.org/10.21474/IJAR01/5451>



RESEARCH ARTICLE

LOVE HATE SEX PAIN: LOATHSOME MARITICIDE- A CASE REPORT.

Gaurav Sharma¹, Jai Soni², Tarun Dagar³, Kunal Khanna⁴ and Deepshikha⁵.

1. Senior Resident, Department of Forensic Medicine, Pt. B. D. Sharma PGIMS, Rohtak.
2. Senior Resident, Department of Forensic Medicine, All India Institute of Medical Sciences, Raipur.
3. Assistant Professor, Department of Forensic Medicine, Adesh Medical College, Ambala.
4. Assistant Professor, Department of Forensic Medicine, Kalpana Chawla Medical College, Karnal.
5. Post Graduate Resident, Department of Pathology, Pt. B. D. Sharma PGIMS, Rohtak.

Manuscript Info

Manuscript History

Received: 17 July 2017
 Final Accepted: 19 August 2017
 Published: September 2017

Key words:-

Dismembered, infiltration, antemortem, post-mortem, sharp cut, putrefied, fracture, hyperaemia.

Abstract

Society stands on the basis of sound interpersonal relationships. Families stand on the basis of sound co-ordination among members. Sociologists world over have considered family as a bicycle, each wheel equal in all respects. Husband and wife are these two wheels. If any of these skids, this assembly is doomed to fail. Problem to one spouse, in normal relationships causes trouble to the other partner as well. But cases of familial discord, scuffle, beatings between husband and wife are not unheard of. In most of these cases, husband tends to be the culprit and woman, merely a traumatized victim. Murder of one's husband or wife is a rare occurrence worldwide. In stark contrast to Philemon and Baucis Deaths, where deep love between partners is reflected by demise of a partner after death of the other one; mariticide is killing of husband and uxoricide is killing of wife. In our country, most of these cases have inherent similarity of one spouse having extra-marital relationship. In this paper, we will describe an unusual case of mariticide, where a woman with her extramarital boyfriend killed her husband. She further dismembered the body in multiple pieces and buried these in her own courtyard, from where she was arrested sitting on a cot watching TV, literally over the remains of her partner in life and death. Through this paper, we will discuss the cases in detail and highlight the importance of meticulous autopsy. Some sociological aspects will be considered too.

Copy Right, IJAR, 2017.. All rights reserved.

Introduction:-

World over barring some places, male is considered to be the dominant among the two partners in marriage. If the relationship between the two goes wrong, it is the woman who has to endure more. In cases of extramarital relationships as well, the partners develop cold feet when confronted with the issue of dissolving the present marriage and proceeding with a new one, as they are concerned with their offspring. Intimate partner violence is common at all places and in all strata of society. Violence causing death of married woman by hands of her husband is intentional in many cases in setting of country like India, where dowry system is deeply rooted. Pre planned murder of a wife or husband sends shivers down the spine of most of the regular people as love is the basic ingredient of this sacred relationship. Many cases of battered and murdered wives are on record. Women, killing

Corresponding Author:- Gaurav Sharma.

Address:-Senior Resident, Department of Forensic Medicine, Pt. B. D. Sharma PGIMS, Rohtak.

their husbands are usually unheard of. Mariticide as a crime might be subdivided in uxoricide (largely considered as an epiphenomenon of femicide) and husbandicide, which respectively mean the killing of one's wife, or one's husband, from the respective spouse.¹ In regular practice, mariticide connotes murder of husband by wife.

Women, killing husbands are considered either highly traumatized and they murder their spouse to find a way out of the living hell or they are psychiatrically & psychologically unstable. Women who kill for extramarital sexual gratification appear fallaciously to be stuff of fiction. Women like Stacey Ruth Castor who was found guilty of intentionally poisoning and thus murdering her two husbands have opened the lid of a can called "female power unleashed." The term black spider widow is nick name given to these women. Women like Evelyn Dick, Katherine Knight, Tillie Klimek, Stella Nickel are examples from other countries. Recently a Mohali woman, Seerat Kaur shot dead her husband of 12 years, packed his 6'3" body in a suit case and hired an auto to dump his body before she, with her extramarital boy friend were arrested. Researches have been designed to identify the contexts and motivations of partner-killing, including evolutionary perspectives and situational perspectives. Evolutionary psychologists like Buss and Shackelford argue that, over human evolutionary history, men and women have experienced conflicts of interest, with men attempting to control women's sexual behavior and women resisting that control.² We came across a curious case, where in stark contrast to the theory of rendering sexual control to her husband, this woman from eastern hinterland of Haryana did exactly the opposite and murdered her husband by throttling with the help of her boy friend, dismembered his body and buried the parts in her courtyard. (Figure 2)

Case Report:-

In the year 2012, the victim, a 31 years old male from a small village in Eastern Haryana working a contract worker was married to a woman, who later turned out to be one with easy virtue and tolerated no criticism of this lifestyle of hers despite facing problems in her married life. The family members were skeptical when they did not hear from their son or daughter-in-law for 7 days and went to the house of the couple on 26-04-2016. On entering the house, there was smell of decomposition as later confirmed in Forensic Science Visit report also. During the search, a suitcase and blankets were recovered under the wooden floor; from which dismembered remains of a male were recovered, which were in advanced state of decomposition. (Figure 1) Bottle full of alprazolam tablets was also recovered. The woman confessed of administering sedatives and then throttling her husband to death before cutting him in pieces. A case was registered against the woman and her friend U/S 148, 149, 449, 302, 201 and 120 B of Indian Penal Code. The dismembered body was taken to the nearest General Hospital, from where it was referred to PGIMS Rohtak for autopsy. As per police papers, the apparent cause of death was "murder by sharp weapon."

Autopsy findings:-

Eight different body segments of dead body of a male individual were received, which when anatomically arranged appeared to be of the same individual. These were Head, trunk with bilateral upper thigh segments and bilateral two third of arms, right forearm with hand, left forearm with hand, bilateral lower thigh segments extending till upper two third bilateral leg segments and both feet along with lower one thirds of both legs. Only underwear was present over the body. Cluster of eggs of flies were present over the body at places. Scalp hair were black and peeled off with moderate traction. Facial features were only partially identifiable. (Figure 5) Epidermis of both the hands and feet was loosened. Marbling was present over the sides of trunk. Approximated length was 185 cm. (Figure 3)

Head was received separately with upper neck portion and available skin and soft tissue margins showed multiple adjacent sharp cuts in all directions. Ecchymosis was absent. Underlying vertebral column at level of C3 and C4, hyoid bone and laryngeal cartilages were fractured into multiple fragments and adherent to the tissue tags. (Figure 4) On dissection, the body of mandible was found to be fractured on left side. (Figure 7) The exposed ends of bony trabeculae did not show any blood infiltration. The exposed soft tissues were softened and putrefied.

Similarly all the parts as seen in the figures vide infra showed sharp cuts and fractures of the protruding parts of bones. At these sites also no blood infiltration was noticed.

Injuries:-

Following injuries were present over the dismembered remains.

1. Available skin and soft tissue remnants of head segment and of neck region in the trunk showed a transversely placed reddish contusion of size 8x3 cm over the anterolateral aspect of right side of the neck. On dissection, underlying available tissues and deep muscles showed ecchymosis. (Figure 6)

2. A reddish contusion of size 3x2 cm was present over the right forearm region over its dorsal aspect situated 2 cm proximal to the wrist joint on its lateral border. On dissection, underlying tissues were ecchymosed.

Internal Findings:-

Trachea was softened with sharp cut over its proximal end where blood infiltration was not present. Findings in the internal viscera were suggestive of decomposition. Stomach mucosa showed putrefactive changes but mild hyparaemia was noticed focally. (Figure 8) Age findings were suggestive of the victim being a young adult male individual.

Investigations:-

The viscera were preserved for chemical analysis, which tested positive for Alprazolam. Bones from different segments were preserved for DNA analysis, however there was no need to resort to this as positive match for identification was made by the family members.

Opinion:-

Cause of death in the case was deduced after taking all the circumstances in consideration. The board was of the opinion that possibility of the victim having died of throttling could not be ruled out, however the cuts at the ends of dismembered segments were postmortem in nature. The time duration between death and autopsy was estimated to be between 2 and 3 days.

Discussion:-

Motivations for killing a partner might differ for men and women. Daly and Wilson in 1988 reported that men are more likely to kill in response to a partner's infidelity whereas Kirkwood thinks that motivations for women might include want for the resources. Jhonson and Hotton however think that fear for their safety or their children were the prime reasons in cases of mariticide. Pietrzak et al find that both men and women report feelings of anger in response to jealousy inducing stimuli, but they also experience sex-differentiated feelings. Men report anger as the primary feeling in response to partner infidelity but women report additional feelings including anxiety and fear. Dobash et al categorically emphasize that men tend to kill their partners using methods that require close proximity to their victims including methods that do not involve a weapon, such as beating or strangling. In unison with our case report, Langman and Dowson too state that women use weapons more often in physical conflicts with their partners.²

In 2002, in a study done by Department of Justice in United States of America, it was seen that Family violence accounted for 11% of all reported and unreported violence between 1998 and 2002. Of these, roughly 3.5 million violent crimes committed against family members; 49% were crimes against spouses, 11% were sons or daughters victimized by a parent and 41% were crimes against other family members. A single offender against a single victim was most characteristic of spouse murder and boyfriend/girlfriend murder. Of the 787 identifiable incidents of spouse murder, 90.6% involved a spouse killing his/her spouse and no one else.³

In a landmark study, Wolfgang classified weapons of murdering husband or wife.⁴

Method	Total	Husband killed by Wife	Wife killed by Husband
Shooting	34	15	19
Stabbing	46	30	16
Beating	15	0	15
Other	05	02	03

It is also evident from the table above that women tend to be resorting to deadly means to kill husbands if the situation is so.

Conclusion:-

During consideration of a mariticial act, two major perspectivex need to be addressed: the situational and the evolutionary one.⁵ Risk assessment of the spouse should be done to cut down the number of spousal homicide, if psychological or psychiatric instability is known.⁶ Lot of education and counseling should be provided to the

patients and their attendants by the doctors. In cases of tragic deaths, meticulous autopsy should be carried out. These measures help the authorities to implement justice in the fairest way.

legends:



Figure 1



Figure 2

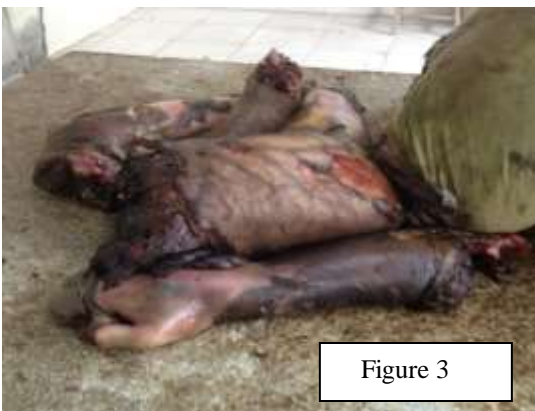

Figure 3



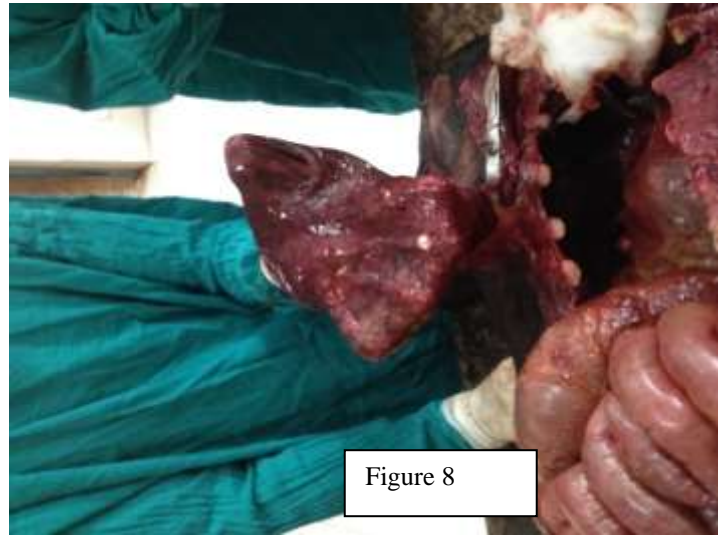
Figure 4

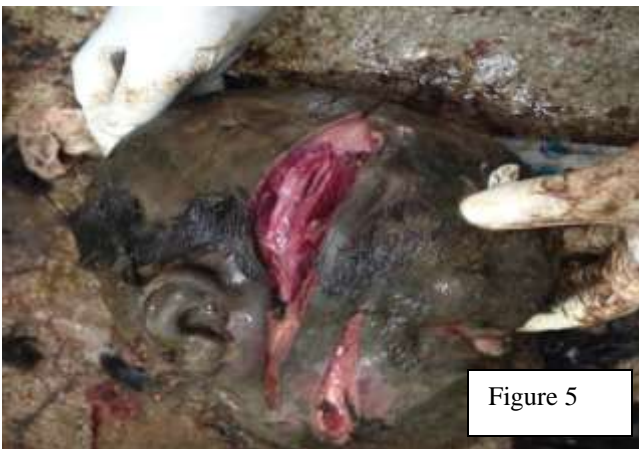

Figure 5

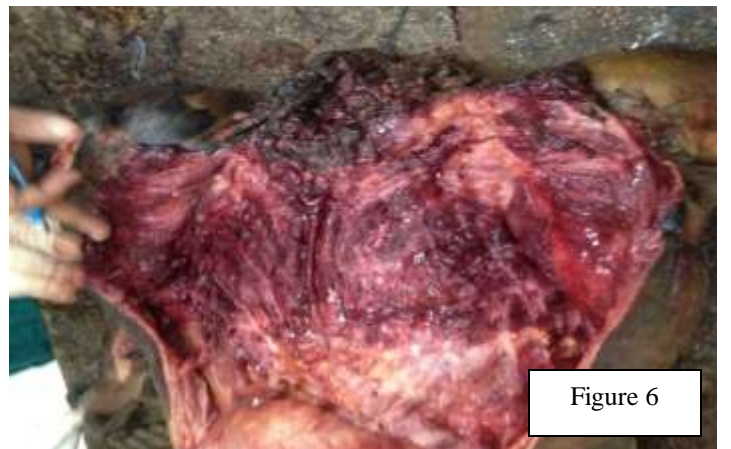

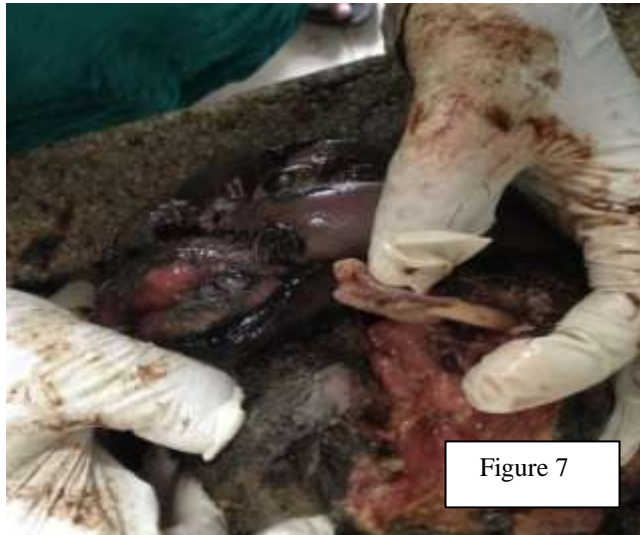Figure 6

**Reference:-**

1. Dawson J, Patrick A. Murder in families. 1994. Washington: US Department of Justice, Office of Justice Programs, Bureau of Justice Statistics.
2. Mize K D, Shackelford T K, Shackelford V A. Hands-on Killing of Intimate Partners as a Function of Sex and Relationship Status/State. *J Fam Viol.* 2009; 24:463-4.
3. Matthew R. Durose M R, Harlow C W, Langan P A, Motivans M, Rantala R R, Smith E L. Family Violence Statistics. U.S. Department of Justice. Washington DC. 2005; 1-20.
4. Howard M. Husband-wife homicide: An essay from a family law perspective. *Law and Contemporary Problems.* Vanderbilt University School of Law. 1986. 9
5. Xhemali B, Ismaili Z, Shaqiri E, Vyshka G. Mariticide as an Extreme form of Family Violence. *Anthropo.* 2015; 13: 145.
6. Drouin C, Lindsay J, Dubé M, Trépanier M, Blanchette D. Intervening with Men to Prevent Spousal Homicide. *Cri Viff. Montreal.* 2012; 28.