



Journal Homepage: - [www.journalijar.com](http://www.journalijar.com)  
**INTERNATIONAL JOURNAL OF  
 ADVANCED RESEARCH (IJAR)**

Article DOI: 10.21474/IJAR01/2662  
 DOI URL: <http://dx.doi.org/10.21474/IJAR01/2662>



### RESEARCH ARTICLE

#### EVALUATION OF AVERAGE DISTANCE FROM MANDIBULAR CANAL TO THE ROOT APICES, CEMENTO-ENAMEL JUNCTION & ALVEOLAR CREST OF MANDIBULAR MOLARS IN COASTAL ANDHRA POPULATION.

K. Bramara Kumari<sup>1</sup>, N.V.V. Satya Bhushan<sup>2</sup>, U. Siva Kalyan<sup>3</sup>, Kho Chai Chiang<sup>4</sup>, Srinivas Saketh G<sup>1</sup> and M. Bharat Prakash<sup>1</sup>.

1. Post Graduate student, Department of Oral and Maxillofacial Surgery, GITAM Dental College and Hospital.
2. Professor and Head, Department of Oral and Maxillofacial Surgery, GITAM Dental College and Hospital.
3. Reader, Department of Oral and Maxillofacial Surgery, GITAM Dental College and Hospital.
4. Senior Lecturer, Department of Oral and Maxillofacial Surgery, GITAM Dental College and Hospital.

#### Manuscript Info

##### Manuscript History

Received: 30 October 2016  
 Final Accepted: 29 November 2016  
 Published: December 2016

##### Key words:-

Inferior Alveolar neuro vascular bundle, Mandibular canal, Root apices, Cemento-enamel junction, mandibular molars and Alveolar crest

#### Abstract

The inferior alveolar nerve is the major sensory branch of the posterior trunk of the mandibular nerve which is the anatomical landmark of particular interest to Oral and Maxillofacial surgeons, reporting of injuries to the inferior alveolar neurovascular bundle following minor and major surgeries. These accidental injuries may occur because of poor knowledge of the precise location of mandibular foramen, mandibular canal and the course of mandibular neurovascular bundle. This study was done to determine the average position of the mandibular canal in relation to mandibular molars using the OPG in vertical plane. The study was conducted on 150 patient OPGs in our institution in which, 72 were females and 78 males to assess and evaluate the distance from root apices, Cemento-enamel junction at the midline of mesio-distal diameter of the tooth and alveolar crest to the Inferior alveolar neurovascular bundle of 1<sup>st</sup>, 2<sup>nd</sup> and 3<sup>rd</sup> molars on both sides of mandible in both genders of coastal Andhra population.

Copy Right, IJAR, 2016., All rights reserved.

#### Introduction:-

The inferior alveolar nerve (IAN) is the major sensory branch of the posterior trunk of the mandibular nerve. It innervates teeth, gingiva and also supplies mucosa and skin of lower lip and skin of the chin. Inferior alveolar canal which holds the neurovascular bundle is the anatomical landmark of particular interest to Oral and Maxillofacial surgeons as the damage of which may lead to permanent or long-lasting neuro-sensory alteration or loss<sup>1</sup>. There are cases reporting of injuries to the inferior alveolar neurovascular bundle following minor and major surgeries. These accidental injuries may occur because of poor knowledge of the precise location of mandibular foramen, mandibular canal (MC) and mental foramen and the course of mandibular neurovascular bundle. It is mandatory to have knowledge on position and course of MC and its relationship to posterior teeth in the mandible is of great importance to Oral and Maxillofacial surgeon to obtain the desired surgical outcome of the procedures which are carried out at different levels of mandible.

**Corresponding Author:- Dr. K. Bramara Kumari.**

Address:- Post Graduate student, Department of Oral and Maxillofacial Surgery, GITAM Dental College and Hospital.

Injury to inferior alveolar nerve is a well-known and well documented complication that might occur during surgical procedures such as third molar surgery, implant placement, osteotomies, fracture repair, root canal treatment procedures, ridge augmentation procedures, benign and malignant tumors of the mandible<sup>2</sup>. Hence, by doing a pre-operative radiographic assessment, the surgeon can provide patients with the necessary information regarding the surgical procedure, the possible risks and prepare them for potential complications and also it decreases the risk of inadvertent IAN injury associated with operative procedures<sup>3</sup>. This study was done by taking the findings of the Coastal Andhra population similar to Sudanese population<sup>3</sup>.

The routine radiographic methods used in dentistry for detecting MC are Intra Oral Periapical Radiograph (IOPAR), Orthopantomogram (OPG), Computed Tomography (CT) scan, Cone beam Computed Tomography (CBCT) . The maxillo-mandibular anatomy can be better visualized in OPG where single image of facial structures along with their supporting structures are seen simultaneously. On OPG, the MC is usually visualized in the ramus and in the molar regions, where the inferior alveolar neuro vascular bundle is in contact with the lingual cortex of mandible and this positioning of the canal makes it visible in the OPG. Considering the facts like availability of OPGs, low dose of radiation, economic status of the patient, patient convenience and its accuracy in measuring the vertical bone height of the mandible, we have chosen panoramic radiograph for this study.

This study is an attempt to localize the position of MC correctly for coastal Andhra population on both sides of the mandible in both genders in order to avoid injury during various maxillo-facial surgical procedures.

### **Materials and Methods:-**

This study was conducted in 150 patients' OPG's who reported to the Department of Oral and Maxillofacial Surgery were randomly selected for the study after Ethical committee approval. Patients with the age of 30-50 years were included in the study. Patients with missing of any molar teeth, teeth with periodontal problems, lesions involving mandible including cysts, benign or malignant tumors, patient undergone radiotherapy, medically compromised persons, systemic disorders, blood dyscrasias and OPG with unclear images.

3 parameters were selected and studied on right and left sides of the jaw for males and females. After the collection of OPGs (Fig. 1), distances were measured from the root apices (D1), Cemento-enamel junction (CEJ) at the midline of mesio-distal diameter of the tooth (D2) and alveolar crest (D3) distal to the tooth to the superior border of the MC at 1<sup>st</sup>, 2<sup>nd</sup> and 3<sup>rd</sup> molars except for 3<sup>rd</sup> molars that are impacted disto-angularly where the distance was measured from mesial alveolar crest of the tooth to superior border of the canal.

The distances were measured accurately with the help of X-ray image viewer using divider and metal scale and were measured in millimeters on both right side (rt) and left side (lt):M1= Distance from D1, D2 and D3 distal to the tooth to the superior border of canal at 1<sup>st</sup>molar, M2 for 2<sup>nd</sup> molar, M3 for 3<sup>rd</sup> molar, M3M for mesio-angular impacted 3<sup>rd</sup> molar, M3H for horizontally impacted 3<sup>rd</sup> molar, M3V for vertically impacted 3<sup>rd</sup> molar, M3D for disto-angular impacted 3<sup>rd</sup> molar

### **Results:-**

All the data was entered in Microsoft Excel worksheet and analysis was done by using SPSS 20.1 version (statistical package for social sciences) software by percentage analysis, Mann Whitney test to find out the statistical difference between male and female groups and on right (rt.) and left (lt.) sides of mandible in terms of distance from neurovascular bundle to D1, D2 and D3 of mandibular molars [M1 {Fig 2} , M2 {Fig 3}, M3 {Fig 4}, M3M {Fig 5}, M3H {Fig 6}, M3V {Fig 7}, M3D {Fig 8}]. These were the criteria used for evaluation. There was no statistical difference observed between both genders and on both sides of the mandible for 1<sup>st</sup>, 2<sup>nd</sup> and 3<sup>rd</sup> molars (P-value >0.05).

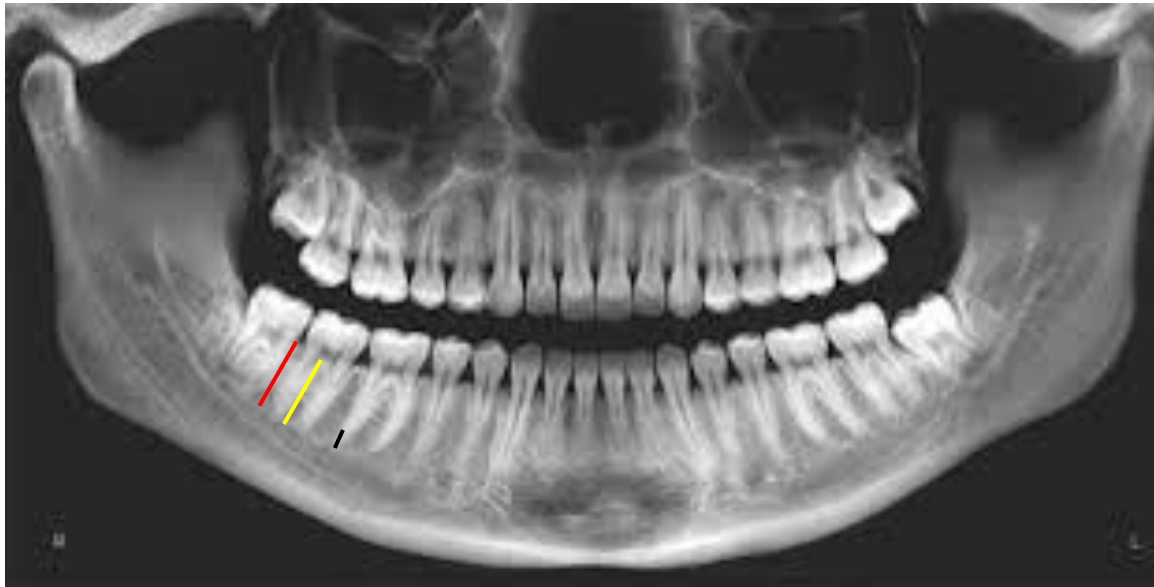


Fig 1:- Orthopantomograph (D1- Black, D2 –Yellow, D3 - Red )

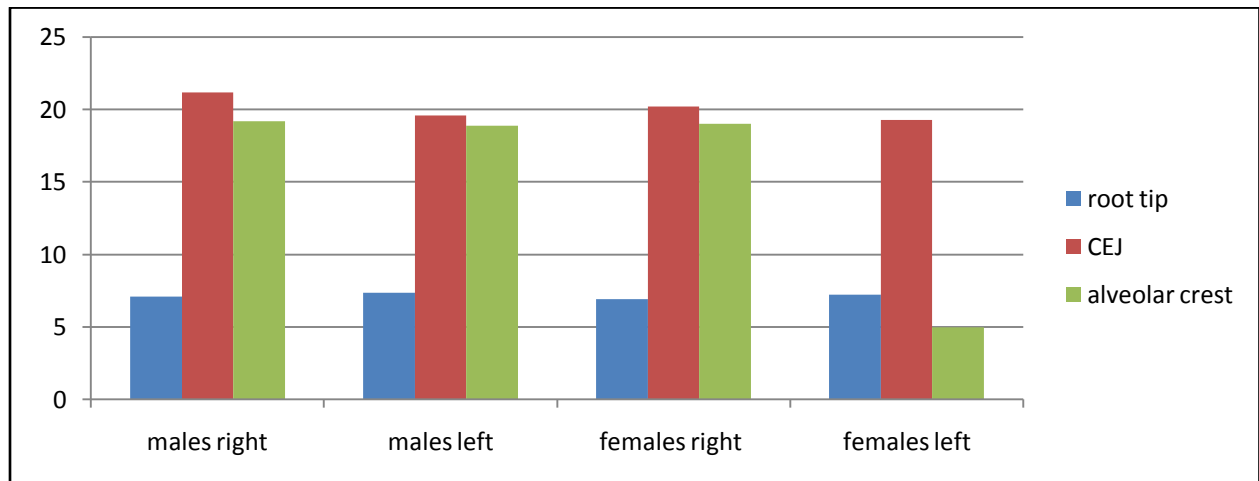


Fig 2:- Distance at D1, D2 and D3 on both right and left Sides of the jaw in both the genders at 1<sup>st</sup> molar region

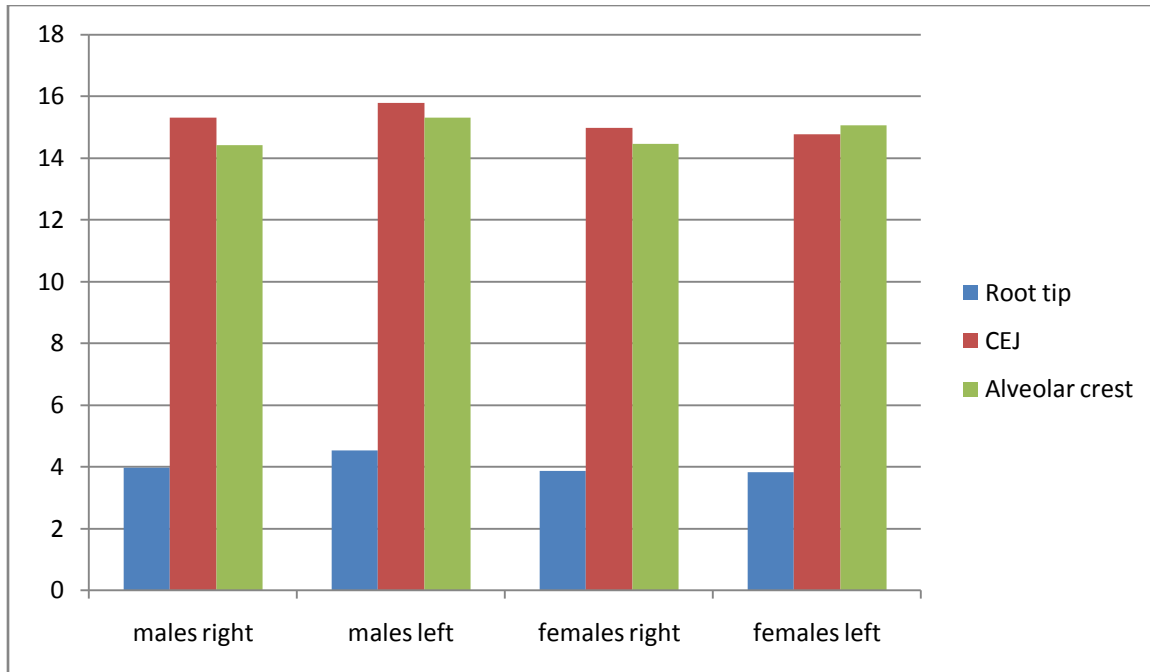


Fig 3:-Distance at D1, D2 And D3 on both right and left sides of the jaw in both the genders at 2<sup>nd</sup> molar region

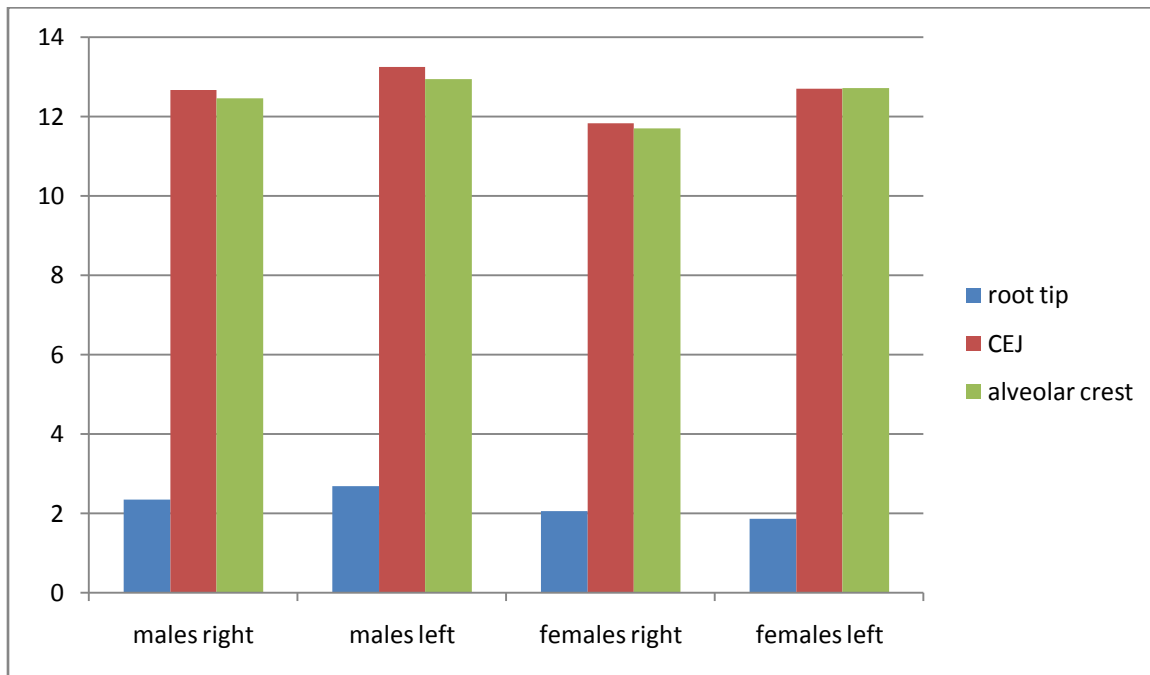
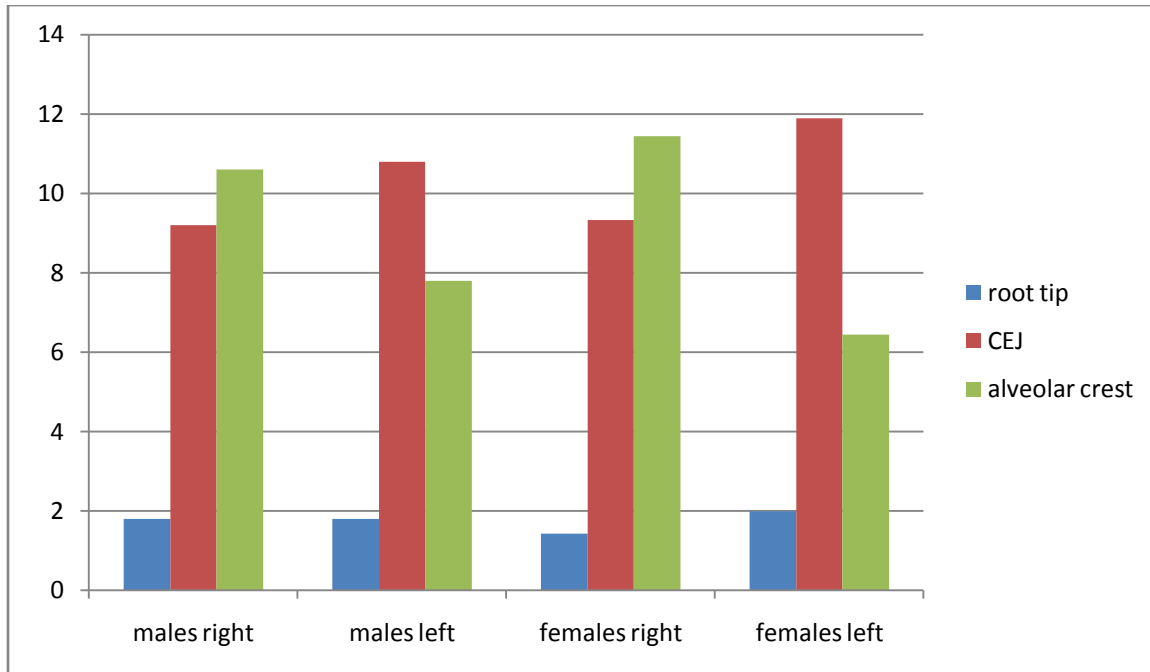
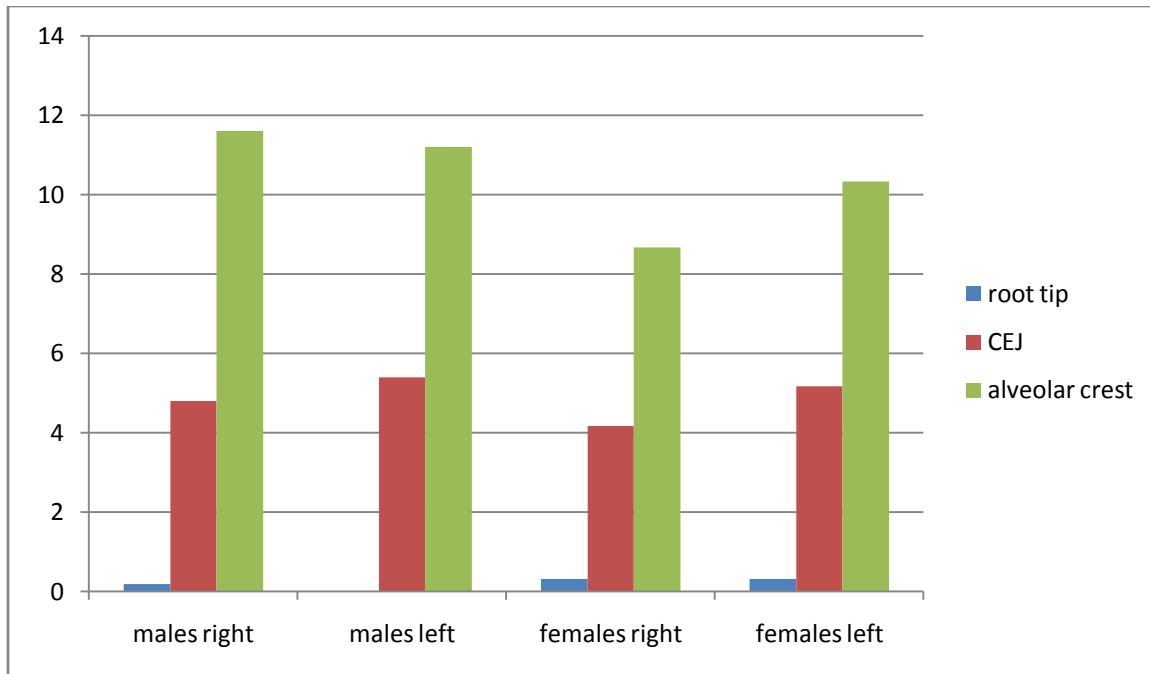


Fig 4:- Distance at D1, D2 And D3 on both right and left sides of the jaw in both the genders at 3<sup>rd</sup> molar region



**Fig 5:-** Distance at D1, D2 and D3 on both right and left Sides of the jaw in both the genders at mesio-angular impacted 3<sup>rd</sup> molar region



**Fig 6:-** Distance at D1, D2 and D3 on both right and left sides of the jaw in both the genders at horizontally impacted 3<sup>rd</sup> molar region

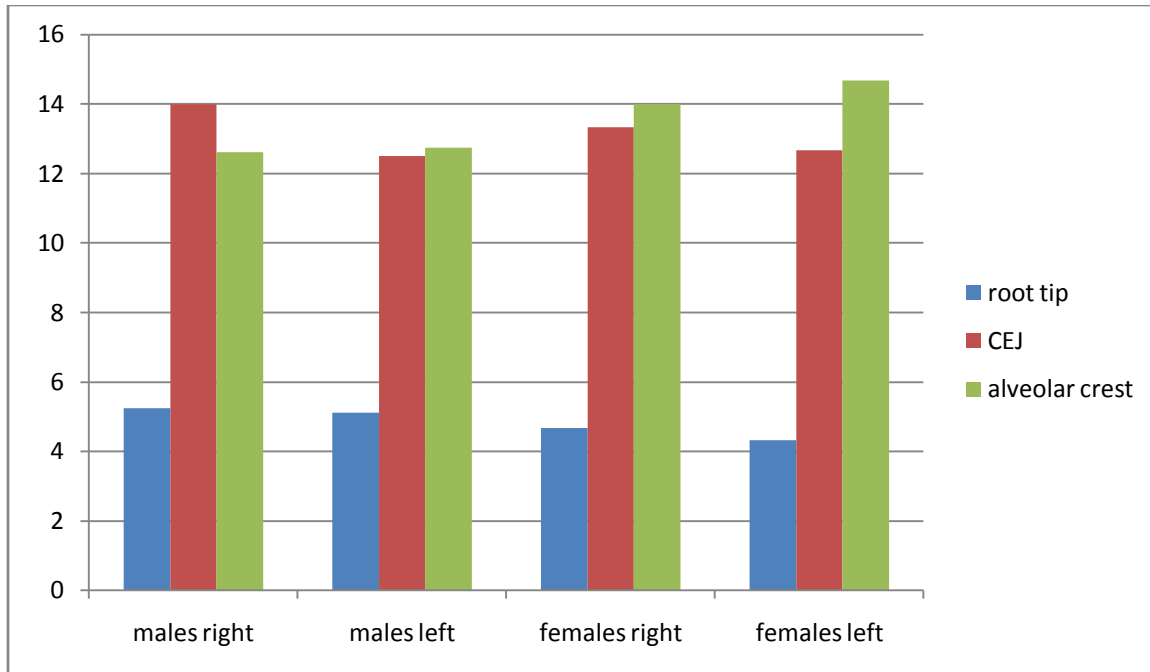


Fig 7:- Distance at D1, D2 and D3 on both right and left Sides of the jaw in both the genders at vertically impacted 3<sup>rd</sup> molar region

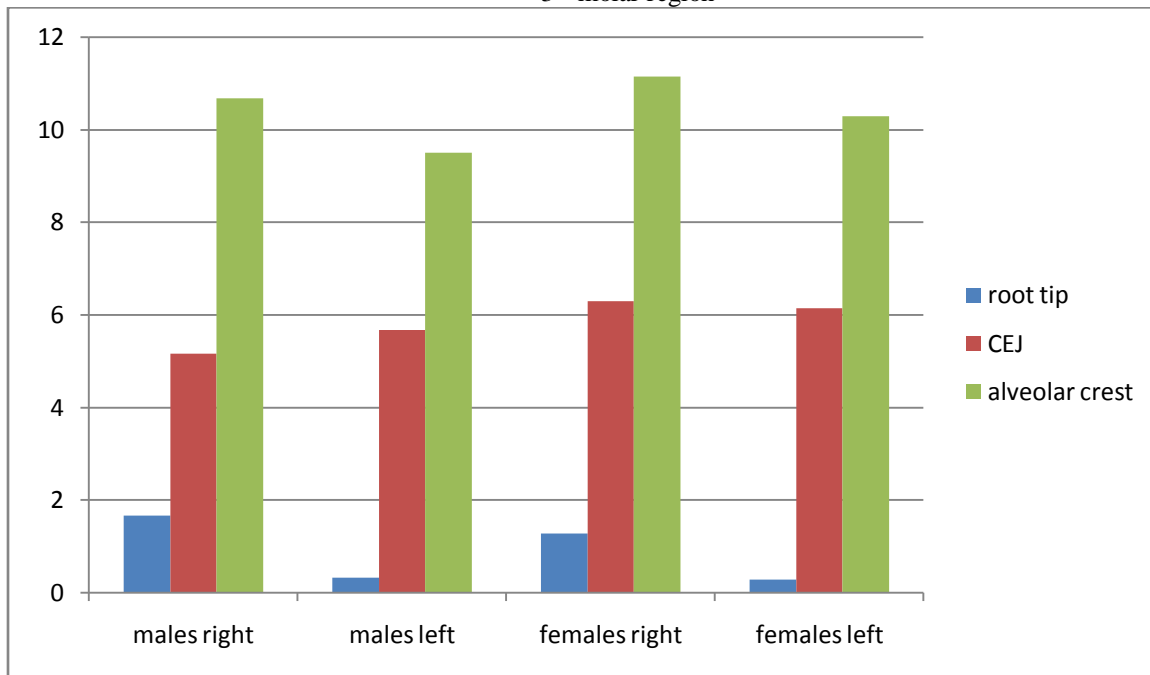


Fig 8:-Distance at D1, D2 and D3 on both right and left sides of the jaw in both the genders at disto-angular impacted 3<sup>rd</sup> molar region

**Discussion:-**

Knowledge of the anatomy of the MC and its location is of great importance to the Oral and Maxillofacial surgeon. Many researches have been done to study the anatomy including location, shape and course of the inferior alveolar canal with different radiographic methods including OPG, conventional CT scan as well as morphological studies in cadavers.

The inferior alveolar nerve travels within the inferior alveolar canal (IAC) in the mandible, and is thus supported by the alveolus and the neurovascular bundle. Anatomically, the inferior alveolar vein is the most superior structure in the canal. When rotary instruments penetrate the canal, the bleeding will alert the surgeon that the superior aspect of the bony canal has been breached and the vein is injured. More profuse bleeding usually indicates damage to the inferior alveolar artery, which lies underneath the vein and superior to the nerve.

Despite a number of anatomical descriptions of the IAN, there is no consensus on its course and pattern of its distribution. Traditionally there are two methods of IAN course and pattern investigation: cadaveric study and medical imagination methods. First attempt to classify the IAN anatomy was provided by Olivier<sup>4</sup> in 1928. He described two typical patterns based on the dissection of 50 mandibles: Type I, the IAN was a single structural entity with branches to the individual teeth, and was observed in 66% of cases; Type II, observed in 34% of cases, the IAN formed a plexus from which individual teeth were supplied. Carter and Keen<sup>5</sup>, who studied on 8 human mandibles, classified the IAN into three categories: the most common category consisted of a single nerve trunk that coursed directly beneath the apices of the mandibular teeth; the second category consisted of a large nerve from which individual nerves supplied the lower teeth; and the third category consisted of a nerve trunk superior to which there was a plexus that supplied the teeth.

Possible causes of inferior alveolar nerve injury are nerve transpositioning, grafting procedures, infection and soft tissue retraction during surgery, implant surgery, surgical removal of impacted third molar, osteotomies, loco-regional anesthetic injections, endodontic treatment, orthognathic surgery, fracture management, resection of benign and malignant tumors of the mandible.

Heasman<sup>6</sup> reported, from a study of 96 plain films of dried mandibles, in 68% of the cases the MC passed along an intermediate course between the mandibular root apices and the inferior border of the mandible. A mean distance of 10 mm between the MC and the inferior mandibular border, proximally to the third molar region has been reported. According to Juodzbalys et.al<sup>7</sup>, in 70% of cases the MC and inferior alveolar neurovascular bundle stretches throughout the mandible body forming an “S” shape curve. It approaches the lingual surface of the mandible in the area of the molars, and stretching forwards to the front part, comes closer to the vestibular surface. In order to plan any type of surgery in the mandibular posterior teeth region, location of MC is mandatory to prevent complications.

A frequent and serious complication associated with removal of impacted mandibular third molars is injury to the sensory nerve bundle. In a 1973 survey of more than 1200 oral and maxillofacial surgeons, Schwartz<sup>8</sup> found that 66% of respondents had treated patients who had sustained nerve damage after mandibular 3<sup>rd</sup> molar odontectomy. Permanent nerve damage was occurred in 418 cases and 2399 cases of temporary nerve damage were reported.

Denio et.al<sup>9</sup> did study on the spatial relationship of the MC to the posterior teeth in 22 dried matured human mandibles. In this study, they recorded the distances from root apices of 1<sup>st</sup>, 2<sup>nd</sup> premolars and 2<sup>nd</sup> molars to the MC. 2<sup>nd</sup> premolar and 2<sup>nd</sup> molar had the closest distances to the canal with a mean of 4.7mm and 3.7mm respectively.

Denio et al<sup>9</sup> evaluated 22 cadavers and found the mean distance of the MC to the apices of mandibular second molar, the first molar and premolars were 3.7, 6.9, and 4.7 mm respectively which is in coherent with the present study,

Tamas F<sup>10</sup> conducted retrospective studies reported an 80% to 100% incidence of neurosensory disturbance immediately after Bilateral Sagittal Split Osteotomy (BSSO). Operative injury to the vascular and nerve bundle within the MC also represents a main risk factor during sagittal split osteotomy of the ramus leading to impairment of the inferior alveolar nerve.

OPG is only two-dimensional, which makes it difficult to assess available bone width. The accuracy of OPG is quite low due to distortion in the horizontal plane and magnification in the vertical plane, and greatly depends on the correct patient positioning. CT can also be used to assess the bone quantity and quality but patients are exposed to a high radiation dose. In the present study, digital OPG was used due to quick, low dose of radiation, low cost, patient convenience, less time and its accuracy in measuring the vertical bone height of the mandible. It was designed to clearly determine the path of the MC and to localize the MC and its relationship on both sides of the mandible and in both genders in coastal Andhra population using appropriate application of OPG. A total of one hundred and fifty

(150) suitable patients records were selected aged between twenty (20) and sixty (60) with permanent dentition were included. MCs should be clearly visible in the OPG's on both left and right sides and 1<sup>st</sup>, 2<sup>nd</sup> & 3<sup>rd</sup> molars should be present on both left and right sides of the mandible. Impacted molars were also included in the study. Patients with systemic health problems or are medically compromised or radiotherapy were excluded.

In the present study, we used 7 variables including (M1, M2, M3, M3M, M3H, M3V, M3D) and 3 parameters (D1, D2, D3) in both sides and in both gender (males and females) to localize the inferior alveolar canal which is important in many surgical procedures where the nerve paths though and may be affected, which was a critical point during surgery. Measured the distances of variables at different sites of mandibular molars and in males and females were M1 in mm found to be (D1=6.93, D2=19.27, D3=18.88), M2 was found to be (3.98, 14.76, 14.41), M3 (1.87, 11.83, 11.70), M3M (1.40, 9.20, 8.94), M3H (0.33, 4.17, 9.50), M3V (4.33, 12.67, 14.00), M3D (0.79, 6.14, 10.29).

Levine et al<sup>11</sup> did one of the interesting clinical and radiographic using the CT imaging technique among US population. They reported that the MC was  $17.4 \pm 3.00$  mm from the superior cortical surfaces of the mandible at the mandibular first molar. In the present study, distance from first molar to the superior border of the MC was  $18.8 \pm 1.00$  mm. There is no significant difference from the present study to Levine et.al study at first molar region.

The results of this study, strongly concludes that the measures on the right are similar to the measures on the left side of the jaw which is in coherent with the study of Levine et al<sup>11</sup>, Narayana and Vasudha<sup>12</sup> and Kieser et al<sup>13</sup>. Recording the measurement on both sides of the jaw in clinical studies may then produce cluster sampling as well as duplication of the data, which then becomes unnecessary in metrical analyses. One side is therefore sufficient in future studies.

Watanabe et al<sup>14</sup> analyzed CT data of 79 Japanese patients (52 male and 27 female) and found that the distance from the alveolar crest to the MC ranged from 15.3 to 17.4 mm. It is clear that the distance between the MC and the atrophic alveolar ridge is variable dimension and should be assessed in each particular case. In the present study, the distance from alveolar crest of molars to MC ranges from 14.41 to 19.01 mm similar to our study.

According to Obrodavic et.al<sup>15</sup>, the main objective is to study the significance of data collected from right and left side of the mandible and to determine whether it is suitable to use data from both side of the jaw in conducting clinical researches. There was no significant difference observed on right and left sides of the mandible which is similar to the present study.

In the present study, the comparison between the distances from the root tip, CEJ, and alveolar crest in males and females on both the right and left sides of the jaw showed that the 1st molar region showed highest values in comparison with the 2<sup>nd</sup> and 3<sup>rd</sup> molar region. Horizontally impacted third molar is closer to MC at Root apex (D1) and Midline of CEJ (D2) relatively to other types of impaction. Hence, surgeons has to be careful while doing horizontal impaction as there is only 0.33mm & 4.17mm distance between root tip & midline of CEJ to superior border of MC beyond which nerve damage occurs. Sectioning of the tooth and careful retrieval minimize the damage. Mesio-angular impacted third molar is closer to MC at alveolar crest (D3) relatively to other types of impaction as there is only 8.94mm distance between alveolar crest to superior border of MC.

It can be observed that comparison between males and female measurements done on the right and left side showed no significance ( $p > 0.05$ ).

### **Conclusion:-**

The relationships between mandibular molars and MC in vertical plane are recorded and the obtained results are at M1 in mm found to be (D1=6.93, D2=19.27, D3=18.88), M2 was found to be (3.98, 14.76, 14.41), M3 (1.87, 11.83, 11.70), M3M (1.40, 9.20, 8.94), M3H (0.33, 4.17, 9.50), M3V ( 4.33, 12.67, 14.00), M3D (0.79, 6.14, 10.29), which can help the surgeons to make precise surgical plans, to limit their extension beyond these distances and reduce the incidence of complications, particularly the risk of damage to the inferior alveolar neurovascular bundle. Eventhough, this study measured the distance between molars and MC, due to the small size of the sample, future studies are required with large sample size in order to get the standardized distances and to establish the complication free surgeries.



**References:-**

1. Renton T, Hankins M, Sproate C, McGurk M - A randomised controlled clinical trial to compare the incidence of injury to the inferior alveolar nerve as a result of coronectomy and removal of mandibular third molars. *British Journal of Oral and Maxillofacial Surgery* 2005; 43: 7-12
2. Xu GZ, Yang C, Fan XD, Yu CQ, Cai XY, Wang Y, He DM - Anatomic relationship between impacted third mandibular molar and the mandibular canal as the risk factor of inferior alveolar nerve injury. *British Journal of Oral and Maxillofacial Surgery* 2013; 51:215-219
3. Ayad CE, Elhag ZA, Abdulla EA, Elfadil M, Kajoak S- Characterization of inferior alveolar canal in Sudanese population using orthopantomography. *International journal of Medical imaging* 2013; 1(3):39-44
4. Santos CO & Souza PH, Couto SA, Stinkens L, Moyaert K, Bullen IR & Jacobs R - Assessment of variations of the mandibular canal through cone beam computed tomography. *Clin Oral Invest* 2012; 16:387-393
5. Carter RB, Keen EN – The intra mandibular course of the inferior alveolar nerve. *J Anat.* 1971; 108: 433-440
6. Heasman PA – Variation in the position of inferior dental canal and its significance to restorative dentistry. *J Dent* 1988; 16(1): 36-39
7. Juodzbaly G, Wang HL, Sabalys G – Anatomy of mandibular vital structures. Part I : Mandibular canal and inferior alveolar neurovascular bundle in relation with dental implantology. *J Oral Maxillofac Res* 2010; 1: e2 1-8.
8. Schwarz MS, Rothman SL, Chefetz N, Rhodes M – Computed tomography in dental implantation surgery. *Dental Clinics of North America* 1989; 33(4): 555-597
9. Denio D, Torabinejad M, Bakland LK. Anatomical relationship of the mandibular canal to its surrounding structures in mature mandibles. *J Endod* 1992;18:161-5.
10. Tamas F. Position of the mandibular canal. *Int J Oral MaxillofacSurg*1987; 16: 65-69.
11. Levine MH, Goddard AL, Dodson TB. Inferior alveolar nerve canal position: A clinical and radiographic study. *J Oral MaxillofacSurg* 2007; 65: 470-4.
12. Narayana, K. & Vasudha, S. Intraosseous course of the inferior alveolar (dental) nerve and its relative position in the mandible. *Indian J Dent Res*2004;15: 99-102.
13. Kieser, J., Kieser, D. & Hauman, T. The course and distribution of the inferior alveolar nerve in the edentulous mandible. *J CraniofacSurg*, 2005;16: 6-9.
14. Watanabe H, Mohammad Abdul M, Kurabayashi T, Aoki H. Mandible size and morphology determined with CT on a premise of dental implant operation. *SurgRadiolAnat* 2010;32: 343-9.
15. Obradovic O, Todorovic L, Pesic V, PejkoVIC B, Vitanovic V. Morphometric analysis of mandibular canal: Clinical aspects. *Bull Group IntRechSciStomatolOdontol* 1993; 36:109-13.