



Journal Homepage: - [www.journalijar.com](http://www.journalijar.com)  
**INTERNATIONAL JOURNAL OF  
 ADVANCED RESEARCH (IJAR)**

Article DOI: 10.21474/IJAR01/6176  
 DOI URL: <http://dx.doi.org/10.21474/IJAR01/6176>



**RESEARCH ARTICLE**

**PRECANCEROUS LESIONS OF PROSTATE A CLINICO-PATHOLOGICAL STUDY.**

**Dr. S. S. Haider<sup>1</sup>, Dr. Tahsin Munsif<sup>2</sup> and Dr. Vineeta Tewari<sup>3</sup>.**

1. Assistant Professor Department of Surgery Eras Lucknow Medical College (ELMCH).
2. Assistant Professor Dept of Anatomy, ELMCH.
3. Professor, Dept of Anatomy, ELMCH.

**Manuscript Info**

**Manuscript History**

Received: 01 November 2017  
 Final Accepted: 03 December 2017  
 Published: January 2018

**Key words:-**

Prostate cancer, PIN, Precancerous lesions, Peripheral zone of prostate.

**Abstract**

**Background:** Prostate cancer is one of the most common malignancies diagnosed in men & is the most common cancer found in men older than 60 years. One third of all men older than 50 years have a latent form of prostate cancer that may progress to life threatening Prostate cancer. In this study all the precancerous lesions were more common in the higher age groups (60-69 and 70-79 years).

**Material And Methods:** The present study has been performed on 100 patients in the department of Surgery , Eras Lucknow medical college and hospital. The age of the patients varied from 40-80 years. Maximum proportion of patients (34%) were aged between 60-69 yrs followed by 70-79 yrs (30%). There were 12% patients in age grp 40-49 yrs and 24% were in the age group of 50-59 years. Thus it was seen that the complaints of lower urinary tract system or prostatic disease were common in higher age group.

**Results:** In this study all the precancerous lesions were more common in the higher age groups (60-69 and 70-79 years). However , no statistically significant association between type of lesion and age could be established in this study (p=0.267). Studying the histopathology only peripheral and central zones were seen to be involved. Peripheral zone was involved in 4/5 (80%) cases while central zone was involved in 1/5 (20%) cases Overall, in the present study, PIN was found to be an efficacious marker for prognosis of prostate carcinoma.

*Copy Right, IJAR, 2018,. All rights reserved.*

**Introduction:-**

The advent of modern era of medicine has blessed humans with increase in their life expectancy. The diseases of elderly population contribute to a large group of patient in surgical OPD

Prostate cancer is one of the most common malignancies diagnosed in men & is the most common cancer found in men older than 60 years. One third of all men older than 50 years have a latent form of prostate cancer that may progress to life threatening Prostate cancer.

Age adjusted incidence of prostate cancer in US is 69 per 100000. The incidence of latent prostate cancer is even higher, increasing from 20% in men in their 50s to approximately 70% in men between the ages of 70 & 80 years. Fortunately, prostate cancer is much less common in Asians. This is probably because of environmental influences,

**Corresponding Author:- S. S. Haider.**

Address:- Assistant Professor Department of Surgery Eras Lucknow Medical College (ELMCH).

including diet. In the present day scenario, as the diet in our country is becoming more westernised, so also the incidence of clinical prostate cancer would be rising. Therefore, the importance of early detection of this disease and specially recognition of its precancerous lesions becomes very significant.

Prostatic intraepithelial neoplasia (PIN) , particularly high grade PIN and atypical small acinar proliferation ASAP have been identified as precursor lesions to prostatic carcinoma. PIN refers to the precancerous end of a morphologic spectrum involving cellular proliferation within prostatic ducts, ductules and acini. PIN is a condition in which some prostate cells have begun to look and behave abnormally. The epithelial cells lining the acini and ducts become abnormal, but the lining itself remains intact(1) PIN first described in 1969 is a neoplastic proliferation of prostatic epithelial cells that is confined to pre-existing prostatic ducts or acini(2). Now PIN is commonly divided into low grade and high grade PIN(3). HGPIN have been described as Tufting, Micropapillary, Flat , Cribriform(4). Tufting is the most common (97%) to develop adenocarcinoma prostate.

PIN does not significantly elevate serum PSA concentration or its derivatives, nor does it induce a palpable mass and cannot be detected by USG(5). Androgen deprivation therapy decrease the prevalence and extent of PIN. Radiation therapy is also associated with decreased incidence of PIN(6)

**Aims And Objectives:-**

To identify and categorise precancerous lesions of prostate by histopathological examination.

**Study Design:-**

This study was a prospective observational cross-sectional study.

**Study Area And Population:-**

The study was carried out in Eras Lucknow Medical college, Lucknow.

All male patients patients above 40 years of age , visiting hospital surgery OPD with history of lower urinary tract symptoms and distributed according to IPSS (International Prostate Symptom Score) score range.

Patients who were undergoing simple prostatectomies for benign reasons were also included in the study

**Sample Size:-**

N = 100

Patients who had not given consent and who had bleeding disorders or systemic illness were excluded from this study

**Method:-**

All the patients included in the study were subjected to history taking, clinical examination, DRE, PSA examination, TRUS and TRUS guided multiple site prostate biopsy.

Prostate biopsy was done with a transrectal approach. Needle guidance system that clamp onto the side of the probe were available for end firing and side firing. Electronic guidelines direct the needle pass the automatic biopsy gun with 18 gauge needle was used. The probe used was 8 MHz. With the help of gun, the needle was passed in the guide, ensuring that the tip was safely inside the guide. A simple swift motion advances the gun and needle tip to the surface of lesion. Once triggered the needle advances 2-3 cms with the push of button. The inner needle advances and the outer needle cuts the tissue core and traps it in the veveled chamber of inner needle

**Histopathology:-**

The biopsy cores were collected in separate labelled containers with 10% formalin. Biopsy specimen were sent along with duly filled registration forms. The lesions were graded as per standard internationally accepted systems.

**Statistical Analysis:-**

The data was analyzed using Statistical package for social sciences version 15.0.

**Results:-**

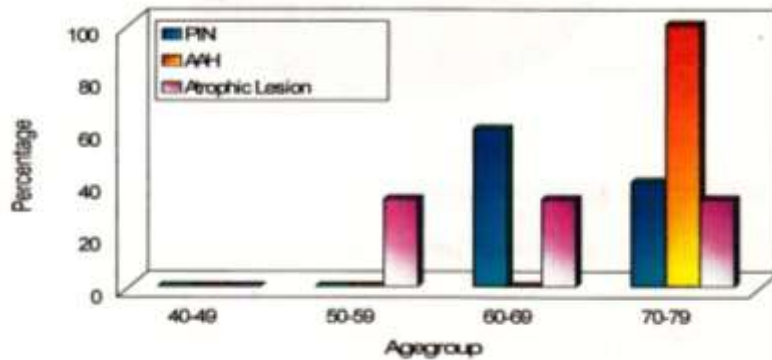
The present study has been performed on 100 patients in the department of surgery , Eras Lucknow medical college and hospital. The age of the patients varied from 40-80 years. Maximum proportion of patients (34%) were aged between 60-69 yrs followed by 70-79 yrs (30%). There were 12% patients in age grp 40-49 yrs and 24% were in the

age group of 50-59 years. Thus it was seen that the complaints of lower urinary tract system or prostatic disease were common in higher age group.

In this study all the precancerous lesions were more common in the higher age groups (60-69 and 70-79 years). None of the cases with PIN was seen in lower age groups. However, no statistically significant association between type of lesion and age could be established in this study (p=0.267).

**Table 1:-** Precancerous lesions in different age groups

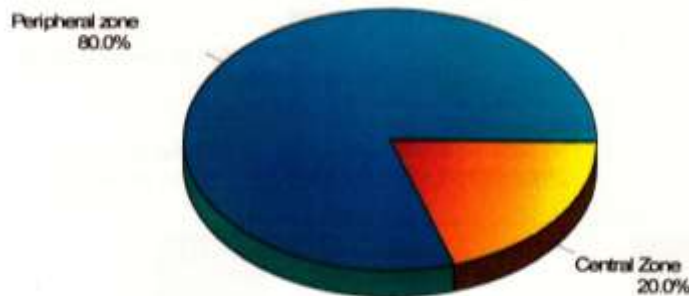
Age group (in years)	No of patients	PIN(n=5)		AAH(n=2)		Atrophic Lesion(n=6)	
		No	%	No	%	No	%
40-49	12	0	0	0	0	0	0
50-59	24	0	0	0	0	2	33.3
60-69	34	3	60	0	0	2	33.3
70-79	30	2	40	2	100	2	33.3
Total	100	5	100	2	100	6	100



On studying the histopathology only peripheral and central zones were seen to be involved. Peripheral zone was involved in 4/5 (80%) cases while central zone was involved in 1/5 (20%) case

**Table 2:-** Location of PIN lesions (n=5)


S.No	Location	No of cases	Percentage
1	Peripheral zone	4	80
2	Central zone	1	20
3	Transitional zone	-	-
4	Anterior zone	-	-
5	Periurethral zone	-	-



Patients were called for regular follow up and rebiopsy was taken after 18 months in suspected cases.

**Table 3:-** Correlation of PIN findings With Rebiopsy Results after 18 months (n=99)

PIN Status at Baseline	Rebiopsy Result after 18 month		Total
	Malignant	Benign	
Positive	3(a)	2(b)	5
Negative	0(c)	94(d)	94
Total	3	96	99



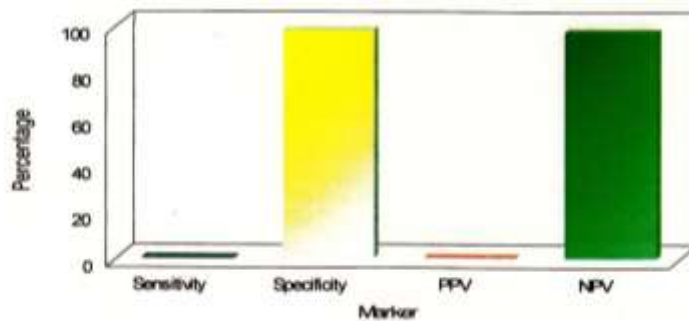
Diagnostic efficacy of PIN

Sensitivity =  $a/(a+c)=3/3=100\%$

Specificity =  $d/(b+d)=94/96=97.2\%$

Positive predictive value =  $a/(a+b)=3/5=60\%$

Negative predictive value =  $d/(c+d)94/94=100\%$



Though PIN was found to be 100% sensitive and 97.9% specific for prognosis of malignancy its positive predictive value was only 60%. Overall, in the present study, PIN was found to be an efficacious marker for prognosis of prostate carcinoma.

**Discussion:-**

Prostate cancer rarely causes symptoms until it is advanced. Thus suspicion of prostate cancer resulting in recommendations for prostatic biopsy is raised by abnormalities found on DRE or PSA elevation. Controversy about decision making for prostate biopsy is one of the problems in this time(7). Study of precancerous lesion of prostate is important for understanding prostatic carcinogenesis and for developing protective chemoprotective measures for prostate cancer(8).

Transrectal ultrasound guided biopsy is the definitive method for detecting PIN and early invasive prostate cancer(9).

Out of 100 patients studied, 30 were aged above 70 years while 34 were aged between 60-69 years. The prospects of prostate cancer and prostate disorders increase in the higher age groups. It is estimated that at least one third of men over the age of 50 years have a lent form of the disease that may eventually develop in prostate cancer. Although all the five cases with HGPIN were in the age group 60-69 years and 70-79 years which is in contrast with the generally

proposed hypothesis that PIN is an early indicator of prostate cancer. The prevalence of HGPIN in men aged 80 years is 70%. The incidence of prostate cancer in enrolled patients above age 40 years was found to be 4% (1 case detected at first biopsy and 3 cases who were found to be malignant at repeat biopsy). This is in accordance with findings of Sunny et al(10) who in their study reported an expected incidence of 1 out of 59(1.69%) among the men above age of 50 years. In the present study, though the incidence has been 4% which is more than double the incidence reported by Sunny L et al, which can be attributed to the fact that all the subjects enrolled in the study were having complaints of lower urinary tract or prostate disorders. Thus, the higher prevalence in the present study could attributed to selection of relatively higher risk subjects.

The incidence of HGPIN in present study was 5% amongst the risk subjects. In the literature, there has been a marked variability in the incidence of high grade PIN on biopsy. It has been reported on an average to be 6% by Bostwick et al() while Wills et al(11) reported its incidence to be 5.5%. In some other studies such as that of Orozco et al,(12) amongst 62,537 patients the incidence has been reported to be 4.1% while Novis et al(13) in a series of 15,753 patients reported its incidence to be slightly lower at 3.9%. Thus the incidence of HGPIN in present series is in vicinity with the above findings. However, our study has some contrast from the studies as the study was not a population survey rather it has tried to explore the incidence of HGPIN amongst the suspect high risk patients.

### **Conclusion:-**

On the basis of observations made and their analysis in our study the prevalence of precancerous lesion was found to be 13% in the patients with complaints of urogenital tract and aged above 40 years. On histopathology only peripheral and central zones were seen to be involved. Peripheral zone was involved in 80% cases while central zone was involved in 20% cases. Overall, in the present study, PIN was found to be an efficacious marker for prognosis of prostate carcinoma.

### **Acknowledgement:-**

I acknowledge Late Dr Prof RC Jain my guide and mentor for his kind help and support. I also acknowledge Dr Prof Bhatt, Dr Khandury for their help and support. Without them the work was impossible.

**Conflict of interest:** None

### **References:-**

1. Harvard Prostate Knowledge.
2. McNeal, JE. Origin and development of carcinoma in prostate. *Cancer* 1969;23:24.
3. Drago, JR, Mastofi, FK, Lee, F. Introductory remarks and workshop summary. *Urology* 1992;39:2.
4. Bostwick DG, Amin MB, Dundore P, Marsh W, Schultz DS. Architectural pattern of high grade prostatic intraepithelial neoplasia. *Hum Pathol.* Mar 1993;24(3):298-310.
5. Bostwick DG. Prostatic intraepithelial neoplasia. *Current Urology reports* 2000;1(1):65-70.
6. Bostwick DG, Neumann R, Qian J, Cheng L. Reversibility of Prostatic intraepithelial Neoplasia. Implications for chemoprevention. *Eur Urol* 1999;35:492-495.
7. Shahrokh F Shariat, Claus G Roehrbom. Using Biopsy to Detect Prostate Cancer. *Urology*2008;10(4):262-280.
8. Ximing J Yang. Precancerous lesions of prostate:Pathology and clinical implications. Uptodate Literature review July 2017.
9. Stanley A Brosman.Precancerous lesion of the Prostate.Medscape Feb 2017.
10. Sunny L, Yeole BB, Kurkure AP, Hakama M, Shiri R,Mathews S, Shastri NG, Advani SH. Cumulative risk and trends in prostate cancer incidence in Mumbai, India. *Asian Pac J Cancer Prev.* 2004 Oct-Dec;5(4):401-5.
11. Wills M, Hamper U, Partin A, Epstein J. Incidence of high grade prostatic intraepithelial neoplasia in sextant needle biopsy specimens. *Urology* 1997;49(3):367-373.
12. Orozco R, O Dowd G, Kunnel B, Miller MC, Veltri RW. Observations on pathology trends in 62,537 prostate biopsies obtained from urology private practices in the United States. *Urology.* Feb 1998;51(2):186-95.
13. Novis DA, Zarbo RJ, Valenstein PA. Diagnostic uncertainty expressed in prostate needle biopsies. A college of American Pathologists Q-probes Study of 15,753 prostate needle biopsies in 332 institutions. *Arch Pathol Lab Med.* Aug 1999;123(8):687-92.