



Journal Homepage: -[www.journalijar.com](http://www.journalijar.com)

## INTERNATIONAL JOURNAL OF ADVANCED RESEARCH (IJAR)

Article DOI:10.21474/IJAR01/11480  
DOI URL: <http://dx.doi.org/10.21474/IJAR01/11480>



### RESEARCH ARTICLE

#### INCIDENTAL MORGAGNI HERNIA FOUND DURING PANCREATITIS ACUTE: CASE REPORT

Ratbi El. Amine, Bakali Youness, Lemhouer Walid, Alaoui Mhamdi Mouna, Sabbah Farid, Raiss Mohamed  
and Hrra Abdelmalek

Surgical Clinic C, University Hospital Ibn Sina, Rabat, Morocco.

#### Manuscript Info

##### Manuscript History

Received: 05 June 2020

Final Accepted: 10 July 2020

Published: August 2020

##### Key words:-

Morgagni Hernia, Laparoscopy, Mesh-Free Repair

#### Abstract

Morgagni hernia or parasternal hernia is a very rare entity of congenital diaphragm hernia with a frequency of 3% of all diaphragmatic hernias, is defined as the intrathoracic protrusion of abdominal viscera through a defect in anterior diaphragm. We report a case of 60-years-old female with no past medical history, incidentally discovered Morgagni hernia during an abdominal CT for acute pancreatitis. Her vital signs were normal, while physical examination was founded discomfort and tenderness during epigastric palpation without any other associated signs. Abdominal TC was performed, and images before the administration of contrast material showed the Morgagni hernia with the presence of abdominal viscera inside chest cavity associated to the diastasis of the 5 (mm? cm?) diaphragmatic fibres, the hernial sac containing a part of stomach and transverse colon and none signs of obstruction. The patient underwent the reduction of the content hernia excision of the sac and mesh-free repair method using non-absorbable sutures an laparoscopy, the patient evolved favourably. The aim of this study was to describe the clinical characteristics and surgical outcomes of MH repair based on operative approach.

Copy Right, IJAR, 2020. All rights reserved.

#### Introduction:-

Morgagni hernia or parasternal hernia is a very rare entity of congenital diaphragm hernia with a frequency of 3% of all diaphragmatic hernias (1). It was foremost designated by the Italian pathologist and anatomist Giovanni Morgagni in 1769 (2), characterized by the protrusion the abdominal viscera inside the thoracic cavity, through a defect in the anterior diaphragm, known as foramina of Morgagni (3). In adult, most cases is asymptomatic and usually discovered during a chest x-ray, but that can be complicated in 10 to 15% of cases, most often of intestinal obstruction (4). We are representing a case of Morgagni hernia revealed by a pancreatitis acute.

#### Presentation of case:-

A 60-years-old-female brutally presenting abdominal pain pancreatic type with vomiting, his medical story was without notable pathological. Her vital signs were normal, while physical examination was founded discomfort and tenderness during epigastric palpation without any other associated signs. Laboratory examinations revealed a lipasemia to 600 U/L, CRP to 110 mg/land white count a 10000/mm<sup>3</sup>. After the initial conditioning, the patient was hemodynamically stable, abdominal ultrasound as etiological check-up was normal. Abdominal computed tomography (TC) was performed, and images before the administration of contrast material showed the Morgagni

**Corresponding Author:- Ratbi El Amine**

Address:- Surgical Clinic C, University Hospital Ibn Sina, Rabat, Morocco.

hernia with the presence of abdominal viscera inside chest cavity associated to the diastasis of the 50mm diaphragmatic fibres, the hernial sac containing a part of stomach and transverse colon and none signs of obstruction (Figure 1). After 3 weeks' time needed to decrease the acute pancreatitis, the patient underwent a surgical laparoscopic, upon entering the abdominal cavity, a huge anterior diaphragmatic defect was identified, with part of the greater omentum, transversal colon, and gastric protruding through inside the right thoracic cavity. No adhesions were encountered, the hernia's sac contents and their reduction back in abdominal cavity was achieved through laparoscopy and excision of the sac was next performed with a tension free closure of the diaphragmatic defect according Raphy (Figure 2). The patient evolved favourably and was discharged on her fourth postoperative day.

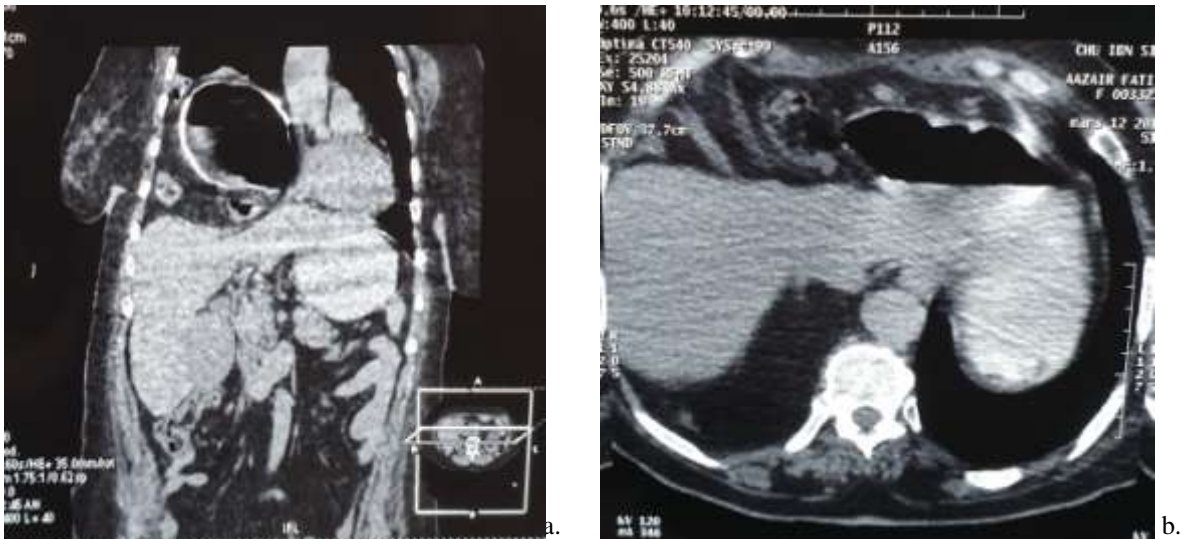
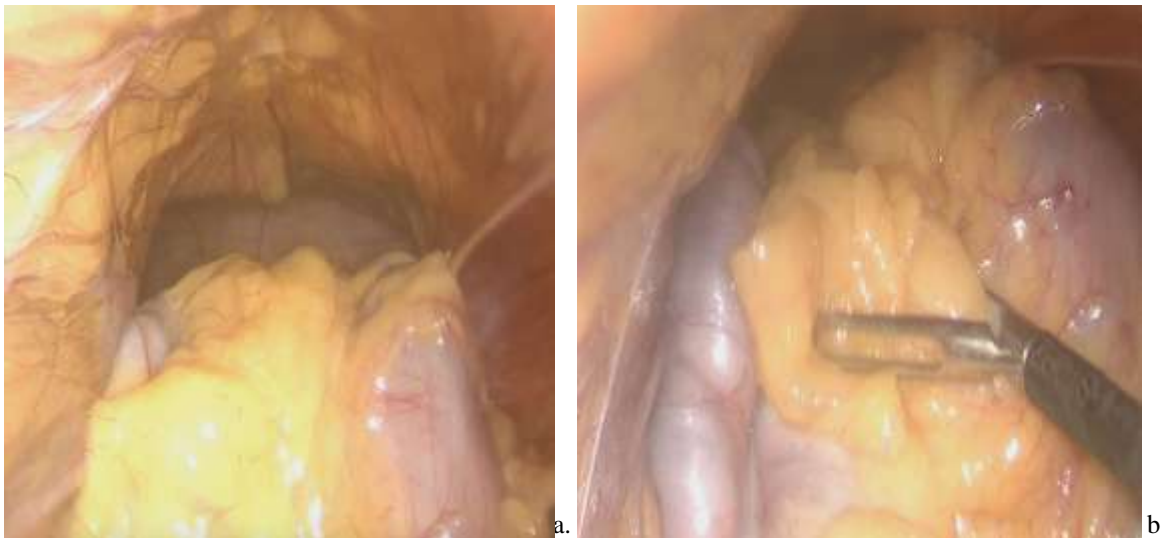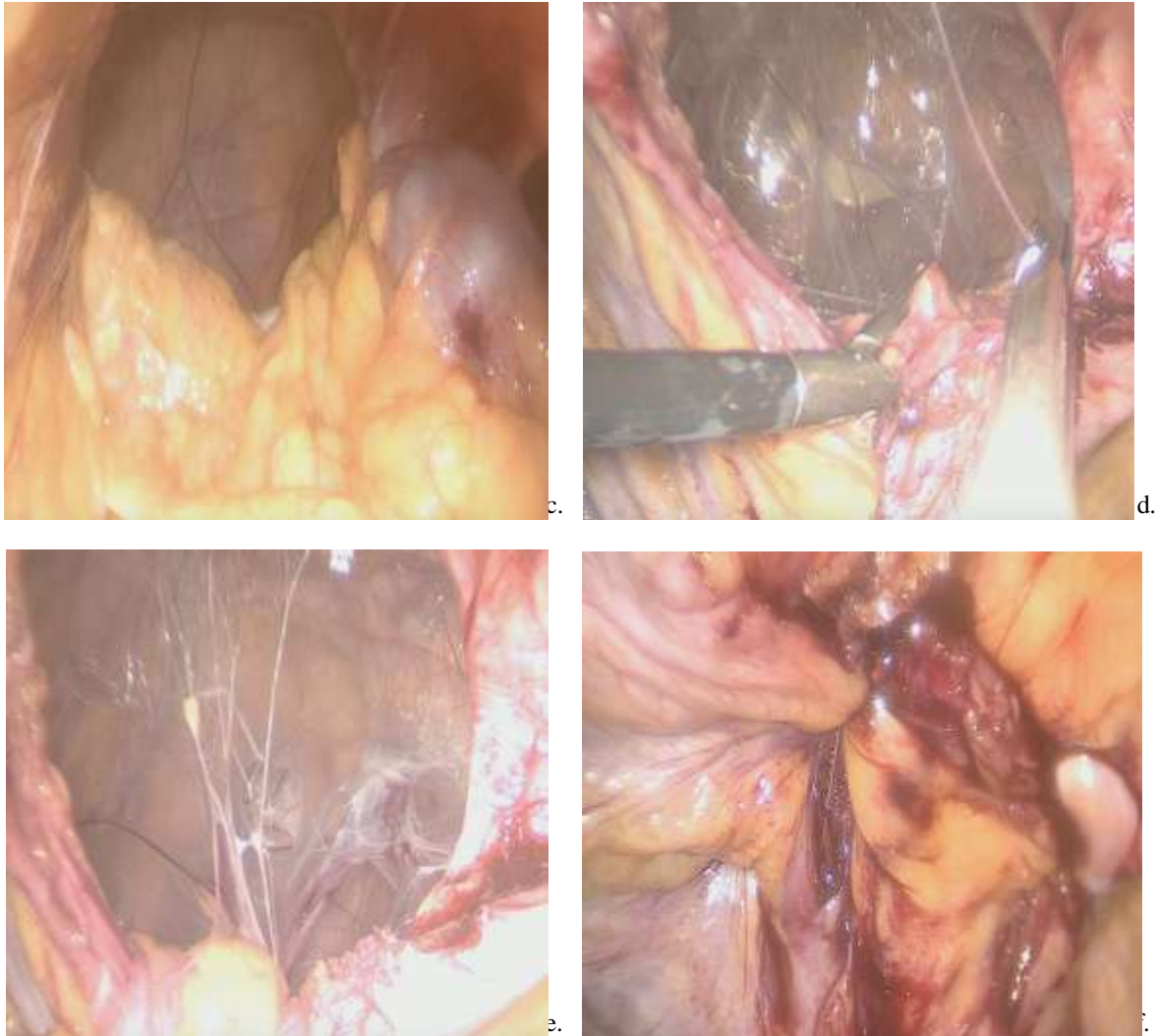


Figure 1:-

a: Sagittal CT image of chest and abdomen showing a stomach and part of bowel within the chest.

b: Axial CT image of chest and abdomen showing the hernia in the anterior part of the diaphragm containing a part of stomach, colon and omentum.





**Figure 2:-** Laparoscopic view.

a & b: Identification of the anterior diaphragmatic defect with colon, stomach portion and omentum

c: After reduction the hernia's contents in the abdominal cavity

d & e: Excision of the diaphragmatic sac

f: Tension free closure of the defect with non-absorbable sutures and mesh-free repair

### **Discussion:-**

Morgagni hernias are a rare type of congenital diaphragmatic hernia that may not be clinically apparent until adulthood. That result of weakness or defect in the diaphragmatic musculature and the difference in the pressure gradient between the abdominal and pleural cavities.

The incidence among adults with all types of diaphragmatic hernia is about 3% (5). in the pediatric age group, it occurs in about 5% of the patients, but great differences exist among series.

The most of Morgagni hernia evolves from right sternocostal trigone. Left-sided Morgagni hernia as our case, is observed in 9% of all cases (5% isolated and 4% bilateral (4). Such rare occurrence is attributed to the protective effect of the pericardial sac (6)

Almost any intra-peritoneal structure can be found in a Morgagni hernia especially omentum exclusively (34%) or colon and omentum (29%), stomach, liver and small intestine may be also seen (4).

In adult, the symptoms of MH are related to the content of hernia or the pressure exerted on the thoracic structures with common symptoms including pulmonary symptoms (dyspnea and persistent cough) and retrosternal chest pain or gastric symptoms (7). Horton et al reported that less than one third of patient (28%) have no symptoms at time of presentation and are discovered incidentally (4) as our patient. A few cases of reported MH describe patients with acute abdominal symptoms due to gastric obstruction (6).

Chest X-ray, MH may appear as homogenous masses around or overlying the cardiac silhouette, or air-fluid levels include bowel or stomach (8). CT play an important role in the diagnosis, and most often identifies the extent and content of hernia (6). Additionally, gastrointestinal contrast can be detecting Morgagni's hernia if the sac contains parts of the stomach and proximal small bowel (1). In our case the diagnosis was made by the CT.

Surgery repair prompt even on asymptomatic patients to avoid the risk of incarceration and strangulation of abdominal content in the chest once the Morgagni hernias was diagnosed (7,9). In the literature, the primary repair via laparotomy or thoracotomy has been the preferred surgical approach and has been shown to be a safe procedure and produces a durable repair (10). Currently, the laparoscopic approach become more commonplace giving a better exposure and visualization of the hernia and its contents thus allows performing out gestures intra-abdominal. Although this approach in compared as the traditional open approach give higher patient satisfaction and a shorter hospital stay (4,11).

Frequently primary closure of the defect may be effected with non-absorbable, but larger defects may require the use of mesh (11). Monsivais et al. (12) used single-incision laparoscopic port with adequate reduction of the hernia, excision of the sac, and applying mesh over the diaphragmatic defect from 2 cm incision. Furthermore, Hassan et al. (13) choose to leave the hernia sac in-situ to avoid the risk of pneumomediastinum and injury to thoracic structures. Although some authors prefer the excision of the sac especially as it decreases the rate of morbidity as the fluid collection and reduces the tissue trauma, because the sac is manipulated instead of the content (4). Monsivais et al., (12) used single-incision laparoscopic port with adequate reduction of the hernia, excision of the sac, and applying mesh over the diaphragmatic defect from 2 cm incision.

In our case, we adopted the mesh-free repair method, using non-absorbable sutures with excision of the sac,

The complication and operative mortality is rare for both laparoscopic and open surgical methods; among 50 cases there were no deaths and no known recurrences (5,14), no such complications were noticed in our case.

### **Conclusion:-**

Morgagni hernia are a rare disease that the diagnosis based a CT, the laparoscopic approach become the best technique requiring prompt surgery repair to avoid complications of incarceration.

### **References:-**

1. P.C. Minneci, K.J. Deans, P. Kim, D.J. Mathisen, Foramen of Morgagni hernia: changes in diagnosis and treatment, *Ann. Thorac. Surg.* 77 (6) (2004) 1956–1959.
2. Gedik E, Tuncer MC, Onat S, Avci A, Tacyildiz I. B: a review of Morgagni and Bochdalek hernias in adults. *Folia Morphol* 2011;70(1):5e12.
3. Horton JD, Hofmann LJ, Hetz SP. Presentation and management of Morgagni hernias in adults: a review of 298 cases. *Surg Endosc* 2008; 22:1413-20.
4. Daou R, Serhal S, Jureidini F, Demain P. Hernie rétro-costo- xyphoïdienne de l'adulte. À propos de 3 observations. *Chirurgie* 1992; 118: 59-62.
5. Comer, T. P., and Clagett, O. T. Surgical treatment of hernia of the foramen of Morgagni. *J. Thorac. Cardiovasc. Surg.* 52:461, 1966.
6. Nasr, A. Fecteau, Foramen of Morgagni hernia: presentation and treatment, *Thorac. Surg. Clin.* 19 (4) (2009) 463–468.
7. Park, C. Doyle, Laparoscopic morgagni hernia repair: how I do it, *J. Gastrointest. Surg.* 18 (10) (2014) 1858–1862.

8. Patial, Tushar, et al. "Hernia of Morgagni in the Elderly: A Case Report." *Cureus*, 2017, doi:10.7759/cureus.1549.
9. Bettini, J.G. Ulloa, H. Harris, Appendicitis within morgagni hernia and simultaneous paraesophageal hernia, *BMC Surg.* 15 (2015) 15.
10. Saltzstein HC, Linkner LM, Scheinberg SR. Subcostosternal (Morgagni) diaphragmatic hernia: report of a case of hernia containing stomach, transverse colon, and omentum, with review of the literature. *Arch Surg* 1951;63:750–65
11. G. Godazandeh, F. Mokhtari-esbuie, Laparoscopic repair of morgagni hernia: three-case presentation and the literature, *Case Rep. Surg.* (2016) 4, 2016.
12. Monsivais S, Sharp NE, Vassaur H, Buckley FP. Single-incision laparoscopic MH repair in an adult. *Int J Surg Res Pract* 2014; 1:1.
13. Hassan A, Alabdrabmeer M, Alealiwi M, Al Danan O, Alshomimi S. Incidental Morgagni hernia found during laparoscopic reparaire of hiatal hernia: Case report & review of literature, *IJSCR* (2019) [dio.org/10.1016/j.ijscr.2019.03.012](https://doi.org/10.1016/j.ijscr.2019.03.012)
14. Young MC, Saddoughi SA, Aho JM, Harmsen WS, Allen MS. Comparison of Laparoscopic Vs Open Surgical Management of Morgagni Hernia. *Ann Thorac Sur* 2019;107:257-61.