



ISSN NO. 2320-5407

Journal Homepage: [-www.journalijar.com](http://www.journalijar.com)

INTERNATIONAL JOURNAL OF ADVANCED RESEARCH (IJAR)

Article DOI:10.21474/IJAR01/11832
DOI URL: <http://dx.doi.org/10.21474/IJAR01/11832>



INTERNATIONAL JOURNAL OF
ADVANCED RESEARCH (IJAR)
ISSN 2320-5407
Journal Homepage: <http://www.journalijar.com>
Journal DOI:10.21474/IJAR01

RESEARCH ARTICLE

PREVALENCE OF ALVEOLAR EXOSTOSIS AMONG EDENTULOUS PATIENTS IN KASHMIRI POPULATION

Dr. Adil Fayaz¹, Dr. Shazia Mir² and Dr. Sandeep Kaur Bali³

1. Post-Graduate Student, Department of Prosthodontics, Govt. Dental College & Hospital, Srinagar (J&K).
2. Associate Professor, Department of Prosthodontics, Govt. Dental College & Hospital, Srinagar (J&K).
3. Professor and Head, Department of Prosthodontics, Govt. Dental College & Hospital, Srinagar (J&K).

Manuscript Info

Manuscript History

Received: 05 August 2020

Final Accepted: 10 September 2020

Published: October 2020

Key words:-

Edentulous, Prevalence, Torus
Mandibularis (TM), Torus Palatinus
(TP)

Abstract

Background: The most remarkable exostoses of the human jaws are torus palatinus (TP) and torus mandibularis (TM). The aim of the present study was to determine the prevalence of alveolar exostosis among the edentulous patients of Kashmir.

Methods: The present study included 200 edentulous subjects aged between 55 and 75 years. The subjects were examined for the existence of tori by clinical inspection and palpation. Statistical analysis was performed using SPSS for Windows version.

Results: Among the 200 subjects, 41 (20.5%) had prevalence of tori. Out of 41 patients, four subjects (9.75%) had TP and thirty-seven (18.5%) had TM. Prevalence of TP is more in female subjects than males. Out of the 41 subjects, 27 (65.85%) presented with flat tori, nine (21.95%) with spindle-shaped tori, and five (12.19%) with nodular-shaped tori. Most of the tori observed were small sized (92.68%).

Conclusion: A comparatively increased prevalence of TM was observed with flat tori being the most common type.

Copy Right, IJAR, 2020,. All rights reserved.

Introduction:-

An exostosis is a benign, localized, peripheral overgrowth of bone of unknown etiology. It may be a nodular, flat or pedunculated protuberance located on the jawbones' alveolar surface¹. They are composed of dense cortical bony structure and minimal amount of bone marrow, and are covered with a fragile and limited vascularized mucosa. Tori usually become apparent during the second or third decade of life². In the jaws, depending on the anatomic location they are named as torus palatinus (TP), torus mandibularis (TM), or buccal bone exostoses (BBE), TP that occurs along the midline of the hard palate is a sessile, nodular mass of bone. TM is a bony overgrowth located on the lingual aspect of the mandible, most commonly seen in the canine and premolar areas. BBE occurs along the buccal aspect of the maxilla or mandible, usually in the premolar and molar areas. Palatal exostoses are found on the palatal aspect of the maxilla, and the most common location is the tuberosity area. Multiple exostoses occasionally occur in the same individual. They may appear as isolated, discrete bony overgrowths on the facial aspect of alveolar bone in young, dentate subjects or as somewhat less usually found multiple exostosis in maxilla (torus palatinus) and in mandible (mandibular tori)³. Reichart et al have classified TP, based on their size, as small (less than 3 mm), medium (3–6 mm), and large (more than 6 mm) tori⁴. Removal of these exostoses may be difficult when compounded by lack of access, restricted opening by the patient, or the relative immobility of palatal tissue.

Corresponding Author:- Dr. Adil Fayaz

Address:- Post-Graduate Student, Department of Prosthodontics, Govt. Dental College & Hospital, Srinagar (J&K).

Buccal exostoses are significant with regards to prosthodontics because they may interfere with denture insertion. Also, buccalexostoses may be traumatized and interfere with oral hygiene procedures³. Other exostoses such as mandibular and palatal tori may require surgical removal for prosthetic reasons.

The presence of alveolar exostosis have multifactorial etiology, which includes mainly genetics and environmental factors⁵. Many predisposing factors such as trauma, drugs, discontinued growth, infection, masticatory stress, and environmental and nutritional factors have been identified by various researchers^{6,7}.

This study has been carried out to estimate the prevalence of alveolar exostosis among the edentulous subjects of Kashmiri population which may interfere with the denture insertion.

Methods:-

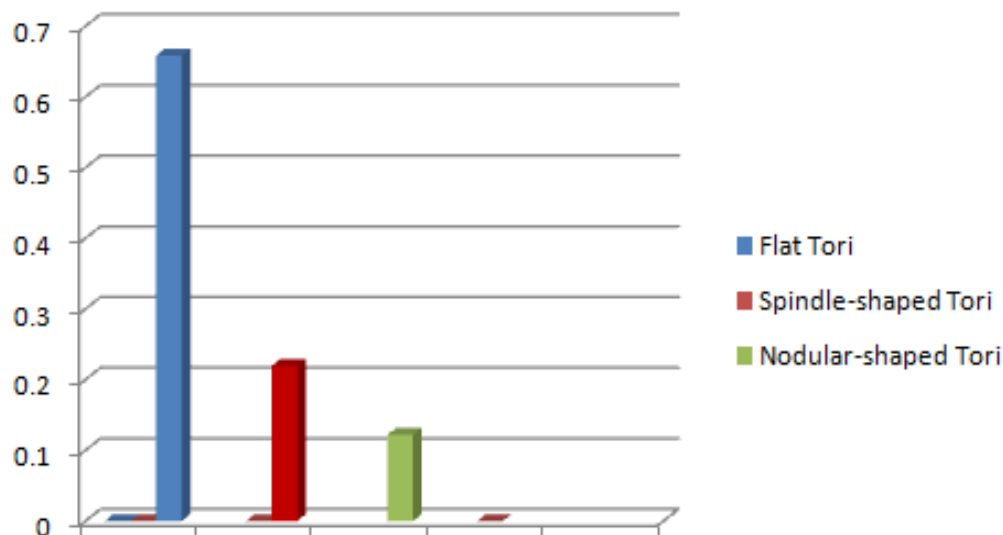
The present study comprised 200 edentulous subjects aged between 55 and 75 years. The present study was carried out at the department of Prosthodontics, Crown and Bridges, Government Dental College and Hospital, Srinagar.

Subjects were categorized based on the size of the exostosis as described by Reichart as small (<3mm), medium (3-6mm) and large (>6mm). The existence of exostosis was determined by clinical examination and palpation.

The data were collected, and statistical analysis was performed using SPSS version 20.0. The statistical analysis was performed using chi-square (χ^2) test and P-value at 5% level was considered to be statistically significant.

Results:-

The study revealed that out of a total of 200 subjects, 41 (20.5%) had prevalence of tori. Out of 41 patients, four subjects (9.75%) had TP and thirty-seven (18.5%) had TM. Prevalence of TP is more in female subjects than males. Out of the 41 subjects, 27 (65.85%) presented with flat tori, nine (21.95%) with spindle-shaped tori, and five (12.19%) with nodular-shaped tori. Most of the tori observed were small sized (92.68%).



Discussion:-

The benign innocuous nature of tori in majority of cases does not necessitate any surgical intervention unless in the event of tissue trauma, periodontal or prosthodontic complications. Further while attempting to capture accurate detail for final impressions of crown and bridge, removable prosthetics, oral appliances, accurate opposing models, study models, and whitening trays, stock impression trays often cannot be seated to the depth, because of the interference by these bony anatomical variants. These bony protuberances may cause pain during the impression making, as there is often only a thin oral mucous membrane covering these osseous protuberances which is easily irritated⁸.

It has been reported that TP occurs more frequently than TM. In contrast to this, the results of the present study showed higher prevalence of TM (18.5%) in comparison to TP (9.75%). This finding is similar to that of Sirirungrojying and Kerdpon and Bruce et al who noticed a higher prevalence of TM than that of TP^{9,10}.

The present study revealed that TP is more prevalent in females in comparison to males, and this was attributed to a dominant type, X chromosome¹¹. Some authors have also found no significant differences in the prevalence of TM between males and females¹². The results of the current research showed that the sex-based factor has minimal impact on the prevalence of tori.

The flat-shaped tori (65.85%) were reported to be more commonly seen in the present study. This finding is in line with other similar studies mentioned in the literature^{7,13,14}. However, Simunković et al, Jainkittivong et al, and Reichart et al showed a higher prevalence of spindle-shaped tori^{4,15,16}. Haugen found that nodular TP was core common⁶.

It is possible for ulcers to form on the area of the tori due to repeated trauma. However, the existence of tori may be beneficial as they may be used for harvesting bone in augmenting the ridge and the potential use of the mandibular and palatal tori as sources of autogenous cortical bone for grafting.

Conclusion:-

The results of the present study show that the prevalence of tori in the Kashmiri population is low and the incidence of tori is higher in females when compared to males, which is however not significant. There is also higher prevalence of small sized flat-shaped tori, although not significant. Further long-term prospective studies are encouraged for future assessment of the prevalence of TP and TM.

References:-

1. Stafne EC, Gibilisco JA. Oral roentgenographic diagnosis. 4th ed. Philadelphia: WB Saunders Company; 1975, p. 89–91.
2. Al-Sebaie D, Alwrikat M. Prevalence of torus palatinus and torus mandibularis in Jordanian population. Pak Oral Dent J. 2011;31:214–216.
3. Sonnier KE, Horning GM, Cohen ME. Palatal tubercles, palatal tori, and mandibular tori: prevalence and anatomical features in a U.S population. J Periodontol 1999;70:329–36.
4. Reichart PA, Neuhaus F, Sookasem M. Prevalence of torus palatinus and torus mandibularis in Germans and Thais. Commun Dent Oral Epidemiol. 1988;16:61–64.
5. Simunković SK, Bozić M, Alajbeg IZ, Dulčić N, Boras VV. Prevalence of torus palatinus and torus mandibularis in the Split-Dalmatian County, Croatia. CollAntropol. 2011;35:637–641.
6. Haugen LK. Palatine and mandibular tori. A morphologic study in the current Norwegian population. Acta Odontol Scand. 1992;50:65–77.
7. Patil S, Maheshwari S, Khandelwal SK. Prevalence of torus palatinus and torus mandibularis in an Indian population. Saudi J Oral Sci. 2014;1:94–97.
8. Al Quran FAM, Al-Dwairi ZN. Torus palatinus and torus mandibularis in edentulous patients. J Contemp Dent Pract 2006; 7(2):1–6.
9. Bruce I, Ndanu TA, Addo ME. Epidemiological aspects of oral tori in a Ghanaian community. Int Dent J. 2004;54:78–82.
10. Sirirungrojying S, Kerdpon D. Relationship between oral tori and temporomandibular disorders. Int Dent J. 1999;49:101–104.
11. García-García AS, Martínez-González JM, Gómez-Font R, Soto-Rivadeneira A, Oviedo-Roldán L. Current status of the torus palatinus and torus mandibularis. Med Oral Patol Oral Cir Bucal. 2010;15:e353–e360.
12. Martínez-González JM. Benign tumors of the maxilla. In: Donado M, editor. Cirugía Bucal. Patología y Técnica. 2nd edn. Barcelona: Masson; 1998:627–639.
13. Al-Bayaty HF, Murti PR, Matthews R, Gupta PC. An epidemiological study of tori among 667 dental outpatients in Trinidad and Tobago, West Indies. Int Dent J. 2001;51:300–304.
14. King DR, King AR. Incidence of tori in 3 population groups. J Oral Med. 1981;36:21–23.
15. Simunković SK, Bozić M, Alajbeg IZ, Dulčić N, Boras VV. Prevalence of torus palatinus and torus mandibularis in the Split-Dalmatian County, Croatia. CollAntropol. 2011;35:637–641.
16. Jainkittivong A, Apinhasmit W, Swasdison S. Prevalence and clinical characteristics of oral tori in 1,520 Chulalongkorn University Dental School patients. Surg Radiol Anat. 2007;29:125–131.