



ISSN NO. 2320-5407

Journal homepage: <http://www.journalijar.com>

INTERNATIONAL JOURNAL
OF ADVANCED RESEARCH

RESEARCH ARTICLE

Short-term results of primary total hip arthroplasty for Protrusio Acetabuli

Abdel Rahman H. Khalifa, Ashraf R. Marzouk, Mohamed Alam-Eldin, Ahmad addosooki

Department of Orthopedic Surgery, Faculty of Medicine, Sohag University.

Manuscript Info

Manuscript History:

Received: 12 February 2014
Final Accepted: 22 March 2014
Published Online: April 2014

Key words:

Protrusio Acetabuli, Total hip arthroplasty, impacted morsellised autograft, outcome.

*Corresponding Author

Abdel Rahman Hafez

Abstract

BACKGROUND AND PURPOSE:

Protrusio is a central acetabular defect resulting from migration of the femoral head medial to Kohler's line. Protrusio can develop in association with a number of conditions that affect the metabolism or mechanical behavior of the periacetabular bone. Total hip arthroplasty (THA) for acetabular protrusio requires reconstruction of the contained cavitory defect. The purpose of this study is to assess the outcome of primary total hip replacement in this category of patients using impacted autograft with either cemented or cementless cups.

METHODS:

Our Prospective study was carried out during the period from January 2010 to January 2013. We reported 8 hips in 6 patients (4 males and 2 female) with age ranged from 54 to 73 years (mean age 64 years) and presented to our department with protrusio acetabuli (5 patients had primary protrusio acetabuli and 1 patient had secondary protrusio acetabuli). Using the Sotelo-Garza and Charnley classification of protrusio acetabulal, two hips had grade I (mild) protrusio ,three had grade II (moderate) and three had grade III protrusion (severe). In 5 cases a cementless prosthesis was used and cemented prosthesis were used in 3 cases. In one case a bursh-schneider cage of the acetabulum was added. Radiographic and clinical follow-up was performed up to 4 years postoperatively (mean follow-up 16 months, range 12-49 months).

RESULTS:

At radiographic follow-up, no signs of prosthetic loosening or migration were seen. Harris Hip Score improved from 25.8 (SD 7.3, range 11-34) preoperatively to 88.3 (SD 9.7, range 71-98) at latest follow-up.

CONCLUSION:

primary total hip replacement using impacted autograft in patients with protrusio acetabuli led to a good result in a series of eight cases at short term follow-up.

Copy Right, IJAR, 2014., All rights reserved.

Introduction

Protrusio is a central acetabular defect resulting from migration of the femoral head medial to Kohler's line. Protrusio can develop in association with a number of conditions that affect the metabolism or mechanical behavior of the periacetabular bone. Total hip arthroplasty (THA) either cementless or cemented for acetabular protrusio requires reconstruction of the contained cavitory defect. The acetabular rim is generally intact.¹ The defect can be effectively treated with a lateralized cementless porous-coated component supported on the peripheral acetabular bony rim. Morsellized autograft is used to fill the medial defect. However, if the rim is inadequate to provide

mechanical support for a cementless cup due to bone loss or osteoporosis, cementless cup reconstruction can result in medial migration. If rim support is inadequate, a reconstruction cage is a more appropriate option to gain fixation to the pelvis above and below the acetabulum.^{2,3} Total hip arthroplasty for protrusio can also affect both offset and leg length, so careful preoperative templating is important to help determine implant position. Results of THA with medial acetabular bone grafting for protrusio acetabuli have been favorable, with success rates similar to conventional THA.⁴

PATIENTS AND METHODS:

This study was carried out during the period from January 2010 to January 2013. Eight hips of 6 patients (4 males and 2 females) with protrusio acetabuli were treated by primary total hip replacement. The youngest patient was aged 54 years and the oldest was aged 73 years (mean age 64 years). They were available to follow-up and were re-examined clinically and radiologically during the period from January 2010 to December 2013. An informed written consent was taken from all patients and ethical approval was taken from the local ethical committee. Exclusion criteria were : cancer, current infections , joint arthroplasty in the past 4 months or revision surgery. No patient was excluded because of his age or for his BMI. Five patients were primary protrusio acetabuli and 1 patient was secondary protrusio acetabuli. Using the Sotelo-Garza and Charnley classification of protrusio acetabuli, two hips had grade I (mild) protrusio , three had grade II (moderate) and three had grade III protrusion (severe).⁵ In 5 cases a cementless prosthesis (Fig 1) was used and in 3 cases cemented prosthesis (Fig 2) were used. In one case a bursh-schneider cage of the acetabulum was added. Radiographic and clinical follow-up was performed up to 4 years postoperatively (mean follow-up 16 months, range 12-49 months).The clinical assessment of pain, range of movement and hip function was made using Harris Hip Score.⁶ Radiographs were evaluated for the degree of pre- and post-operative protrusion and graft incorporation. The degree of protrusio was measured using the method described by Ranawat⁷ We also looked for radiolucent lines between the graft and the acetabular wall. Data obtained from the patients' record. An Excel sheet filled with records values.(Harris Hip Score)⁶ and a visual analogue scale to assess the patients, subjective complaints and outcomes. The aim was to obtain a comprehensive medical history, a nearly complete data collection and access to the preoperative and postoperative values of the Harris Hip Score⁶.

OPERATIVE TECHNIQUE:

The direct lateral approach was used in 7 hips and posterolateral approach was used in 1 patient.The hip dislocation may be difficult and sometimes necessitates an in situ femoral neck osteotomy. The hip center should be restored to within 10 mm of its anatomical location for improved cup survivorship.⁸ Medialization should be avoided and reaming limited primarily to the periphery of the acetabulum. Peripheral rim support should be maintained when a cementless acetabular cup is used. The cavitory defect behind the cup should be augmented with particulate cancellous bone graft and impaction grafting techniques. Excessive limb-lengthening may be avoided by doing a low femoral neck resection and using components with increased medial offset⁹.

Cementless Acetabular Cup Reconstruction

Stability of press-fit acetabular components relies on the mechanical support of the peripheral acetabular bony rim. To support a lateralized cementless cup in protrusio deformity, the peripheral acetabular rim is reamed with a slightly oversized reamer . Screw fixation is also required. However, the peripheral rim provides primary mechanical support of the cup to prevent medial migration into the acetabular defect. Morsellized bone from the acetabular reamings or femoral head can be used to fill the medial defect. Morsellized bone graft generally heals well, but does not provide mechanical support since the cup is primarily supported by the peripheral bony rim.⁹

In post-traumatic deformity, the inferior pelvis is typically displaced medially. To position the cup to its anatomic location, it should be placed laterally to restore the prefracture lateral offset of the acetabulum. The relative position of the floor of the acetabulum can be determined by the location of the teardrop . However, if the inferior pelvis is displaced medially, the floor of the acetabulum will be relatively medial to its prefracture location. For this reason, the acetabular component should be placed in its prefracture anatomic position.

Cage Reconstruction

If the peripheral bony rim is deficient or osteoporotic, cementless cup reconstruction can be associated with medial and superior implant migration so reconstructive cage may be more appropriate for treatment of protrusio deformity in association with osteoporosis .⁹

Effect on Leg Length and Offset

Lateralization of the acetabular component may create an undesirable increase in offset. Protrusio deformity, particularly in rheumatoid arthritis, can also be associated with a varus proximal femoral deformity. This requires a low femoral neck cut to avoid an increase in leg length after THA. Preoperative templating in protrusio deformity is important to determine the effect of acetabular component lateralization and femoral component placement on leg length and offset.

Post-operative management

Our routine protocol after primary THR includes progression of quad sets and calf raises, each twice a day, up to 20 lifts each time. We recommend walking as far as possible everyday with the physical therapist and with an assistive device (walker), stationary bicycling with no resistance for 15 to 20 minutes each day. After THA through a posterolateral approach, hip precautions usually are continued for 6 weeks after surgery.

RESULTS:

Our clinical and radiological outcome of using impacted autograft in 8 primary THRs with mild (n = 2), moderate (n = 3) and severe (n = 3) grades of acetabular protrusion are satisfactory. The mean Harris hip score had improved from 25.8 (SD 7.3, range 11-34) preoperatively to 88.3 (SD 9.7, range 71-98) at latest follow-up.

At final follow-up, 5 hips (62.5%) had a good or excellent result, two (25%) had a fair result and one (12.5%) had a poor result. All bone grafts had united by the sixth post-operative month and none of the hips showed any radiological evidence of recurrence of protrusio, osteolysis or loosening. By using impacted morsellised autograft and either cementless or cemented acetabular components it was possible to achieve restoration of hip mechanics, provide a biological solution to bone deficiency and ensure long-term fixation without recurrence in arthritic hips with protrusio undergoing THR.

The average operation time was 146 min (range 135-195 min.). The postoperative clinical assessment was satisfactory with an improvement in The mean Harris hipscore from 25.8 (SD 7.3, range 11-34) preoperatively to 88.3 (SD 9.7, range 71-98) One patient had a transient femoral nerve palsy; ame stable after reduction significant postoperative complications.

Radiological examination revealed that the centre of rotation of the hips was improved to within 4 mm of normal. There were no cases of failure of the bone graft , with no radiolucent lines around the socket and satisfactory union of the graft.

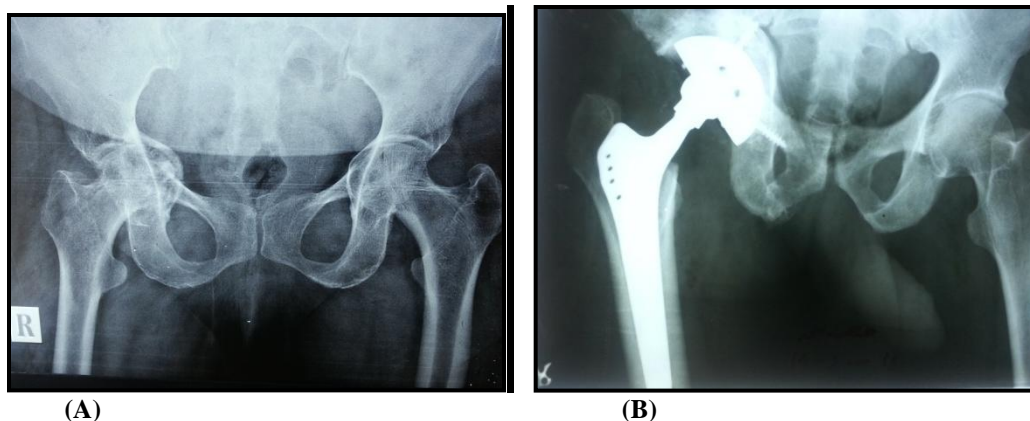


Figure 1: Plain x-ray of right hip of Sixty five years old lady with right protrusion acetabulum (A), after cementless total hip replacement (B).

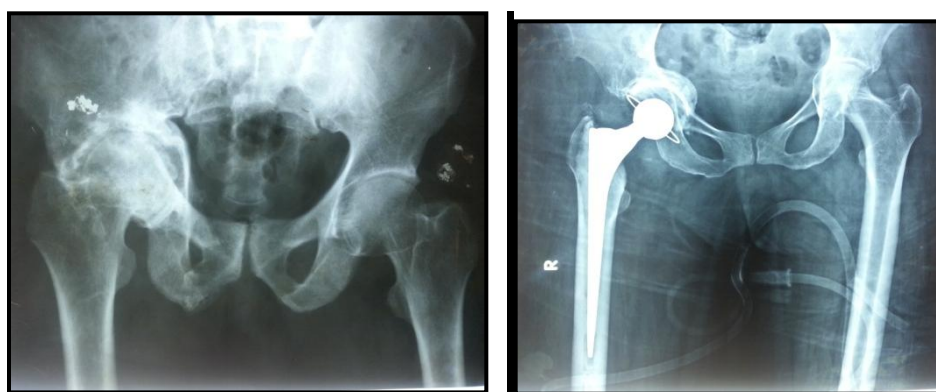


Figure 1: Plain x-ray of right hip of seventy years old lady with right protrusion acetabulum (A), after cemented total hip replacement (B).

DISCUSSION

There are few reports describing the technique of managing acetabular protrusion in primary total hip replacement. Most are small series with different methods of addressing the challenges of significant medial and proximal migration of the joint centre, deficient medial bone and reduced peripheral bony support to the acetabular component.¹⁰⁻¹²

When performing THA for patients with protrusion acetabula the bone stresses on the medial wall of the acetabulum are increased if the socket is placed medially. Several surgical techniques have been described to treat acetabular deficiency associated with protrusion.^{1,13,14}

Garza and Charnley reported the use of cement to fill bone defects, and they reported similar results when using cement as when using bone graft, and concluded that there was no indication for the use of a reinforcement ring even in severe cases. However, there were other reports of unsatisfactory results when cement alone was used. Harris et al. reported poor results with cement fixation augmented by mesh, although this technique was satisfactory in patients with mild protrusion¹⁴. Several authors have recommended the use of medial graft; and use of this technique enables the socket to be placed in a more anatomical position, thereby preventing further progression of the protrusion. The technique may be augmented by the use of a support ring, or cement. Some studies have reported

the failure of a cementless socket without a support ring . Rawanat et al. reported that where the degree of protrusion is more than 5 mm and the medial wall is intact, only graft is required; however, when the medial wall is grossly deficient, additional fixation is required to restore the centre of rotation of the hip joint. Harris et al. reported that an uncemented socket without graft is sufficient [16]; and we have previously reported satisfactory results with an uncemented socket alone in mild protrusio [26] and we only used the MC support ring in patients with severe protrusio. The operation is a larger surgical undertaking than a routine procedure, with a longer operating time and an increased peri-operative blood loss; but good medium term results are obtained.

CONCLUSION

primary total hip replacement using impacted autograft in patients with protrusio acetabuli led to a good result in a series of eight cases at short term follow-up

REFERENCES

- .1 Mullaji AB, Shetty GM. Acetabular protrusio: surgical technique of dealing with a problem in depth. *The bone & joint journal*. Nov 2013;95-B(11 Suppl A):37-40.
- .2 Boisgard S, Descamps S, Bouillet B. Complex primary total hip arthroplasty. *Orthopaedics & traumatology, surgery & research : OTSR*. Feb 2013;99(1 Suppl):S34-42.
- .3 Dutka J, Sosin P, Skowronek P, Skowronek M. Total hip arthroplasty with bone grafts for protrusio acetabuli. *Ortopedia, traumatologia, rehabilitacja*. Sep-Oct 2011;13(5):469-477.
- .4 Mullaji AB, Marawar SV. Primary total hip arthroplasty in protrusio acetabuli using impacted morsellized bone grafting and cementless cups: a medium-term radiographic review. *The Journal of arthroplasty*. Dec 2007;22(8):1143-1149.
- .5 Sotelo-Garza A, Charnley J. The results of Charnley arthroplasty of hip performed for protrusio acetabuli. *Clinical orthopaedics and related research*. May 1978(132):12-18.
- .6 Harris WH. Traumatic arthritis of the hip after dislocation and acetabular fractures: treatment by mold arthroplasty. An end-result study using a new method of result evaluation. *The Journal of bone and joint surgery. American volume*. Jun 1969;51(4):737-755.
- .7 Ranawat CS, Dorr LD, Inglis AE. Total hip arthroplasty in protrusio acetabuli of rheumatoid arthritis. *The Journal of bone and joint surgery. American volume*. Oct 1980;62(7):1059-1065.
- .8 Baghdadi YM, Larson AN, Sierra RJ. Restoration of the hip center during THA performed for protrusio acetabuli is associated with better implant survival. *Clinical orthopaedics and related research*. Oct 2013;471(10):3251-3259.
- .9 Sathappan SS, Strauss EJ, Ginat D, Upasani V, Di Cesare PE. Surgical challenges in complex primary total hip arthroplasty. *Am J Orthop (Belle Mead NJ)*. Oct 2007;36(10):534-541.
- .10 Matsuno H, Yasuda T, Yudoh K, et al. Cementless cup supporter for protrusio acetabuli in patients with rheumatoid arthritis. *International orthopaedics*. 2000;24(1):15-18.
- .11 Ecker ML. CORR Insights(R): restoration of the hip center during THA performed for protrusio acetabuli is associated with better implant survival. *Clinical orthopaedics and related research*. Oct 2013;471(10):3260-3261.
- .12 Li H, Wei W, Lin JH, Kou BL, Lu HS. [Medium and long-term clinical results of using Zweymuller cup to treat protrusio acetabuli]. *Zhonghua wai ke za zhi [Chinese journal of surgery]*. Sep 1 2011;49(9):804-807.
- .13 Blumenfeld TJ, Bargar WL. Surgical technique: a cup-in-cup technique to restore offset in severe protrusio acetabular defects. *Clinical orthopaedics and related research*. Feb 2012;470(2):435-441.
- .14 Oh I, Harris WH. Design concepts, indications, and surgical technique for use of the protrusio shell. *Clinical orthopaedics and related research*. Jan-Feb 1982(162):175-184.