



Journal Homepage: - [www.journalijar.com](http://www.journalijar.com)

## INTERNATIONAL JOURNAL OF ADVANCED RESEARCH (IJAR)

Article DOI: 10.21474/IJAR01/16382

DOI URL: <http://dx.doi.org/10.21474/IJAR01/16382>



### RESEARCH ARTICLE

#### MANAGEMENT OF DENTAL FLUOROSIS BASED ON SEVERITY INDEX

Kumari Deepika, Kriti Bansal, Rekha Gupta and Shubhra Gill

#### Manuscript Info

##### Manuscript History

Received: 05 January 2023

Final Accepted: 09 February 2023

Published: March 2023

##### Key words:-

Dental Fluorosis, Microabrasion,  
Veneers

#### Abstract

**Aim and Objective:** The purpose of present case series is to illustrate treatment procedure of discoloration due to dental fluorosis based on severity index.

**Background:** Dental fluorosis is the appearance of faint white lines or streaks on the teeth that occurs when younger children consume too much fluoride, from any source, over long periods when teeth are under developing stage. It affects the esthetic and also the confidence of the affected person. The esthetic improvement can have great effect on patient confidence and oral health and may be sought for various reasons like discoloration, shape and size of teeth. Tooth whitening is a major concern among general young population to approach dental surgeon. Various treatment options given in the literature to treat dental fluorosis include bleaching, microabrasion, composite restoration and porcelain veneers.

**Case description:** In this case series, mild to moderate fluorosis was treated by use of minimal invasive procedure of microabrasion and ceramic veneers were used to treat moderate to severe fluorosis.

**Conclusion:** Among different treatment modalities present, the selection of appropriate treatment improves the prognosis of treatment.

**Clinical significance:** The treatment approach in dental fluorosis varies based on its severity therefore, it is essential to analyze the fluorosis index before treating the patient with a complaint of tooth discoloration to achieve best prognosis.

Copy Right, IJAR, 2023.. All rights reserved.

#### Introduction:-

Discoloration of anterior teeth is one of the reasons of low self esteem among teenage and adult population. There may be various reasons for discoloration depending upon source extrinsic or intrinsic. Extrinsic stain may be acquired due to plaque, chromological bacteria, medication like iron tablet and dietary origin and possible reason for intrinsic stain include amelogenesis imperfecta, dental fluorosis, tetracycline stain and systemic disease.<sup>1</sup> Severity of discoloration depends upon etiology and stage of tooth development at which it occurred. Dental fluorosis is hypo-mineralisation of enamel due to excess intake of fluoride during tooth development.<sup>2</sup> Severity of discoloration may range from localized defect on a small aspect of one tooth to the generalized discoloration of several teeth. There are various treatment options available to treat dental fluorosis which involves minimal invasive approach like bleaching, microabrasion, composite resin, and indirect restoration like laminate and veneers and crowns.<sup>3</sup>

Bleaching is a noninvasive procedure which involves use of chemical like hydrogen peroxide or carbamide peroxide. Macroabrasion involves use of fine diamond or carbide finishing bur to remove roughness and

discoloration of hypo-mineralized layer of outer enamel. Procedure of microabrasion involves use of 18% sodium-hypochlorite and abrasive mixture to remove hypo-mineralized enamel surface and remove roughness of outer enamel layer. Indirect restorations are the best suited treatment modalities for generalized pitted brown and yellow stain which do not provide appreciable result with minimal invasive procedure.<sup>4,5</sup> Therefore, in this case series, mild to moderate dental fluorosis was treated with microabrasion technique using commercially available microabrasion kit Opalustre (Ultradent Products, Inc), chemical and mechanical abrasion slurry containing 6.6% HCl and silicon carbide microparticles in water-soluble paste. The severe form was treated using ceramic veneers. For treating mild cases of fluorosis, bleaching and microabrasion have been recommended; however, in moderate to severe cases, bleaching and microabrasion are either ineffective or may lead to only temporary improvement, while composite restorations are prone to discoloration and chipping or debonding. Ceramic veneers are the restoration of choice for moderate to severe cases of fluorosis given their color stability, wear resistance, and biocompatibility.<sup>6</sup>

## Case Series

### Case 1

A 21-year-old male patient reported in our department of Prosthodontics with chief complaint of discoloured upper front teeth. There was no significant associated sign and symptoms, and the past medical history was not significant. On clinical examination, all teeth in maxillary and mandibular arch presented with intrinsic brown stains on the facial surfaces. Dental fluorosis was diagnosed as an etiological factor. According to Dean's fluorosis index, it was categorized as mild to moderately severe grade of fluorosis as shown in Figure 1A. Various treatment options explained to the patient and patient had decided to go for microabrasion procedure for the treatment of fluorosis. In maxillary arch, 11 and 21 were endodontically treated and more discolored that were restored first before proceeding to microabrasion procedure. 11 and 21 were prepared for Zirconia crown using putty index, made to guide adequate reduction and double retraction cord technique was used for impression making using polyvinyl siloxane and provisional crowns were given using self-cured bisacrylate composite (3M ESPE™Protemp) shown in Figure 1 B,C,D. After that microabrasion procedure was started using Opalustre kit and GC tooth mousse (Figure 2A,B). Rubber dam with interproximal wedjets were applied for isolation of teeth and gingival barrier (Opal dam green resin barrier) was applied to protect soft tissues from strong acid (Figure 3A,B). During the microabrasion treatment, the patient's, clinician's and assistant's eyes were protected with protective glasses. Initially, slight trimming with the fine diamond bur was done on the affected area in order to reduce the time needed for the microabrasion as well as the amount of microabrasive material used. After that 1-2 mm thick layer of microabrasion paste Opalustre (6.6% HCl and Silicon carbide microparticles) was applied on the affected teeth (maxillary front 10 teeth, second premolar to second premolar) (Figure 3A,B). A rubber cuff was attached to contra angled handpiece and tooth surface was microabraded with slight pressure for 60-120 seconds (Figure 3C). Small drop of water was added to moisten the surface whenever required. Several applications may be necessary depending upon severity of the fluorosis. Here in this case, Opalustre was applied 2 to 3 times in a single session, abundant rinsing with water was done after each application for an optical evaluation, before proceeding to the next application. There was some reduction in the staining after the end of one session and the esthetic improvement was visualized on the wet surface. After polishing the region with Mousse tooth paste (Fluoride paste) at slow speed, a neutral 2% sodium fluoride varnish (Fluoroprotector) was applied for one minute and isolated for 4 minute in order to enhance remineralization. The patient was instructed not to rinse for one hour. Same procedure was repeated once again after 1 week. After completion of fluorosis treatment, final Zirconia crown with layered porcelain were cemented in 11 and 21 for best esthetic result (Figure 3D). For above case, the microabrasion treatment followed by subsequent remineralization gave good and satisfactory results. At the maintenance appointments, after one and three months, it was observed that the shiny aspect and the surface smoothness were maintained and that there was no post-operative sensitivity on teeth that had been treated with microabrasion.

### Case 2

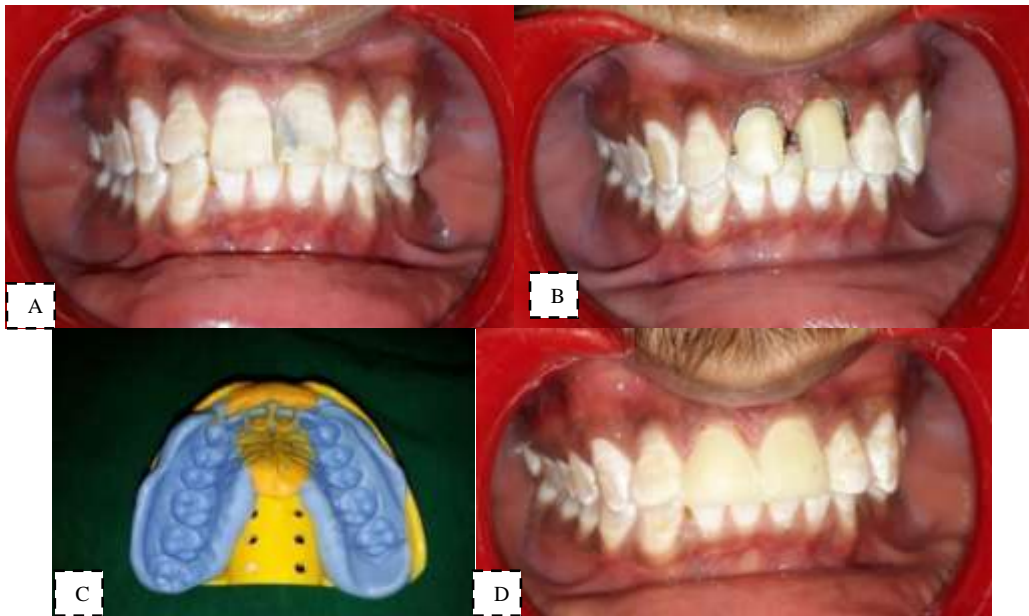
A 22-year-old female patient reported in our department with chief complaint of brown-yellowish discoloration in upper front teeth. On clinical examination, moderate to severely grade fluorosis was observed according to Dean's fluorosis index (Figure 4A). For more stable and effective result, ceramic veneers were planned as treatment modality for this case. The procedure was explained to the patient and an informed consent was taken. Only maxillary right and left central and lateral incisors were prepared for veneers that were visible on smile (Figure 4B). After that impression was made for fabrication of veneers followed by temporization. After try-in of ceramic veneer for marginal fit and esthetics, final prosthesis was bonded using resin cement. Patient was satisfied with the final esthetic outcome (Figure 5A,B). No sensitivity or no any other problem was reported in 6 months follow-up.

### Discussion:-

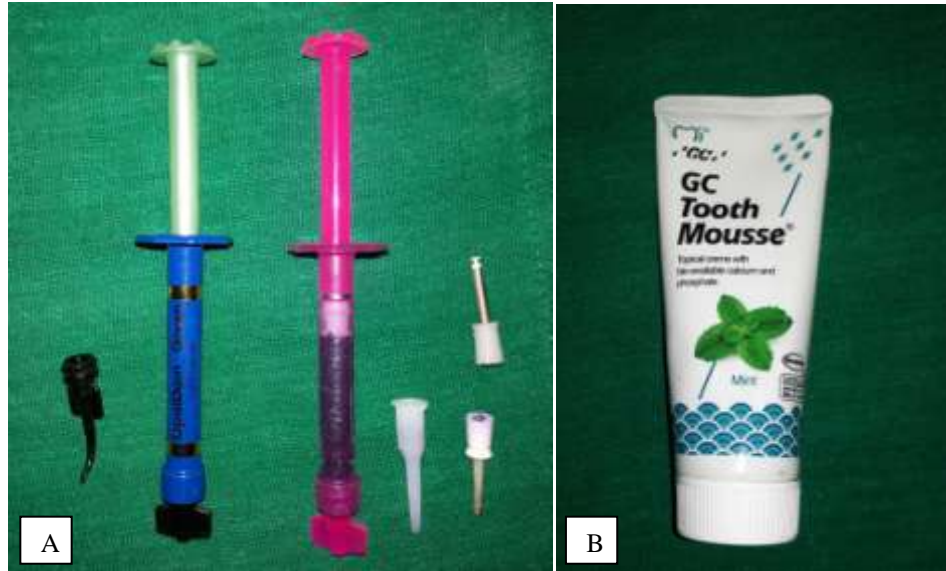The cause of discoloration should find out first to outline treatment plan. The treatment approach in dental fluorosis varies based on its severity therefore, it is essential to analyze the fluorosis index before treating the patient with a complaint of tooth discoloration to determine the most effective approach.<sup>7</sup> Dental fluorosis is one of the major causes of tooth discoloration in country like India where fluorosis is endemic. In India, fluorosis is more prevalent in state like Andhra Pradesh, Punjab, Haryana and Uttar Pradesh due to presence of excess fluoride in water.<sup>8</sup> Therefore, our initial focus should be on the prevention of dental fluorosis. Among various treatment modalities to treat discoloration, bleaching is very popular among public and dental surgeons that involve primarily hydrogen peroxide or one of its precursors, notably carbamide peroxide. Bleaching agents can be applied externally to the teeth also known as vital bleaching, or internally within the pulp chamber known as non-vital bleaching.<sup>9</sup> Both techniques aim to bleach the chromogens within the dentine, thereby changing the body color of the teeth. Local side effects of bleaching include tooth sensitivity, effect on restorative material, mucosal irritation, effect on dental hard tissue.<sup>4</sup> However, yellow brown stains of dental fluorosis show very often little effect of bleaching in comparison to microabrasion or macroabrasion depending upon severity of discoloration and roughness cause by dental fluorosis.<sup>10</sup> Enamel microabrasion is a minimal abrasive technique that involves only superficial enamel to improve discoloration. This technique leads to loss of outer layer of enamel of around 25- 200  $\mu\text{m}$  depending on the number of applications and acids concentration.<sup>11</sup>

In the above case 1, microabrasion was procedure of choice. After using the proper technique protocol, the tooth colouration was improved and a shiny surface was appeared because during the procedure, the demineralised layer was completely removed. The rotary procedure allows the material to simultaneously abrade and erode the enamel surface, so removes the stain mechanochemically.<sup>12</sup> In case 2, ceramic veneers were provided to treat fluorosis as patient was more concerned with the esthetic result. It was planned here as microabrasion may not be much effective due to the severity index of fluorosis. Here, in both cases, none of the patients reported sensitivity in their teeth at any point of time and were satisfied with the treatment outcome. The durability and clinical success of ceramic veneers have been widely investigated in the literature. It has been reported that ceramic veneers provide durable and successful restoration with an estimated survival probability of 93.5% over 10 years.<sup>13-15</sup> In a case study done by Budhwar et al., zirconia crown was given to the patient with moderate fluorosis as it offers a good esthetic result with minimum tooth preparation. Besides that it offers good strength, durability and long lasting effect. Currently, quantitative light-induced fluorescence has been introduced which able to quantify the enamel loss and helps in the diagnosis of dental fluorosis.<sup>16</sup> Based on one systematic review, resin infiltration with increased infiltration time is the best treatment approach in treating dental fluorosis.<sup>17</sup>

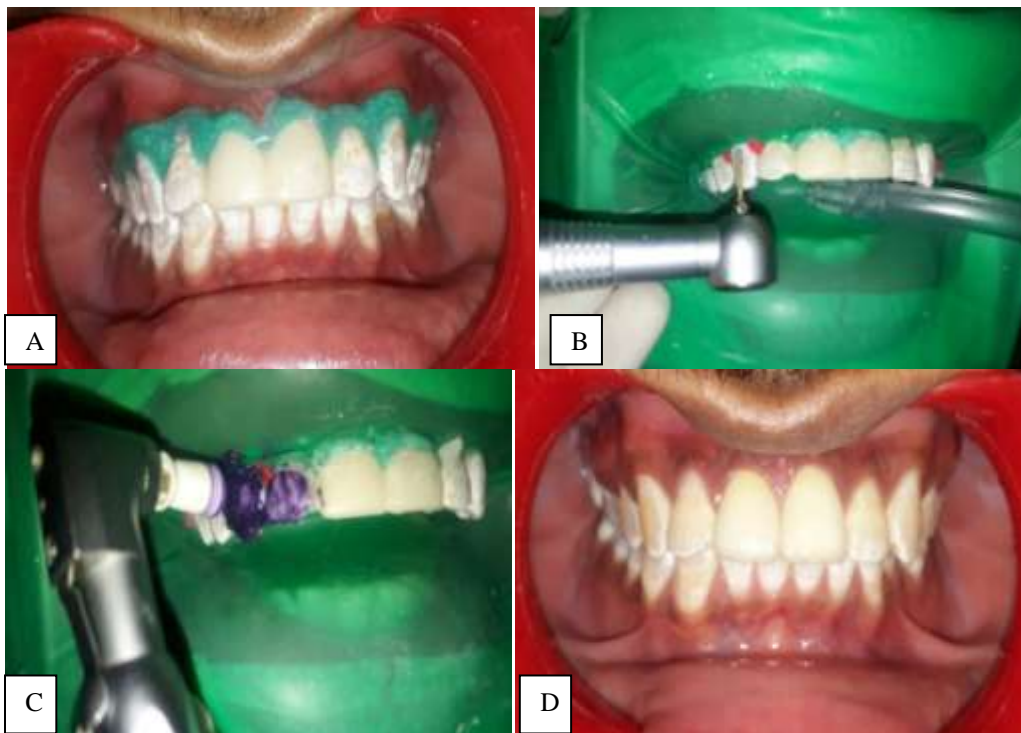
### Figures



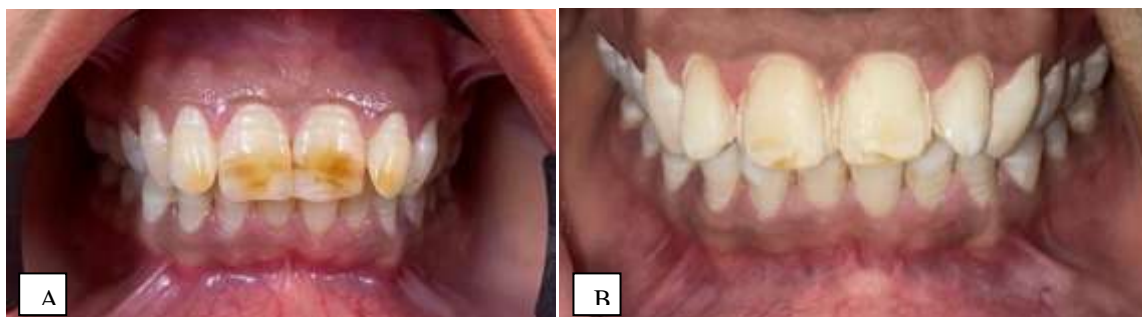
**Fig. 1:-**Case 1 (A) Dental Fluorosis with endodontically treated 11 and 21 (B) Double retraction cord was placed after tooth preparation in 11 and 21 region (C) One-step impression making done using Addition silicone (polyvinyl siloxane) (D) Immediate temporization using self-cured bisacrylate composite (3M ESPE™ Protemp).



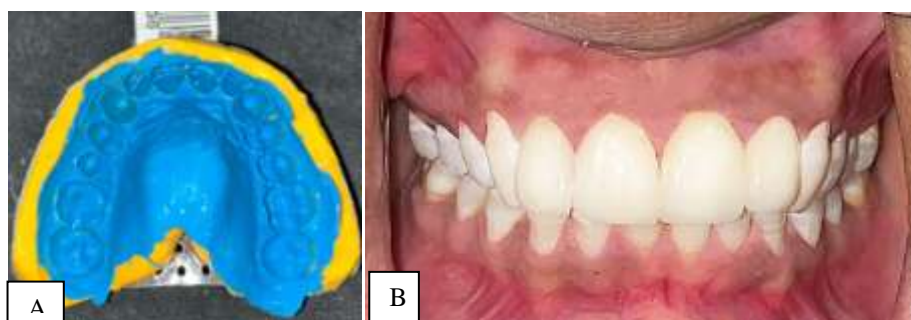
**Fig. 2 (A):-** “Opalustre Kit” (Opal dam green resin barrier with tip, 1.2 ml Opalustre syringe with white mac tip and finishing Opal cups having latch-type bristles) (B) GC tooth mousse for polishing.



**Fig. 3:-** Sequence of microabrasion technique (A) Gingival barrier was applied using Opal dam green resin barrier (B) Rubber dam placed for isolation and mild enamel microabrasion using rotary diamond bur (C) Opalustre slurry applied over tooth surfaces to be treated (D) Final view after completion of microabrasion and Zirconia crown with layered porcelain in 11 and 21 region.



**Fig. 4:-** Case 2 with moderate to severe grade fluorosis (A) Brown-yellowish discoloration of upper front teeth (B) Upper four anteriors prepared for veneers.



**Fig.5:-** (A) Impression with Addition silicone (polyvinyl siloxane) (B) Final view of resin bonded ceramic veneers.

### Conclusion:-

The microabrasion technique is non-invasive conservative method to treat mild to moderate fluorosis but will not be so effective in severe form. Therefore, as a clinician we should analyze first before selecting any particular treatment modality to treat fluorosis depending upon severity index. This should be done in order to save the patient as well as operator time by selecting proper mode of treatment and to achieve stable and satisfactory results.

### References:-

1. Sulieman M. An overview of tooth discoloration: extrinsic, intrinsic and internalized stains. *Dent Update*. 2005 Oct;32 :463-4, 466-8, 471. doi: 10.12968/denu.2005.32.8.463. PMID: 16262034.
2. Den Bestan P. K. Dental fluorosis: its use as a biomarker. *Advances in Dental Research*. 1994;8:105-10. doi: 10.1177/08959374940080010201. [PubMed] [CrossRef] [Google Scholar]
3. ES A. Occurrence and management of dental fluorosis. *Int Dent J*. 2001;51:325-33.
4. Bussadori SK, Do Rego MA, da Silva PE, Pinto MM, Pinto AC. Esthetic alternatives for fluorosis blemishes with usage of a dual bleaching system based on hydrogen peroxide at 35%. *J Clin Pediatr Dent* 2004;28:143-6
5. Celik EU, Yazkan B, Yildiz G, Tunac AT. Clinical performance of a combined approach for the esthetic management of fluorosed teeth: Three-year results. *Niger J Clin Pract*. 2017 Aug; 20:943-51. doi: 10.4103/1119-3077.180066. PMID: 28891537
6. Rotoli B. T. Porcelain veneers as an alternative for esthetic treatment: clinical report. *Operative Dentistry*. 2013; 38:459-66. doi: 10.2341/12-382-T. [PubMed] [CrossRef] [Google Scholar]
7. Dean HT. Classification of mottled enamel diagnosis. *J Am Dent Assoc (1922)* 1934;21:1421-6.
8. S. Ali, *et al.* Concentration of fluoride in groundwater of India: a systematic review, meta-analysis and risk assessment. *Groundw. Sustain. Dev.*, 9 (2019), Article 10022
9. Awadhiya S, Narang A, Agarwal M, Jain M. Nonvital Bleaching: A Case Series on whitening Procedure for Discolored Endodontically Treated Teeth. *Int J Prosthodont Restor Dent* 2018;8:28-31.
10. Rodrigues MC, Mondelli RF, Oliveira GU, Franco EB, Baseggio W, Wang L. Minimal alterations on the enamel surface by microabrasion: in vitro roughness and wear assessments. *J Appl Oral Sci* 2013;21:112-7.
11. Sundfeld RH, Sundfeld-Neto D, Machado LS, Franco LM, Fagundes TC, Briso AL. Microabrasion in tooth enamel discoloration defects: three cases with long-term follow-ups. *J Appl Oral Sci*. 2014 Jul-Aug;22:347-54. doi: 10.1590/1678-775720130672. PMID: 25141208; PMCID: PMC4126832.

12. Schmidlin PR, Gohring TN, Schug J, Lutz F. Histological, Morphological, profilometric and optical changes of human tooth enamel after microabrasion. *Am J dent* 2003;16:4A8A
13. Beier U. S., Kapferer I., Burtscher D., Dumfahrt H. Clinical performance of porcelain laminate veneers for up to 20 years. *The International Journal of Prosthodontics*. 2012;25:79–85. [[PubMed](#)] [[Google Scholar](#)] [[Ref list](#)]
14. Sherwood I. A. Fluorosis varied treatment options. *Journal of Conservative Dentistry*. 2010;13:47–53. doi: 10.4103/0972-0707.62631
15. Gupta A, Dhingra R, Chaudhuri P, Gupta A. A comparison of various minimally invasive techniques for the removal of dental fluorosis stains in children. *J Indian Soc Pedod Prev Dent*. 2017 Jul-Sep;35:260-268. doi: 10.4103/JISPPD.JISPPD\_138\_16. PMID: 28762354.
16. Budhwar P, Yadav R, Rao PL. Aesthetic management of discoloured anterior teeth with zirconia: A case report. *J Appl Dent Med Sci*. 2019;5:1
17. Shahroom NSB, Mani G, Ramakrishnan M. Interventions in management of dental fluorosis, an endemic disease: A systematic review. *J Family Med Prim Care*. 2019 Oct 31;8:3108-13. doi: 10.4103/jfmpe.jfmpe\_648\_19. PMID: 31742127; PMCID: PMC6857403.