



Journal Homepage: - www.journalijar.com
**INTERNATIONAL JOURNAL OF
 ADVANCED RESEARCH (IJAR)**

Article DOI: 10.21474/IJAR01/7000
 DOI URL: <http://dx.doi.org/10.21474/IJAR01/7000>



RESEARCH ARTICLE

ROLE OF MRCP IN HEPATOBILIARY PATHOLOGY IN CORRELATION WITH ERCP.

Selva Magesh Tamilarasan¹, Sonali Ullal², Sharada Rai³ and Akshay Parth⁴.

1. Post graduate Department of Radio-diagnosis, Kasturba medical college, Mangalore, Manipal Academy of Higher Education, Manipal, India.
2. Associate Professor Department of Radio-diagnosis, Kasturba medical college, Mangalore, Manipal Academy of Higher Education, Manipal, India.
3. Associate Professor Department of pathology, Kasturba medical college, Mangalore, Manipal Academy of Higher Education, Manipal, India
4. Post graduate Department of pathology, Kasturba medical college, Mangalore, Manipal Academy of Higher Education, Manipal, India.

Manuscript Info

Manuscript History

Received: 20 February 2018
 Final Accepted: 22 March 2018
 Published: April 2018

Keywords:-

Magnetic resonance imaging; Magnetic resonance cholangiopancreatography; Endoscopic retrograde cholangiography; Biliary ducts; Gallstone; Cholangiocarcinoma. Biliary strictures, choledocholithiasis, periampullary lesions.

Abstract

Title of the article: Role of MRCP in hepatobiliary pathology in correlation with ERCP.

Aim: To determine diagnostic accuracy of MRCP as compared to ERCP for evaluating biliary duct disorders using the specificity, sensitivity, positive and negative predictive values.

Patients and methods: From January 2010 to July 2016, 168 patients with suspected biliary pathology were included in this prospective and retrospective observational study. MRCP was performed prior to ERCP in all the patients included in this study.

Results: MRCP had a 94.09% sensitivity, 94.03 % specificity, 91.30% positive predictive value, 95.96 % negative predictive value (NPV) and 94 % accuracy rates in diagnosing biliary calculus.

MRCP had a 92.31% sensitivity, 95.35%, specificity, 85.71% positive predictive value, 97.62% negative predictive value (NPV) and 94.64% accuracy rates in diagnosing tumours/cyst. MRCP had a 74.51 % sensitivity, 97.44 % specificity, 92.68%, positive predictive value 89.76%, negative predictive value (NPV) and 90.48%, accuracy rates in diagnosing tumours/cyst other biliary disorders like CBD stricture, periampullary diverticulum and others.

Conclusion: MRCP is an accurate investigation compared with diagnostic ERCP for the assessment of biliary pathologies.

Copy Right, IJAR, 2018,. All rights reserved.

Introduction:-

Anatomy and pathology of the biliary tract is important for early diagnosis and treatment of biliary tract disease. Biliary obstruction may be due to choledocholithiasis, tumours or trauma, among other causes. The most common cause is choledocholithiasis. Magnetic resonance cholangiopancreatography (MRCP) is the most accurate, noninvasive imaging study for the hepatobiliary system [7,10,12]. Endoscopic retrograde cholangiopancreatography (ERCP) is the gold standard for evaluation of the biliary pancreatic region.

Corresponding Author:- Sonali Ullal.

Address:- Associate professor Department of Radio-diagnosis, Kasturba medical college, Mangalore, Manipal Academy of Higher Education, Manipal, India.

The new modes of MR sequencing provide clear projectional images that are similar to images obtained during ERCP, while routinely performed by experienced gastroenterologists, is still associated with adverse effects like pancreatitis, bile leak, hemorrhage, gastro duodenal perforation and sepsis with a morbidity rate of 7% and a mortality rate of 1% [36].

The development of fast imaging sequences and the improvements in the quality of abdominal images have generated a new interest in magnetic resonance evaluation of biliary & pancreatic diseases[35]. With the help of advanced imaging sequences, we can get the images equal that of ERCP[17].

Most researchers have reported that these new MRCP sequences are even better than ERCP because they accurately diagnoses pancreatobiliary diseases[24,3,9]. MRCP is a less costly, non-invasive, and sensitive technique for evaluating the biliary and pancreatic ductal systems.

In MRCP, multiplanar images are obtained parallel to the orientation of the biliary tree, using an MR sequence that is sensitive to static fluid without the need for exogenous contrast agents. Fluid in the ducts appears bright against the darker tissue. MRCP can diagnose the presence of bile duct obstruction and the level of obstruction in most cases.

MRCP is unique due to its accuracy and noninvasive nature and its ability to depict ducts proximal to a high-grade obstruction. As a result, at some centers, ERCP is now used primarily as a means of gaining access for interventions such as stent placements instead of as a diagnostic tool.

The major disadvantage of MRCP is that it is entirely diagnostic, in contrast to ERCP, which provides diagnostic information as well as access for therapeutic interventions.

Other disadvantages of MRCP include decreased spatial resolution and the quality of imaging in patients who are in a physiological, non-distended state .

In this retrospective and prospective study we predict the accuracy, sensitivity and specificity of MRCP as compared to ERCP, which is considered as a gold standard for evaluation of hepatobiliary

Objectives:-

To evaluate and correlate the accuracy between Magnetic Resonance Cholangio-Pancreatography and endoscopic retrograde cholangiopancreatography in diagnosing suspected cases of biliary obstruction .

Materials And Methods:-

During the period January 2010 to July 2016, 168 patients with suspected biliary pathology who underwent MRCP and ERCP, were included in this prospective and retrospective observational study.

This cross-sectional study was designed to include former and current patients with clinical features of biliary pathology who subsequently underwent MRCP and ERCP over a 12 month period.

The study participants were divided into four main groups. Normal into group I, stone disease into group II, tumors/cysts into group III and others into group IV.

The sensitivity, specificity, and positive and negative predictive values For MRCP were calculated as compared to the ERCP.

Results:-

Total number of cases collected were 168. Among them 11 cases in group I, 67 cases in group II, 39 cases in group III and 51 cases in group IV. In group II with 67 patients, MRCP had a 94.09% sensitivity and a 94.03 % specificity. Its positive predictive value (PPV), negative predictive value (NPV) and accuracy rates were 91.30%, 95.96% and 94% respectively.

Out of 39 group III patients, MRCP had a sensitivity, specificity, PPV, NPV and total accuracy rates of 92.31%, 95.35%, 85.71, 97.62, and 94.64% respectively for 39 patients in group III.

Out of 51 in Group IV patients, the MRCP had 74.51 % sensitivity and 97.44 % specificity. Its PPV, NPV and accuracy rates were 92.68%, 89.76% and 90.48%, respectively

Conclusion:-

From this study, we conclude MRCP is an alternative to ERCP in the diagnosis of pancreaticobiliary pathology. Due to high sensitivity and specificity we recommend the use of MRCP for diagnosis of biliary pathologies and can be performed rapidly and non invasively

Materials And Methods:-

Study Design:-

During the period January 2010 to July 2016, 168 patients with suspected biliary pathology who underwent MRCP and ERCP, were included in this prospective and retrospective observational study. The sample size was estimated to 168 patients. Our study was performed at the MRI and the ERCP units of Kasturba medical college Ambedkar circle, Manipal University, Mangalore. In all the patients included in this study MRCP was performed prior to ERCP.

Inclusion Criteria:-

The study included

- Patients referred to the department of radiodiagnosis with clinical suspicion of biliary tract and gallbladder pathology.
- Patients detected with biliary tract pathology on ultrasonography

Exclusion Criteria:-

The study excluded

- Pregnant women.
- Patients allergic to contrast.
- Patients who underwent recent interventional procedures on the biliary tract.
- Patients with cardiac pacemakers
- Severe claustrophobia

Ethical Consideration:-

Numerous ethical considerations were considered in the process of this research. Kasturba medical college hospital ethical committee was requested to approve the research proposal. Patient's personal information e.g. names were not to be used in the study in order to uphold confidentiality. Information acquired would not be used for any other purpose besides in the clinical management of patients and academics. The study was approved by the institute's ethical committee. Patients were requested to provide an informed consent in writing.

SCANNING PARAMETERS:

- Technique/sequences used:
 - 1) MRCP 3D HR- A navigator triggered heavily T2W1 high resolution 3-dimensional scan.
 - 2) T2 Coronal half-Fourier acquisition single-shot turbo spin-echo (HASTE)
 - T2 axial sections
 - 4) GRE sequences
 - 5) True fast imaging with steady-state free precession (TRUF1)
 - 6) volumetric interpolated breath-hold examination (VIBE)

All the MRCP studies were done on a 1.5 T magnetic resonance (Siemens, Germany) using a 16 phased array coil.

Single shot fast spin echo (SSFSE) with an adequate field of view was used to get the axial images. Spin echo axial T2 images were acquired using a TE of 102, Field of view (FOV) of 28 to 38cm, slice thickness of 8mm, with a spacing of 2mm. Frequency encoding was done from right to left. Phase encoding FOV was 8cm. Long TE was used to perform thick slabs to image the biliary and pancreatic ducts.

ERCP technique:

Fluoroscopy: A GE OEC 850 was used for screening and taking hard copy plain films. Duodenoscopy: An Evis Olympus JF type 180 side view duodenovideoscope was used. The procedure was performed with patients under conscious sedation or short general anesthesia, depending on the individual evaluation of the patients by the anesthetist.

Patients were positioned in the prone position and ERCP performed by an experienced surgical endoscopist. The endoscopist had no access to information from the prior MRCP.

Image Analysis:-

Both MRCP and ERCP images were retrospectively interpreted by experienced radiologists and gastroenterologists respectively in a blinded fashion.

Data Collection:-

Qualified radiologists diagnosis and gastroenterologist's intra-operative findings were filled in the pretested questionnaire by the researcher.

Statistical Analysis:-

Statistical Package for Social Scientists (SPSS) was used for data analysis. Subsequently , tables, pie charts and graphs were used to present the data. Images, when available were presented for some cases.

Results:-

Total number of cases collected : 168

- normal group I 11
- Calculus group II 67
- Tumours/cysts group III 39
- others group IV 51

11 patients are identified under group I who had a normal MRCP and ERCP examinations.

MRCP identified stone disease in 67 Group II patients, but confirmed ERCP shows stone disease in 63 patients. In group II with 67 patients, MRCP had a 94.09% sensitivity and a 94.03 % specificity .Its positive predictive value (PPV), negative predictive value (NPV) and accuracy rates were 91.30%, 95.96% and 94% respectively.

Out of 39 group III patients with tumours,periampullary mass was seen in 11, Klatskintumour in 10, Cholangiocarcinoma in 13, IPMN-- 2,carcinoma head of pancreas -1 and caroli's disease 2. MRCP had a sensitivity, specificity, PPV, NPV and total accuracy rates of 92.31%, 95.35%, 85.71, 97.62, and 94.64% respectively for 39 patients in group III.

Out of 51 in Group IV patients ,CBD stricture in 27,periampullary diverticulum in 3,pancreatic duct leak in severe pancreatitis - 2,calcific pancreatitis in 1,dilated CBD with no obvious obstructive lesion in 16 and cholangitis in 2.

In group IV, the MRCP had 74.51 % sensitivity and 97.44 %specificity. Its PPV, NPV and accuracy rates were 92.68%, 89.76% and 90.48%, respectively

Table/fig 1:- Diagnostic effectivity of MRCP in various pathologies in comparison with ERCP and histopathological outcome

Disease group	Sensitivity	Specificity	PPV	NPV	Accuracy	p-value
Calculus	94.09%	94.03 %	91.30%	95.96%	94%	<0.0001
Tumours/cyst	92.31%	95.35%,	85.71%	97.62%	94.64%	<0.0001
Others	74.51%	97.44%	92.68%	89.76%	90.48%	<0.0001

Discussion:-

In our study, we found that the accuracy of MRCP for detection of bile duct calculi was comparable to ERCP, MRCP also had a high sensitivity for detection of benign CBD strictures.

In many recent studies, MRCP has been shown to have a diagnostic accuracy comparable to that of ERCP, with the ability to demonstrate small biliary stones and the advantage of not using ionizing radiation[30,33]

In our department, Study of the biliary tract is performed using axial and coronal half-Fourier acquisition single-shot turbo spin-echo T2-weighted images(HASTE) with long TR and MRCP 3D -A navigator triggered heavily T2W1 high resolution 3-dimensional scan which provide a cholangiographic display. The coronal plane is used to provide a cholangiographic display and the axial plane is used to evaluate the pancreatic duct and the distal common bile duct[24]

Group II: Stone disease:-

In our study MRCP identified stone disease in 67 patients, but confirmed ERCP shows stone disease in 63 patients. Out of 67 patients, 3 had cholelithiasis with choledocholithiasis which was accurately detected in MRCP.

In our study MRCP had a 94.09% sensitivity and a 94.03 % specificity and accuracy rate of 94 % in detection of stone disease. In a study done by D Hurter et al [16] on 52 patients they found a sensitivity, and specificity of MRCP 87 % and 80 % for the detection of choledocholithiasis. The paper concluded that MRCP due to its non invasive nature, less complications rates and comparable sensitivity to ERCP for detection of biliary duct pathologies, has the potential to replace ERCP as a diagnostic test. This study, however, had a small sample size.

WenChen et al [5]analysed 25 publications which include 2310 with suspected CBD calculus and 738 with CBD stones. Sensitivity and specificity of MRCP in detecting CBD stones were 90% and 95 % respectively. The article concludes that MRCP has high diagnostic accuracy for the detection of choledocholithiasis and MRCP should be the method of choice for suspected cases of CBD stones.

In systematic review done by Kats J et al CBD stones were diagnosed by MRCP in 25 patients confirmed by ERCP in 24 patients.. Sensitivity and specificity of MRCP in detecting stones were 100% and 96% respectively[23].

In another systematic review done by Kenneth M. Vitellas et al[31] MRCP findings are seen correlation with ERCP in detection of CBD calculus and superior to CT or ultrasonography. Sensitivities and specificities for MRCP are 81%–100% and 85%–100% respectively. MRCP offers a number of advantages compared with ERCP, which is the standard of reference for imaging the biliary tract and pancreatic duct.

Unlike ERCP, MRCP is performed rapidly and does not expose patients to ionizing radiation or iodinated contrast material. The major disadvantage of MRCP is that it is entirely diagnostic, and this is in contrast to ERCP, which provides diagnostic information as well as access for therapeutic interventions[14].

Diagnostic pitfalls include air, blood, and signal loss due to surgical clips after cholecystectomy. High signal from adjacent fluid collections, ascites, or edema may also interfere with biliary signal. Arterial pulsatile compression and flow artifacts may mimic filling defects. Coronal and axial T2-weighted images are helpful in avoiding these pitfalls.

CBD calculi which are smaller than the slice thickness used in MRCP sequence can be easily missed. Motion artifacts due to physiological movements like respiration/ peristalsis/ pulsation artifacts also lead to degradation of the image quality, hence, non visualization of small CBD calculi. Differentiation of choledocholithiasis from malignant biliary obstruction has been one of the challenges in MRCP examinations.

Abrupt termination of the bile duct and the absence of typical signs of biliary lithiasis have a high correlation with malignancy (Fig.8 ,9). These features can be visualized through coronal T2-weighted images or by correlation with sequential axial images. Currently, the primary role of ERCP is to provide access to the pancreaticobiliary tract for stone extraction, stent placement, balloon dilatation and other interventions[Fig 8 b]..

ERCP has long been considered the standard of reference for examination of common bile duct stones, but MRCP has proven to be superior to ERCP for the diagnosis of intrahepatic bile duct stones, because ERCP cannot opacify the biliary duct system upstream to a stenosis.

The ability of MRCP to visualize peripheral intrahepatic bile ducts makes this technique well suited to the evaluation of stones in this site. One of our patient with caroli's disease with intrahepatic biliary stones was demonstrated clearly in MRCP images (Fig-4)

Many studies on MRCP shows high sensitivity (60% - 100%) and specificity (90 - 100%) tool for stone disease [32,34]. NPV values of MRCP are high, 92.80% - 99.84%. [19] So, if MRCP shows negative for common duct stones, one can be confident that stones are not present in most cases and ERCP can be avoided. One of the major benefits of MRCP in the case of suspicious biliary stone is the reduction of ERCP [29].

Pitfall of MRCP is whenever slice thickness were more than 5 mm, there were chances of missing tiny calculi. The false negative occur whenever a calculus is smaller than 5 mm which happened in 4 of our stone disease patients.

Radiologists should be aware that maximum intensity projection reconstructed images can obscure small filling defects and that source images remain indispensable for radiologists in order to make the correct diagnosis

False-positive diagnoses may be due to pneumobilia, cystic duct insertion into the bile duct and extrinsic compression by an adjacent artery. [9,19]

Kim & colleagues [28] recommended that MRCP can be performed before cholecystectomy in an effort to decrease morbidity associated with undetected choledocholithiasis and reduced the performance of purely diagnostic ERCP.

Group III: Tumours/cysts

Out of 39 patients with tumours, periampullary mass was seen in 11, Klatskin tumour in 10, distal cholangiocarcinoma in 13, IPMN-- 2, carcinoma head of pancreas -1 and caroli's disease-2. MRCP had a sensitivity, specificity, PPV, NPV and total accuracy rates of 92.31%, 95.35%, 85.71, 97.62, and 94.64% respectively for 39 patients with tumours.

MRCP helps in evaluating cholangiocarcinoma in general and hilar cholangiocarcinoma in particular. Because MRCP readily depicts ducts proximal to high-grade obstructions that are often not opacified at ERCP, MRCP typically is superior in determining disease extent and resectability [19,26].

Two of our patients with klatskin tumour presented as hilar stricture (Fig 9). 5 of our patients with distal cholangiocarcinoma also presented as stricture. Although morphological features of benign and malignant strictures are defined, differentiation may be difficult at times.

It is difficult to distinguish between large stones and cholangiocarcinomas on ERCP, but even in MRCP without contrast we can diagnose stone disease because of the typical hypointense nature of stones on T2-weighted images [23].

The 'double-duct sign' on MRCP is helpful in diagnosing pancreatic carcinoma [27] which was seen in one of our patient with pancreatic head malignancy. In our study, three of the cases were interpreted as periampullary mass and final diagnosis by ERCP made as IPMN.

Communication between the duct and the abnormal cystic structure can be shown with MRI and MRCP. But it was not so possible in our cases and was merely reported as peripillary mass.

MRCP reliably detects choledochal cysts and provides details equivalent to ERCP without the risk of complications. Two of our cases were Caroli's disease which was correctly diagnosed by MRCP (Fig 4).

C. Matos et al [34] did a prospective study with the data provided with ERCP and MRCP in 8 patients with choledochal cysts. 7 of the 8 patients had relapsing pancreatitis. Similarity was observed between ERCP and MRCP for defining the anatomic characteristics of the cyst (7 type I cysts, 1 type IV cyst) and the presence of an abnormal pancreaticobiliary junction (PBJ) (6 cases)

Group IV: Others

Most false positive cases in our study were due to detection of benign strictures when they were not present. Arterial pulsation artifacts and defects caused by the crossing of hepatic artery over CBD can result in false interpretation of MRCP images and over diagnosis of biliary duct strictures. In one of our case it was reported as mid CBD stricture, but there was no stricture detected in ERCP (Fig:10)

Edematous bile duct secondary to passage of calculi was misinterpreted as a stricture on MRCP images in 2 of our cases

Edematous ampulla was mistaken for periampullary nodule/mass in 4 of our cases. Sensitivity for detection of periampullary/ampullary lesions can be increased by doing a conventional post contrast MRI abdomen imaging in addition to MRCP, in which enhancing small periampullary/ampullary lesions can be easily picked up and will not be confused with non enhancing lesions like sludge ball or edematous ampulla due to passage of calculi. Terminal segment of the bile duct at the ampulla of Vater contains less fluid within its lumen, therefore it becomes difficult to identify a small impacted calculi or a small periampullary nodule, and moreover sometimes the bulging duodenal papilla can mimic a papillary tumor.

MRCP provides accurate delineation of the ductal manifestations of chronic pancreatitis, which is of utmost importance in determining disease extent and in planning surgical drainage procedures. One of the patients had calcific pancreatitis which had good correlation with ERCP.

Conclusion:-

From this study, it is recommended that MRCP is an efficient diagnostic procedure for detection of presence, level, cause of obstruction and routinely advocated before any intervention is planned.

We conclude that MRCP has been shown to have a wide range of clinical applications, and it has been accepted as an accurate technique for non-invasive imaging of the pancreaticobiliary tract because it offers a number of advantages compared with ERCP, the reference standard for imaging the biliary tract and pancreatic ducts.

Table/fig 2:- MRCP with ERCP correlation in stone cases

		ERCPstone		Total
		Yes	No	
MRCPstone	Yes	63	6	69
		91.3%	8.7%	100.0%
		94.0%	5.9%	41.1%
	No	4	95	99
		4.0%	96.0%	100.0%
		6.0%	94.1%	58.9%
Total		67	101	168
		39.9%	60.1%	100.0%
		100.0%	100.0%	100.0%

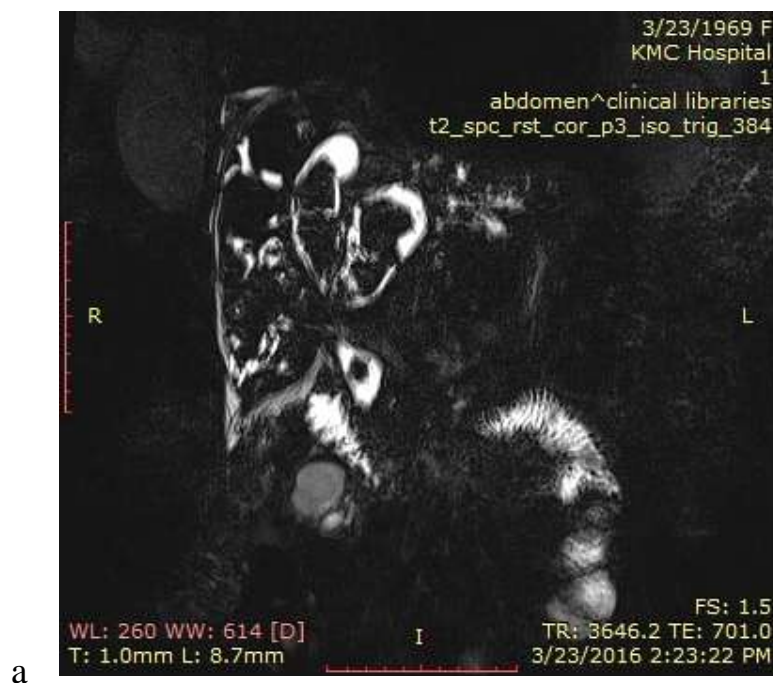
	Estimate	Confidence Interval	
		Lower	Upper
Sensitivity	94.03	88.36	99.70
Specificity	94.06	89.45	98.67
PPV	91.30	84.66	97.95
NPV	95.96	92.08	99.84
Overall accuracy**	94.05	90.47	97.63

	Value	p=	
Kappa	.876	0.000	HS

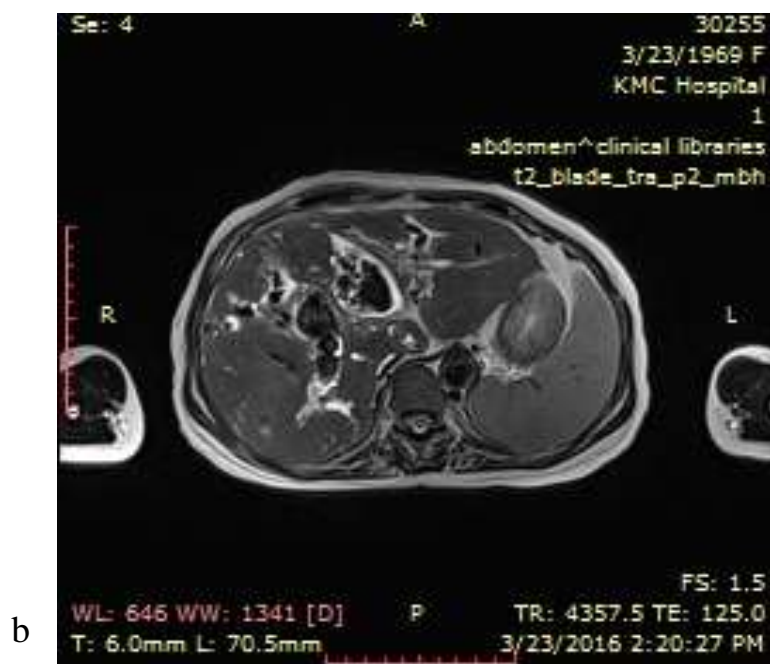
Table/fig 3:- MRCP with ERCP correlation in tumour cases

		ERCPtumour		Total
		Yes	No	
MRCPtumour	Yes	36	6	42
		85.7%	14.3%	100.0%
		92.3%	4.7%	25.0%
	No	3	123	126
		2.4%	97.6%	100.0%
		7.7%	95.3%	75.0%
Total	39	129	168	
	23.2%	76.8%	100.0%	
	100.0%	100.0%	100.0%	

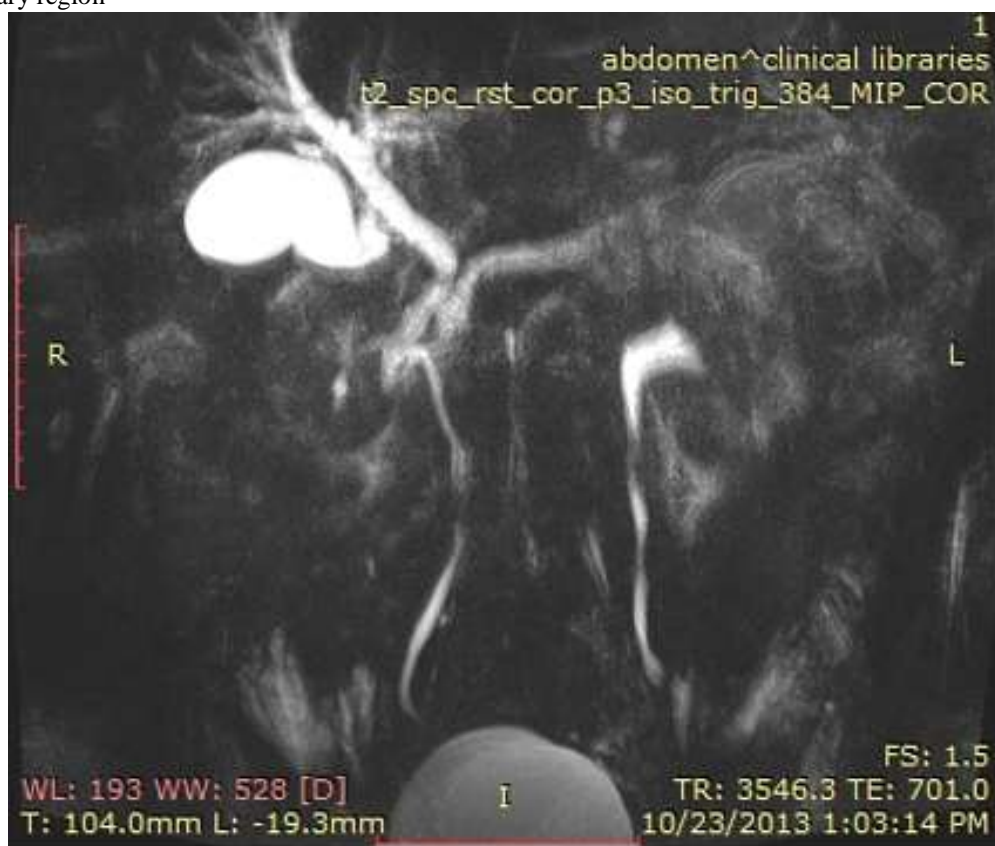		Confidence Interval	
	Estimate	Lower	Upper
Sensitivity	92.31	83.94	100.67
Specificity	95.35	91.71	98.98
PPV	85.71	75.13	96.30
NPV	97.62	94.96	100.28
Overall accuracy**	94.64	91.24	98.05
	Value	p=	
Kappa	.854	0.000	HS

Table/fig 4: a,b:MRCP images depicting caroli's disease with cystic dilatation of CBD,CHD and intrahepatic biliary radicals with multiple large calculi in agreement with ERCP

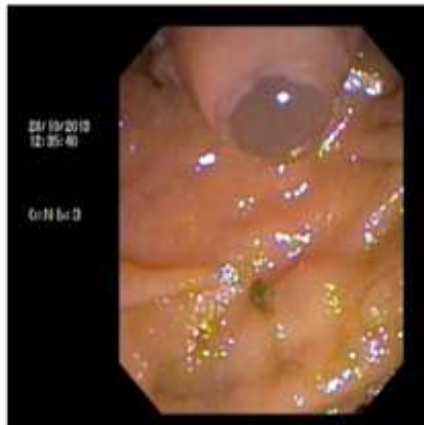
a



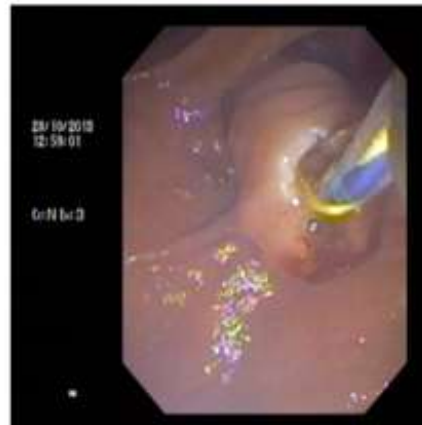Table/fig 5: a : MRCP images show dilated CBD and pancreatic duct with altered signal intensity lesion in the periampullary region



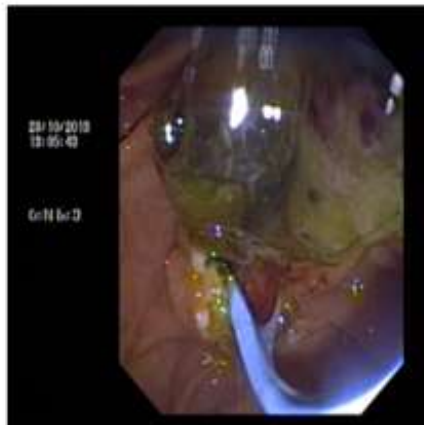
b :ERCP reveals intrapancreatic mucinous neoplasm



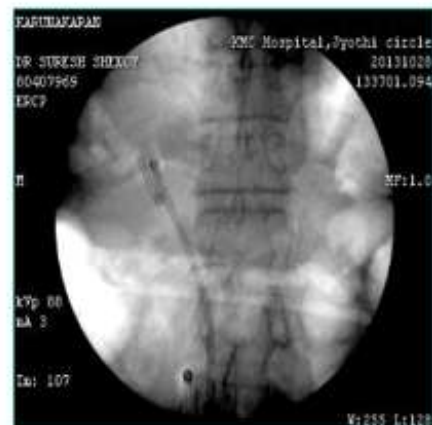AMPULLA



SPHINCTEROTOMY

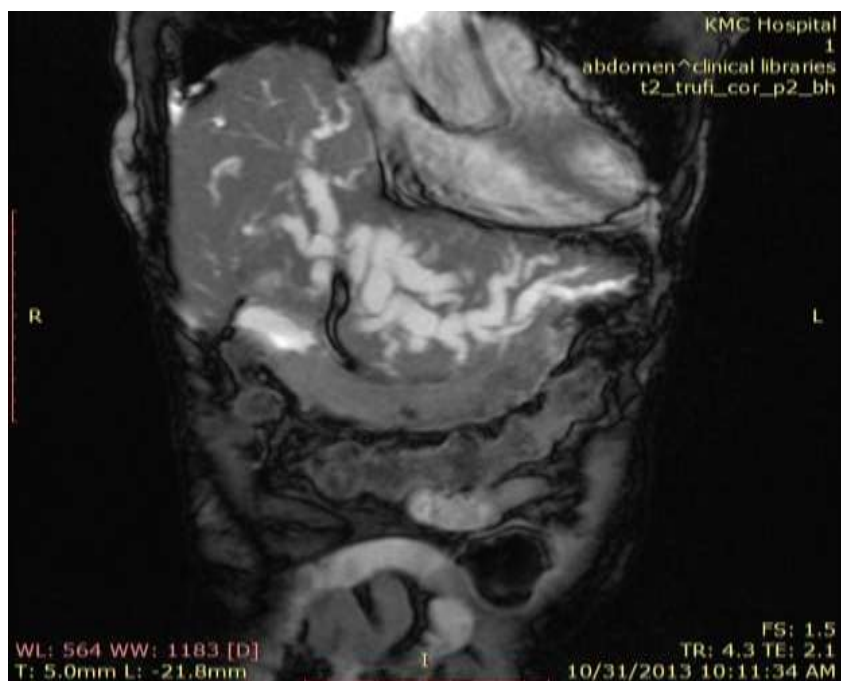


BALLOON SWEEP

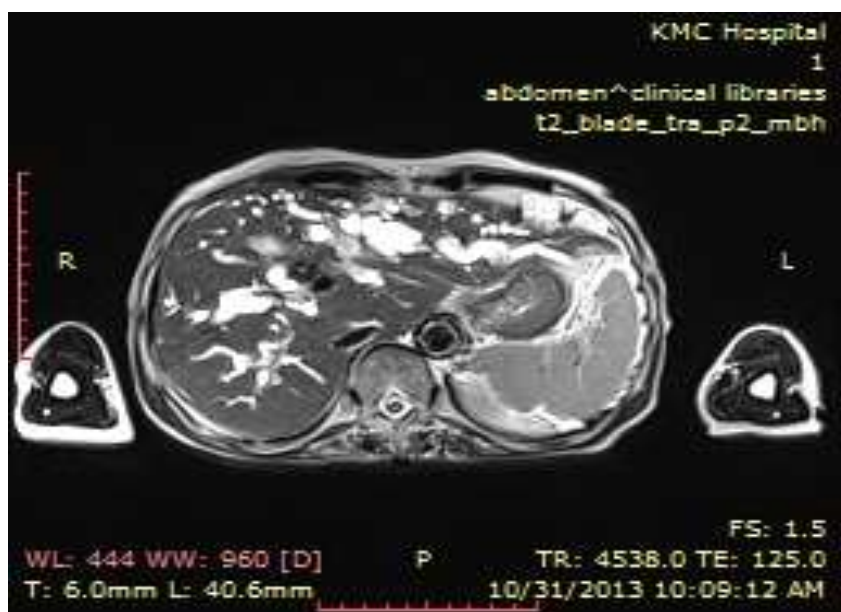


FLUORO IMAGE FOR STENT

Table/fig 6:- a,b : MRCP images showing gross dilatation of intrahepatic biliary radicles, right and left hepatic duct dilatation with altered signal intensity mass at the confluence of right and left hepatic duct representing klatskin's tumour

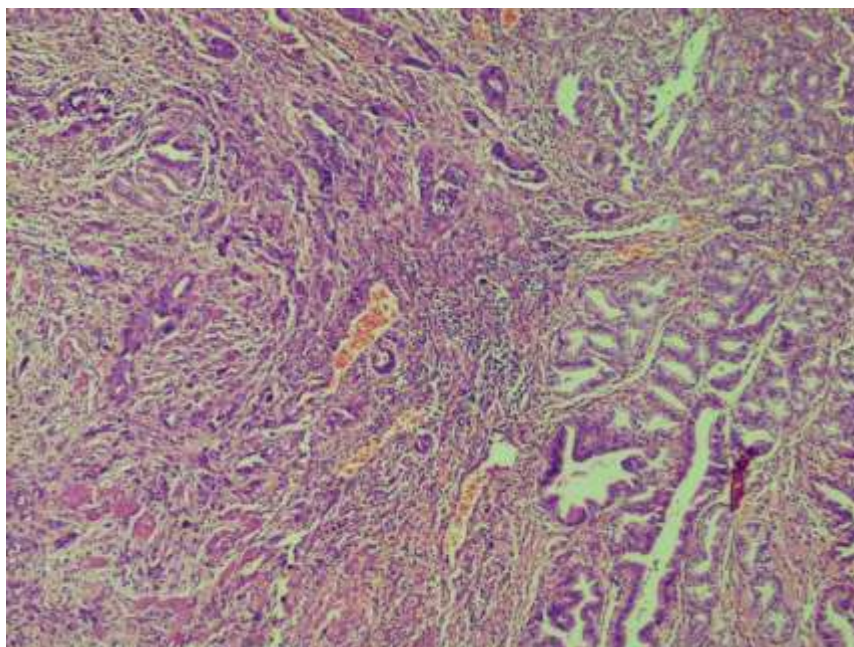


a

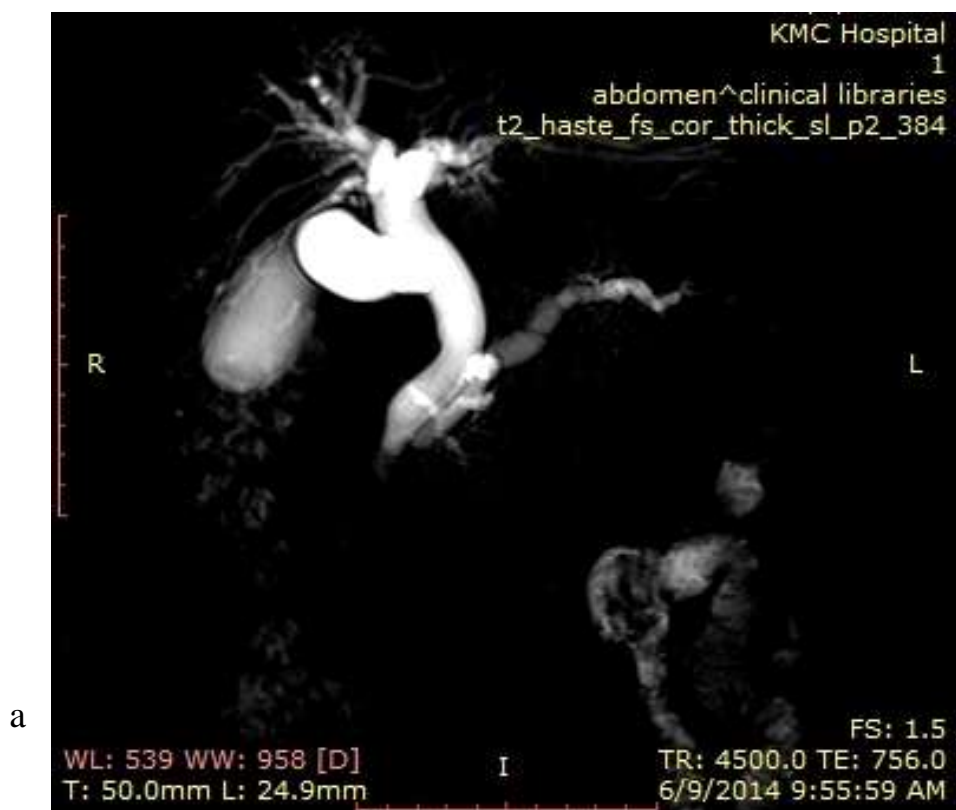


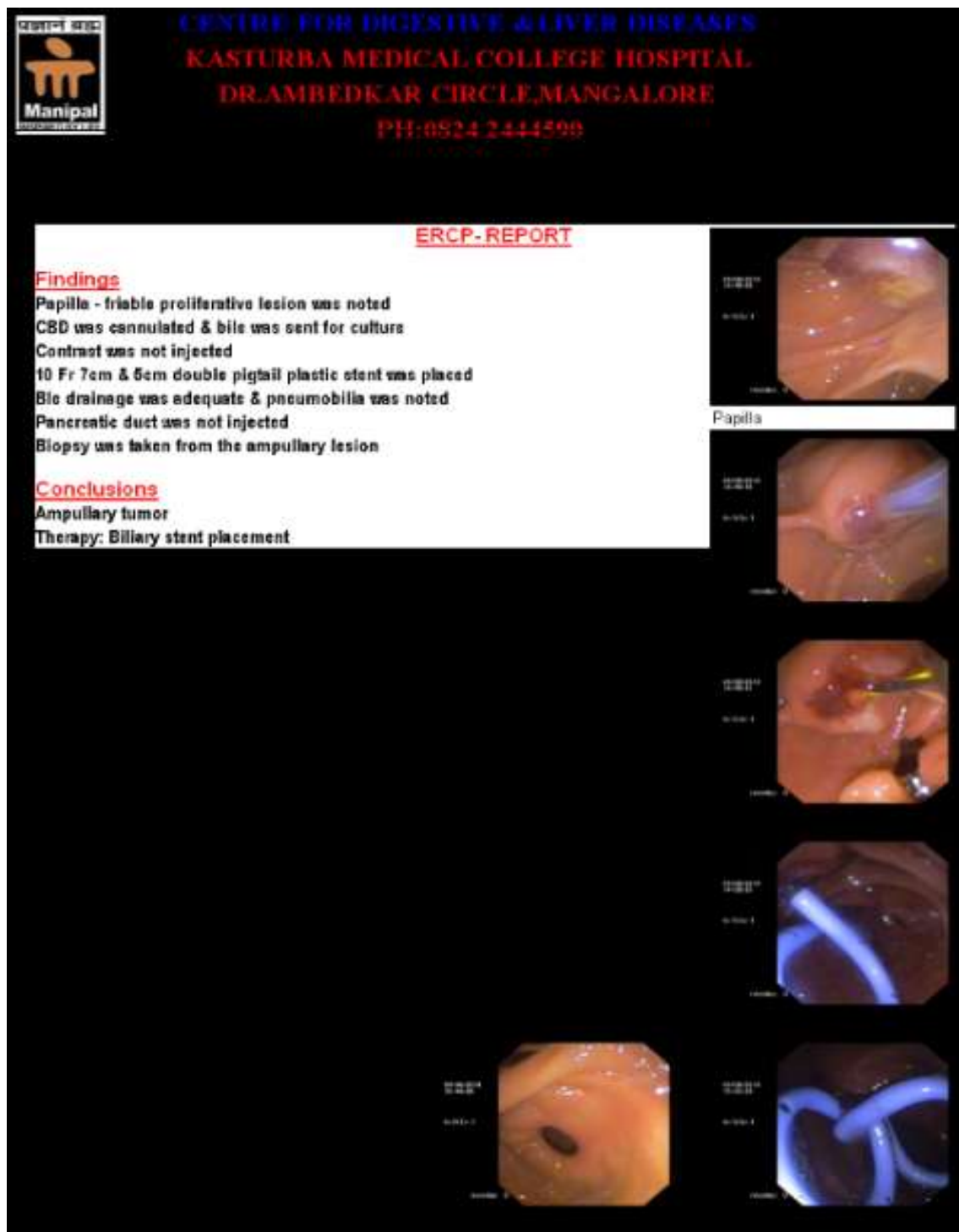
b

c.Histopathological examination reveals well differentiated adenocarcinoma –Cholangiocarcinoma



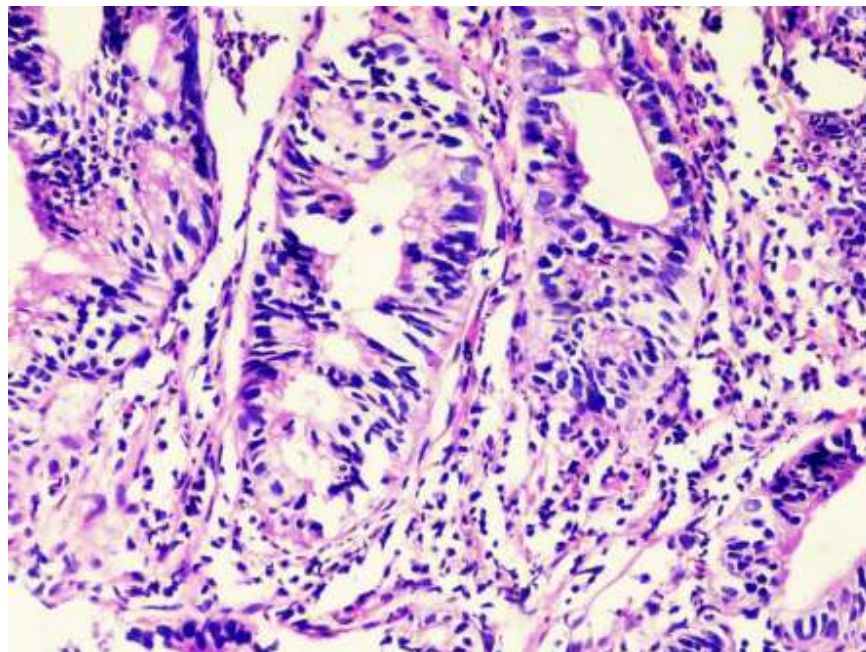
Table/fig 7:- a,b : MRCP and ERCP image showing ampullary nodule causing dilatation of the CBD and pancreatic duct which is confirmed in ERCP





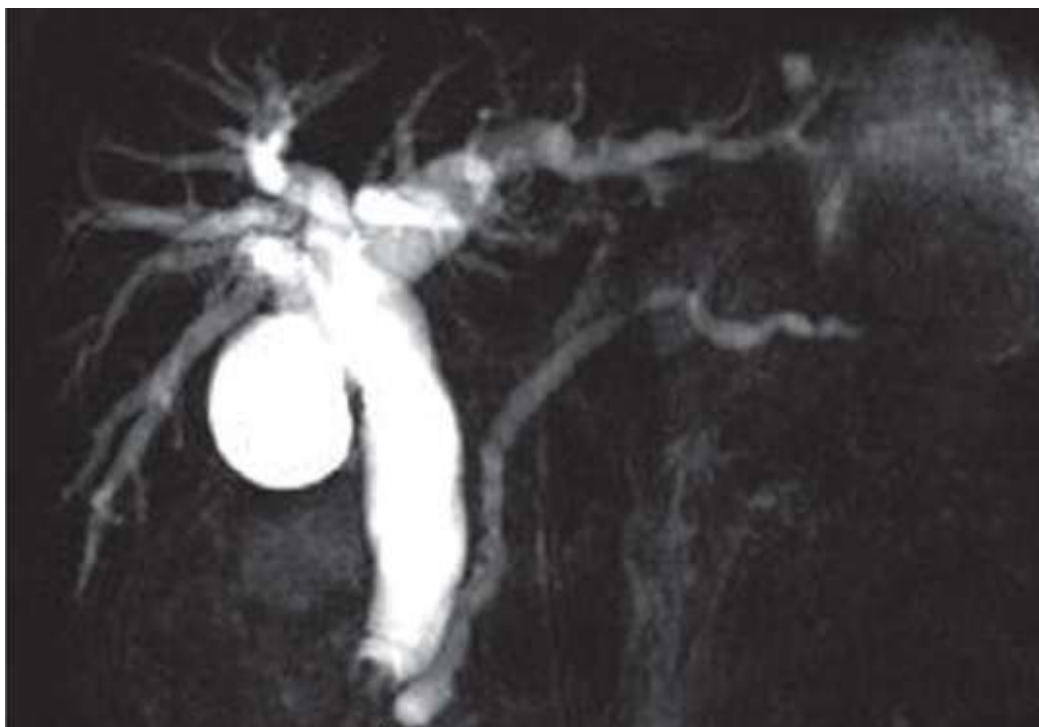b

c. Histopathological examination reveals moderately differentiated adenocarcinoma showing back to back arranged glands -Cholangiocarcinoma

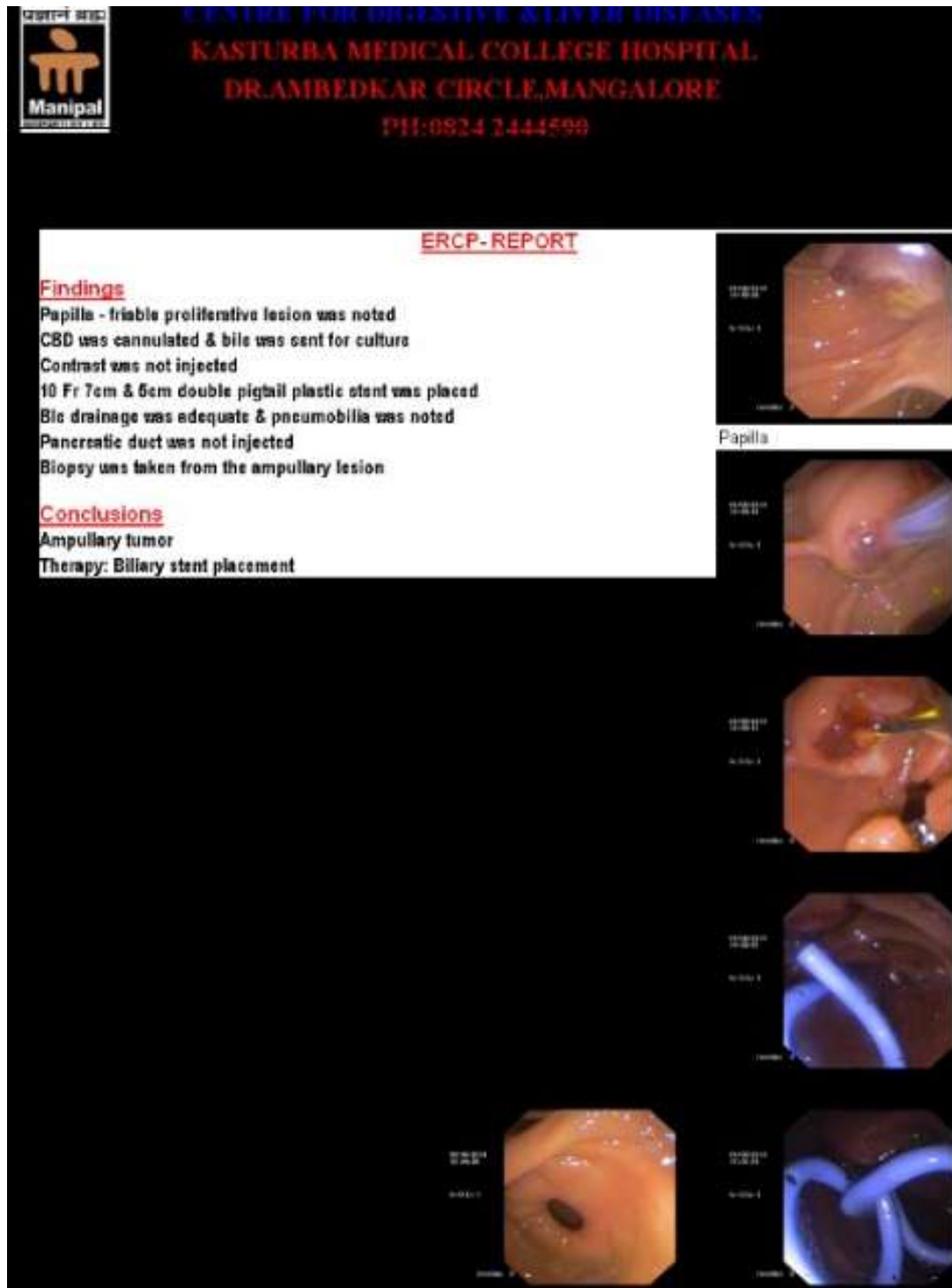


c.

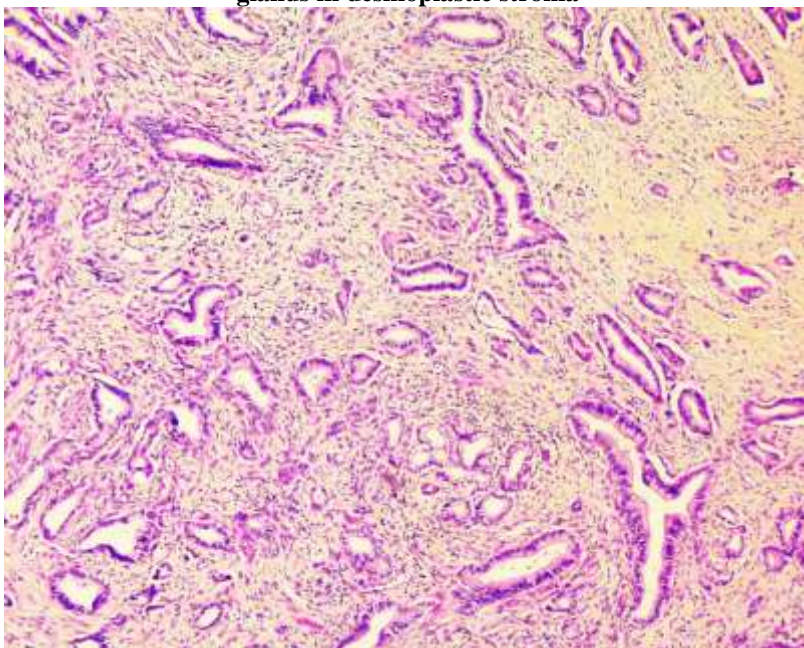
Table/fig 8:- a: MRCP demonstrates dilatation of intrahepatic and extrahepatic bile ducts and the pancreatic duct as well as the low signal intensity mass(no convex margin) in the ampulla of Vater



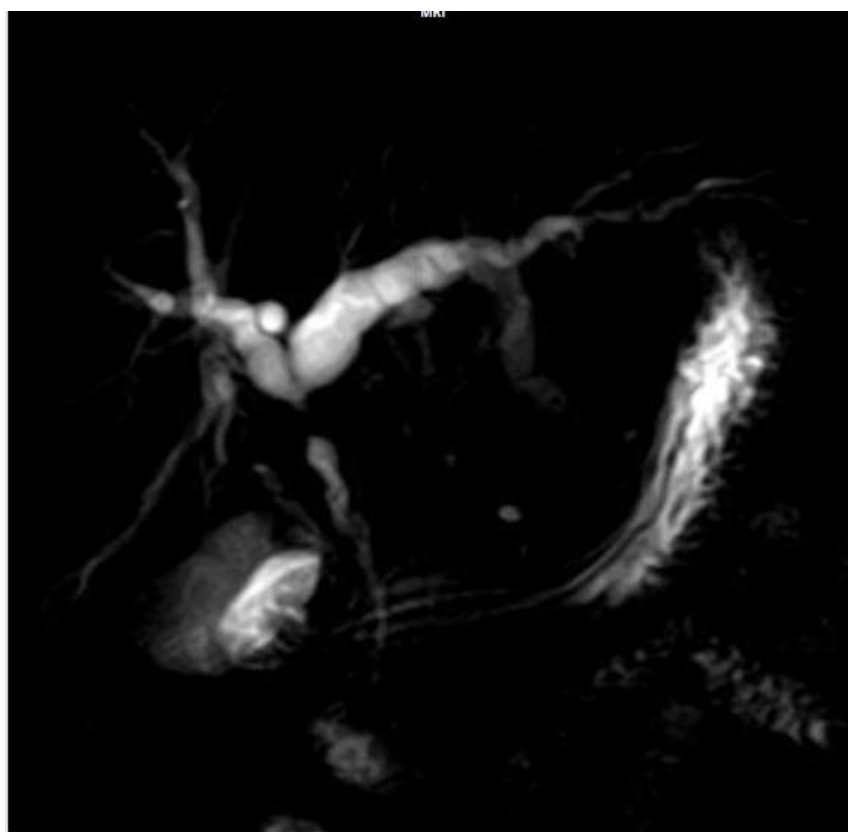
b: ERCP demonstrates mass in the ampulla of Vater. Biopsy of the mass and biliary stent placement was done



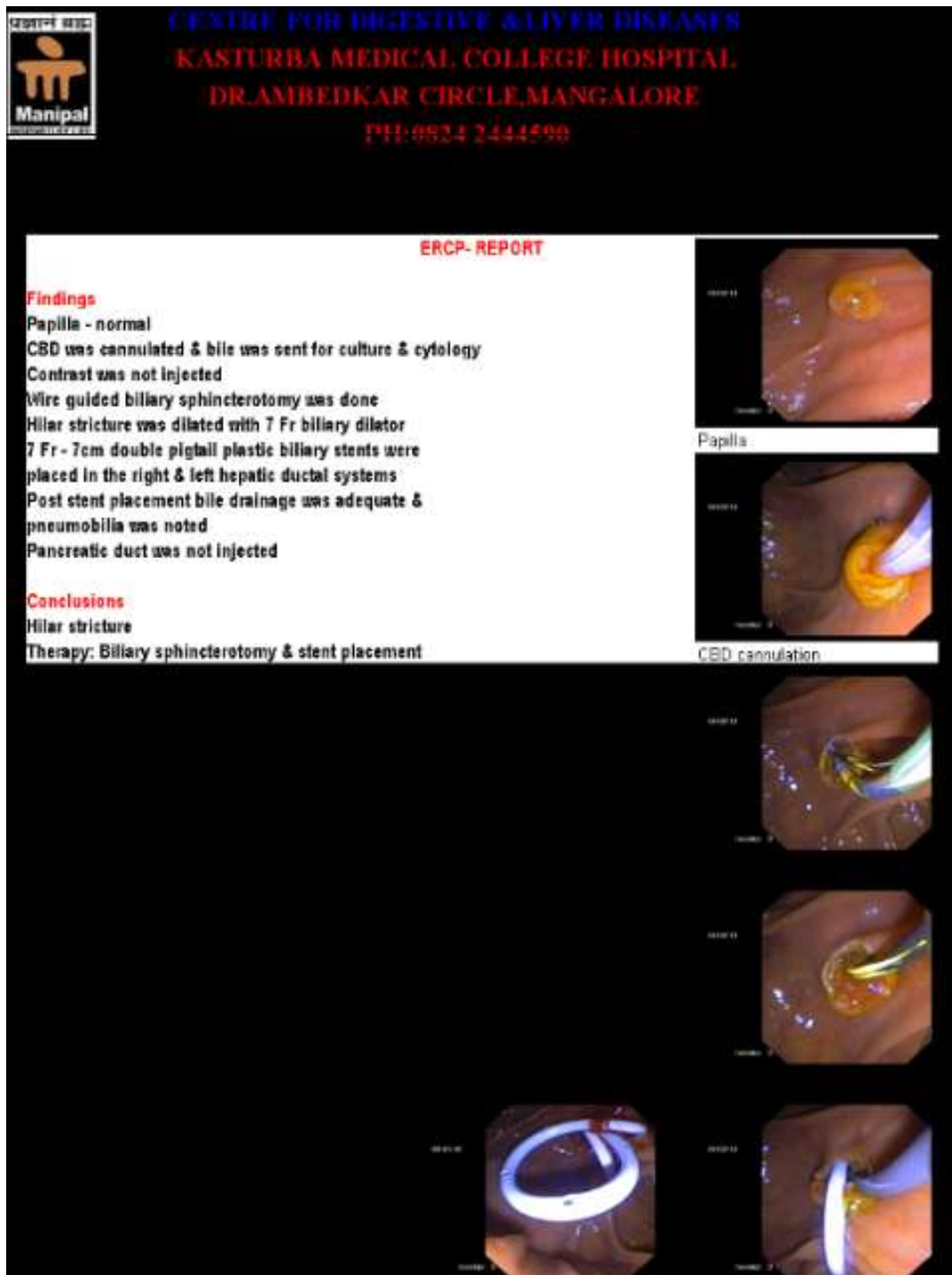
c: Histopathological examination reveals well differentiated adenocarcinoma showing irregularly shaped glands in desmoplastic stroma



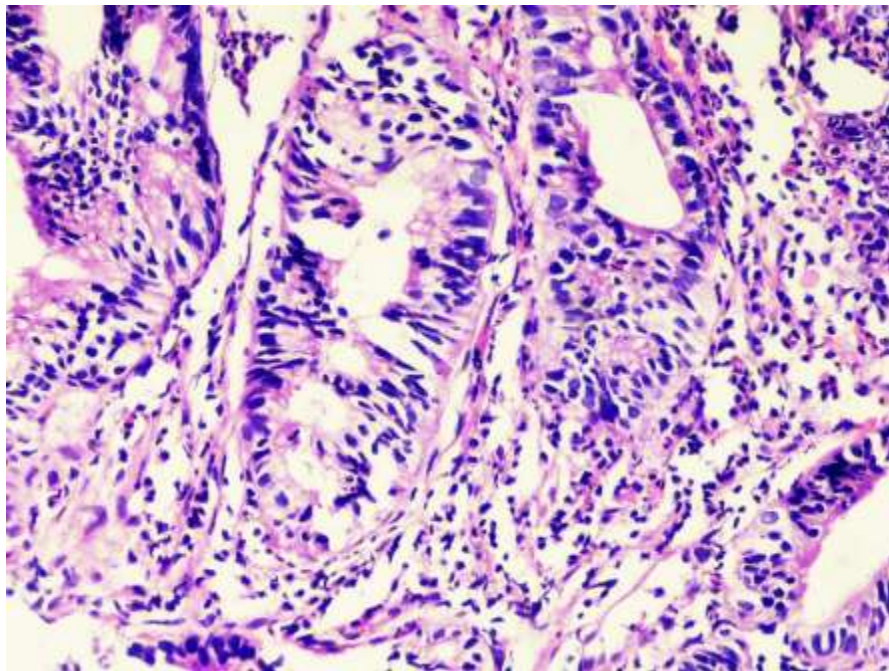
Table/fig 9:- a:MRCP demonstrates amputated the common hepatic duct at the confluence site of both hepatic ducts being totally obstructed for a short segment. Secondary dilatation of the intra hepatic biliary radicles of both hepatic lobes is noted, much more prominent **on the left lobe**



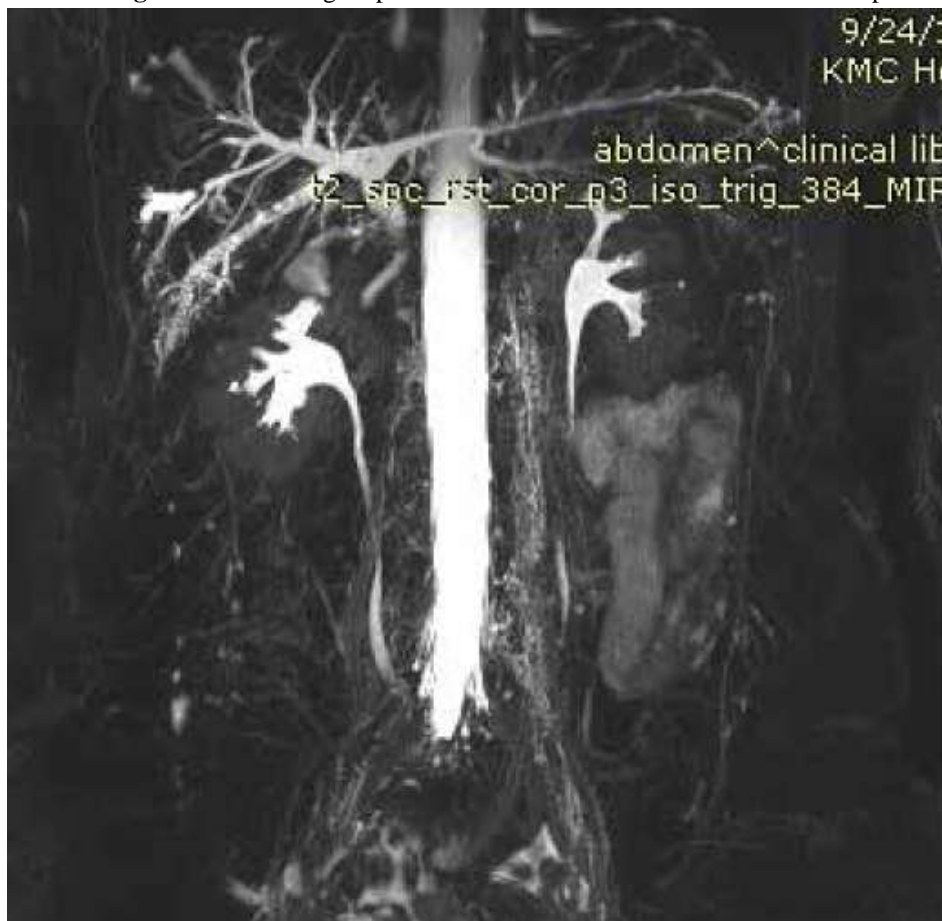
b: ERCP reveals hilar stricture and undergone biliary sphincterotomy and stent placement



c: Histopathological examination reveals moderately differentiated adenocarcinoma showing ill formed glands



Table/fig 10: MRCP image reported as mid CBD stricture. No stricture was present in ERCP.



References:-

1. Safari, M. T., Miri, M. B., Ebadi, S., Shahrokh, S., & Alizadeh, A. H. M. (2016). Comparing the Roles of EUS, ERCP and MRCP in Idiopathic Acute Recurrent Pancreatitis. *Clinical Medicine Insights. Gastroenterology*, 9, 35–39. <http://doi.org/10.4137/CGast.S37927>
2. Attri A, Galhotra RD, Ahluwalia A, Saggar K. Obstructive jaundice: Its etiological spectrum and radiological evaluation by magnetic resonance cholangiopancreatography. *Med J DY Patil Univ* 2016;9:443-50
3. Polistina FA, Frego M, Bisello M, Manzi E, Vardanega A, Perin B. (2015) Accuracy of magnetic resonance cholangiography compared to operative endoscopy in detecting biliary stones, a single center experience and review of literature. *World J Radiol*; 7(4): 70-78
4. SuthaR M, PuRohit S, BhaRgaV V, Goyal P. (2015 Nov) Role of MRCP in differentiation of benign and malignant causes of biliary obstruction. *Journal of clinical and diagnostic research: JCDR*.;9(11):TC08.
5. Chen, W., Mo, J.-J., Lin, L., Li, C.-Q., & Zhang, J.-F. (2015). Diagnostic value of magnetic resonance cholangiopancreatography in choledocholithiasis. *World Journal of Gastroenterology: WJG*, 21(11), 3351–3360. <http://doi.org/10.3748/wjg.v21.i11.3351>.
6. Oto A, Ernst R, Ghulmiyyah L, Hughes D, Saade G, Chaljub G. (2014 Jan 28) The role of MR cholangiopancreatography in the evaluation of pregnant patients with acute pancreaticobiliary disease. *The British journal of radiology*.
7. Sohns JM, Staab W, Dabir D, Spiro JE, Bergau L, Schwarz A, Sohns C. (2014 Feb) Current role and future potential of magnetic resonance cholangiopancreatography with an emphasis on incidental findings. *Clinical imaging*. 28;38(1):35-41.
8. Sohns JM, Staab W, Dabir D, Spiro JE, Bergau L, Schwarz A, Sohns C. (2014 Feb) Current role and future potential of magnetic resonance cholangiopancreatography with an emphasis on incidental findings. *Clinical imaging*. 28;38(1):35-41
9. Mubarak Ali, Ishtiaq Ahmed, Amjad Sattar, Mirza Waseem Akhtar, Mujahid Hussain, Zaigham Abbas (Oct 2012) Diagnostic accuracy of magnetic resonance cholangio-pancreatography in evaluation of obstructive jaundice *JPakMedAssoc*;62(10):1053-6. Sindh Institute of Urology and Transplantation, Karachi.
10. Chang JH, Lee IS, Lim YS, Jung SH, Paik CN, Kim HK, Kim TH et al. (2012 Feb) Role of magnetic resonance cholangiopancreatography for choledocholithiasis: analysis of patients with negative MRCP. *Scandinavian journal of gastroenterology*. 1;47(2):217-24.
11. Chang JH, Lee IS, Lim YS, Jung SH, Paik CN, Kim HK, Kim TH et al. (2012 Feb) Role of magnetic resonance cholangiopancreatography for choledocholithiasis: analysis of patients with negative MRCP. *Scandinavian journal of gastroenterology*. 1;47(2):217-24.
12. Rahman R, Ju J, Shamma's J, Goebel S, Sundaram U. (2009 Dec) Correlation between MRCP and ERCP findings at a tertiary care hospital. *The West Virginia Medical Journal*.;106(5):14-9.
13. Rahman R, Ju J, Shamma's J, Goebel S, Sundaram U. Correlation between MRCP and ERCP findings at a tertiary care hospital. *The West Virginia Medical Journal*. 2009 Dec;106(5):14-9.
14. Sawhney R, Speer T (2009) Patients with a high probability of choledocholithiasis are best managed with ERCP without EUS. *Gastrointest Endosc* 69:982–983
15. Hurter D, De Vries C, Potgieter P, Barry R, Botha F, Joubert G. (2008 May) Accuracy of MRCP compared to ERCP in the diagnosis of bile duct disorders. *SA Journal of Radiology*. 3;12(1):14-22.
16. Hurter D, Chb MB, Potgieter PH, Botha FJH. Accuracy of MRCP compared with ERCP in the diagnosis of bile duct disorders. *SA J Radiol*. 2008;(April) Romagnuolo J, Currie G (2005) Noninvasive vs. selective invasive biliary imaging for acute biliary pancreatitis: an economic evaluation by using decision tree analysis. *Gastrointest Endosc* 61:86–97
17. Halefoglu AM. (2007) Magnetic resonance cholangiopancreatography: a useful tool in the evaluation of pancreatic and biliary disorders. *World J Gastroenterol*; 13: 2529–34.
18. Hallal AH, Amortegui JD, Jeroukhimov IM, Casillas J, Schulman CI, Manning RJ, Habib FA, Lopez PP, Cohn SM, Sleeman D. (2005 Jun 30) Magnetic resonance cholangiopancreatography accurately detects common bile duct stones in resolving gallstone pancreatitis. *Journal of the American College of Surgeons*.;200(6):869-75.
19. Kaltenthaler E, Bravo Vergel Y, Chilcott J, Thomas S, Blakeborough T, Walters SJ et al. (2004); A systematic review and economic evaluation of magnetic resonance cholangiopancreatography compared with diagnostic endoscopic retrograde cholangiopancreatography. *Health Technol Assess* 8(10).
20. Ward J, Sheridan MB, Guthrie JA, Davies MH, Millson CE, Lodge JP et al. (2004 Apr) Bile Duct Strictures after Hepatobiliary Surgery: Assessment with MR Cholangiography 1. *Radiology*.;231(1):101-8.

21. Munir K, Bari V, Yaqoob J, Khan DB, Usman MU. (2004 Mar) The role of magnetic resonance cholangiopancreatography (MRCP) in obstructive jaundice. *journal-pakistan medical association*.;54(3):128-32.
22. Topal B, Van de Moortel M, Fieuws S, Vanbeckevoort D, Van Steenberghe W, Aerts R, Penninckx F. (2003 Jan) The value of magnetic resonance cholangiopancreatography in predicting common bile duct stones in patients with gallstone disease. *British journal of surgery*. 1;90(1):42-7.
23. Kats J, Kraai M, Dijkstra AJ, Koster K, Ter Borg F, Hazenberg HJ, Eeftinck Schattenkerk M, Ziedses des Planters BG, Eddes EH (2003 Mar 17). Magnetic resonance cholangiopancreatography as a diagnostic tool for common bile duct stones. *Digestive surgery*.;20(1):32-7.
24. Kats J, Kraai M, Dijkstra AJ et al. (2003) Magnetic resonance cholangiopancreatography as a diagnostic tool for common bile ducts. *Dig Surg*; 20: 32–7.
25. Taylor AC, Little AF, Hennessy OF, Banting SW, Smith PJ, Desmond PV. (2002 Jan) Prospective assessment of magnetic resonance cholangiopancreatography for noninvasive imaging of the biliary tree. *Gastrointestinal endoscopy*. 31;55(1):17-22.
26. Hussein, F. M., Alsumait, B., Aman, S., Sinan, T., Alkandari, K., Hniya, M. H. d. and Alsaeed, O. (2002), Diagnosis of choledocholithiasis and bile duct stenosis by magnetic resonance cholangiogram. *Australasian Radiology*, 46: 41–46. doi: 10.1046/j.1440-1673.2001.00992.
27. Lopez Hänninen, Enrique, et al. (2002) "Prospective Evaluation of Pancreatic Tumors: Accuracy of MR Imaging with MR Cholangiopancreatography and MR Angiography 1." *Radiology* 224.1: 34-41.
28. Kim, Joo Hee, et al. (2002) "MR Cholangiography in Symptomatic Gallstones: Diagnostic Accuracy according to Clinical Risk Group 1." *Radiology* 224.2: 410-416.
29. Capelastegi A. Role of magnetic resonance cholangiopancreatography in patients with suspected choledocholithiasis. In *Mayo Clinic Proceedings* 2002 May 31 (Vol. 77, No. 5, pp. 422-428). Elsevier.
30. Millat B, Decker G, Fingerhut A (2001) Imaging of cholelithiasis: what does the surgeon need? *Abdom Imaging* 26:3–6
31. Vitellas KM, Keogan MT, Spritzer CE, Nelson RC. (2000 Jul)MR Cholangiopancreatography of Bile and Pancreatic Duct Abnormalities with Emphasis on the Single-Shot Fast Spin-Echo Technique 1. *Radiographics*.;20(4):939-57.
32. Demartines N, Eisner L, Schnabel K, Fried R, Zuber M, Harder F. (2000 Feb) Evaluation of magnetic resonance cholangiography in the management of bile duct stones. *Archives of Surgery*. 1;135(2):148-52 Sica GT, Braver J, Cooney MJ, Miller FH, Chai JL, Adams DF. Comparison of endoscopic retrograde cholangiopancreatography with MR cholangiopancreatography in patients with pancreatitis. *Radiology*. 1999 Mar;210(3):605-10
33. Magnuson TH, Bender JS, Duncan MD, Ahrendt SA, Harmon JW, Regan F. (1999 Jul)Utility of magnetic resonance cholangiography in the evaluation of biliary obstruction. *Journal of the American College of Surgeons*. 31;189(1):63-71..
34. Matos C, Nicaise N, Deviere J, Cassart M, Metens T, Struyven J et al. (1998) Choledochal cysts: comparison of findings at MR cholangiopancreatography and endoscopic retrograde cholangiopancreatography in eight patients. *Radiology*. Nov;209(2):443-8
35. Bearcroft, Philip W., and David J. Lomas. (1997) "Magnetic resonance cholangiopancreatography." *Gut* 41.2: 135-137
36. Bilbao MK, Dotter CT, Lee TG, Katon RM. (1976)Complications of endoscopic retrograde cholangiopancreatography (ERCP). *Gastroenterology*. Mar 1;70(3):314-20.