



ISSN NO. 2320-5407

Journal homepage: <http://www.journalijar.com>

INTERNATIONAL JOURNAL
OF ADVANCED RESEARCH

RESEARCH ARTICLE

Efficient Detection of severity of Diabetic Retinopathy using DIP

Shivananda¹, Dr.Girish.A.Attimarad²

1. PhD Scholar, Dept. of E&C, Singhania University, Rajasthan, India

2. Professor, Dept. of E&C, DSCE, Bangalore, India

Manuscript Info

Manuscript History:

Received: 14 November 2015

Final Accepted: 22 December 2015

Published Online: January 2016

Key words:

Diabetic retinopathy (DR), microaneurysms(MAs), morphological processing, digital image processing(DIP), disease severity.

*Corresponding Author

Shivananda.

Abstract

Abstract--- Diabetes is a rapidly increasing worldwide problem which is characterized by defective metabolism of glucose that causes long-term disorders and failure of various organs of human body. Diabetic Retinopathy (DR) is a most common complication of diabetes. Nowadays it is the primary causes of blindness and visual impairment in adults. This can be prevented if diagnosed and treated in its early stages by detecting the microaneurysms(MAs) and Exudates in the retina of the diabetic patient. The proposed work develops an efficient system for ophthalmologist to analyze the MAs and exudates. The abnormalities in the captured color fundus image is detected using digital image processing(DIP)techniques by applying morphological and other signal processing operations. The extracted features are used to detect the severity of DR with accuracy of 94%.

Copy Right, IJAR, 2016., All rights reserved.

Introduction:-

Diabetes is a chronic disease caused by insufficient insulin being produced by the pancreas or by the ineffectiveness of the insulin produce. In recent years, diabetes has reached worldwide epidemic proportions. The World Health Organization attributes the increased occurrence of the disease to lifestyle and economic change. Diabetic Retinopathy (DR) is a general term for all disorders of the retina caused by diabetes. Fig.1 shows the symptoms of diabetic retinopathy. DR typically begins as small changes in the retinal capillaries. The smallest detectable abnormalities, microaneurysms (MA), appear as small red dots in the retina and are local distensions of the weakened retinal capillary. Due to these damaged capillary walls, the small blood vessels may rupture and cause intraretinal haemorrhages (HA). In the retina, the haemorrhages appear either as small red dots indistinguishable from microaneurysms or larger round-shaped blots with irregular outline. The diabetic retinopathy also increases the permeability of the capillary walls which results in retinal oedema and hard exudates (HE). The hard exudates are lipid formations leaking from the weakened blood vessels and appear yellowish with well defined borders. If the local capillary circulation and oxygen support fail due to obstructed blood vessels, pale areas with indistinct margins appear in the retina. These areas are small microinfarcts known as soft exudates(SE).




Fig.1: Symptoms of diabetic retinopathy
 (a) MAs (b) Haemorrhages (c) Hard exudates (d) Soft exudates

Literature survey:-

V.Vijayakumari and N.Suriyanarayanan et al. [1] uses mathematical morphology for extracting exudates, optic disk and blood vessels. Here morphological opening and closing operations of different sizes are used to detect hard exudates, but one of the main drawbacks of morphological operation is the size of structuring element suitable for one image is not be suitable for another image. Saiprasad Ravishankar et al [2] also uses mathematical morphology to detect hard exudates but it uses a linear classifier for classifying the patches based on their edge strength. Hussain F.Jaafar et al [3] introduced a pure splitting technique for detection of exudates in retinal images. This technique uses an adaptive thresholding based on a novel algorithm for pure splitting of the image. S.Kavitha et al [4] uses mathematical morphology and pure splitting technique to detect faint exudates. SOPharak et al [5] used a Naïve Bayes classifier to detect exudates. The main drawback of Navie Bayes classifier is it misses the faint exudates. R.Vijayamadheswaran et al [6] proposed detection of exudates using a combination of contextual clustering and Radial basis function. In this technique all the fundus images are transformed to a standard template image condition. Detection of exudates is accurate when the fundus images are captured with good quality. Garcia et al [7] detects Hard exudates using neural network (NN) approach. Here three NN classifiers were investigated which includes multilayer perceptron (MLP), radial basis function (RBF) and support vector machine(SVM). Vallabha et al in their work titled "Automated detection and classification of vascular abnormalities in diabetic retinopathy"[20] applied the use of scale and orientation of selective Gabor filter to detect and classify the retina images into mild or severe case.

System methodology:-

The proposed system automatically detects the blood vessels, microaneurysm, haemorrhages and hard exudates of the input fundus image and classify the result into either normal or DR case. Fig. 2 shows the block diagram of the proposed system.

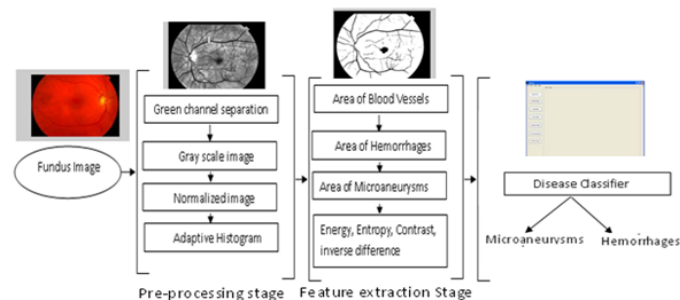


Fig. 2: Proposed system

Eye fundus photography is the preferred diagnostic modality because it is reliable, non-invasive and easy to use. In contrast to traditional ophthalmoscopy, it allows to record diagnostic data and enable the expert consultation afterwards, and more importantly the eye fundus photography results in a better sensitivity rate, that is, a better detection rate of abnormal eye funduses. In case of DR diagnosis the strong recommendation is to take both colour image and red-free eye images, where two images are captured by focusing the 45deg field-of-view fundus camera to macula and optic disc.

For long-term diabetic patients, two-field 60deg photography is recommended since the neovascular changes that need treatment are typically found in the periphery, even if the changes in the central areas of the retina are slight.

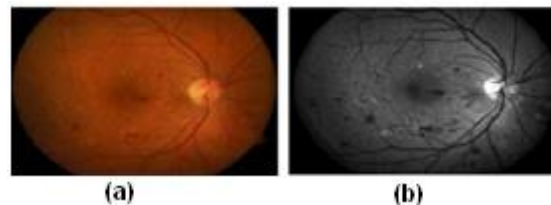


Fig. 3: (a) colour image of an eye fundus (b) corresponding red-free image

Pre-processing stage is considered as the backbone of this research work. In detecting the abnormalities associated with fundus image, the images have to pre-processed in order to correct the problems of uneven illumination problem, nonsufficient contrast between exudates and image background pixels and presence of noise in the input fundus image. This stage is also responsible for colour space conversion and image size standardization for the system. Pre-processing is also very much necessary for the reliable extraction of features and abnormalities as feature extraction and detection grading algorithms give poor results in the presence of noisy background.

In the RGB images, the green channel exhibits the best contrast between the vessels and background while the red and blue ones tend to be more noise. Hence green channel is used for further processing. In next step the green channel image is converted into a gray scale image, as the retinal blood vessels appear darker in the gray image. All the features like blood vessels, MAs etc. are hidden in the background and are not clearly visible. Normalization and contrast enhancement is performed to improve the image quality. A Median filter is used to remove the noisy pixels appears with the background information. One of the problems associated with fundus images is uneven illumination. Some areas of the fundus images appear to be brighter than the other. Areas at the centre of the image are always well illuminated, hence appears very bright while the sides at the edges or far away are poorly illuminated and appears to be very dark. In our research work Naka Rushton method and Adaptive histogram equalisation method (AHEM) are used. AHEM gives better performance, higher processing speed and work well for all images of different sizes.

$$P_n = 255 \cdot \left(\frac{[\phi_w(p) - \phi_w(Min)]}{[\phi_w(Max) - \phi_w(Min)]} \right) \quad (1)$$

where,

$$\phi_w(p) = \left[1 + \exp\left(\frac{\mu_w - p}{\sigma_w}\right) \right]^{-1} \quad (2)$$

Max and *Min* are the maximum and minimum intensity values in the whole image while μ_w and σ_w indicate the local window mean and standard deviation.

The main objective of segmentation is to group the image into regions with same property or characteristics. It plays a major role in image analysis system by facilitating the description of anatomical structures and other regions of interest. In this research, segmentation by K-means with two non-overlapping classes are found to be better than segmentation by simple thresholding. Background and noisy pixels were segmented into one class and the fundus image features which consist of the spots, exudates veins etc. were segmented into another class without any pixel belonging into two classes.

Detection of Optic Disk:-

The optic disk is the visible part of the optic nerve head within the retina and it is generally brighter than the surrounding area with an elliptical contour. Many vessels crossing the optic disk can be typically seen in fundus images. Optic Disk Localization (ODL) necessary to differentiate the disk from other features of the retina like exudates, blood vessel etc. It consists mainly of finding the approximate center of the optic disk or placing the disk within a specific region such as a circle or square. In our research work characteristics of the optic disk like intensity, morphology and color for ODL are used. An 80X80 pixel sub-image is used to evaluate the intensity variance of adjacent pixels. The point with the largest variance was assumed to be centre of the optic disk. Two stage processes for optic disk segmentation is used. First template matching for ODL is performed and after that a

specialized three phase elliptical global and local deformable model with variable edge-strength dependent stiffness was then fitted to the contour of the disk.

Detection of Blood vessels:-

Accurate segmentation of the retinal blood vessels is very essential prerequisite step in the identification of the retinal anatomy and pathology. A green channel image is processed with image segmentation and combined with the mask layer. These two images are compared and the differences are removed. The obtained image would represent the blood vessels of the original image.

Detection of Exudates:-

Exudates appeared as bright yellow-white deposits on the retina due to the leakage of blood from abnormal vessels. Their shape and size will vary with the different DR stages. The grayscale image is first preprocessed and a K-nearest neighbors algorithm, together with a static classifier combination scheme, has been used to determine whether a retinal image contains exudates. The exudates are detected after removing the border, optical disk and non-exudates area.

Detection of Microaneurysms:-

MAs appeared as small dark round dots (~15 to 60microns in diameter) on the fundus images. They are small bulges developed from the weak blood vessels and are the earliest clinical sign of diabetic retinopathy. Hence, it is essential to detect them during the mild stage. The number of MAs would increase with the stage of the retinopathy. Morphological processing algorithms are the most commonly used algorithms. A spot lesion detection algorithm using multiscale morphological processing is used to detect sensitive MAs.

The feature vector used for classification stage consists of following important features obtained from feature extraction and image segmentation stage. The extracted features are as follows:

- i) **Area of blood vessels** (finding the total number of white (vessel) pixels in the blood vessel segmented image).
- ii) **Area of exudates** (finding the total number of white pixels in the exudates segmented image).
- iii) **Area of MA** (finding the total number of white pixels in the MA segmented image).
- iv) **Contrast** (measure of the intensity contrast between a pixel and its neighbor over the whole image).
- v) **Homogeneity** (measures the closeness of the distribution of elements to the diagonal)
- vi) **Correlation** (linear dependency of the gray level values in the co-occurrence matrix)
- vii) **Energy** (sum of squared elements in the co-occurrence matrix).

The extracted feature values will have different ranges of values. Therefore it is necessary to normalize the values to an acceptable range.

Classification:-

SMO (Sequential Minimal Optimization) classifier: SMO is a new SVM learning algorithm which is conceptually simple, easy to implement, often faster and has better scaling properties than a standard SVM algorithm.

At every step, SMO chooses two Lagrange multipliers to jointly optimize, finds the optimal values for these multipliers and updates the SVM to reflect the new optimal values. The advantage of SMO lies in the fact that solving for two Lagrange multipliers can be done analytically. An entire inner iteration due to numerical QP optimization is avoided. In addition SMO does not require extra matrix storage (to store previous $\alpha_1\alpha_2$ and current $\alpha_1\alpha_2$, we only need $2*2$ matrices). Therefore, very large SVM training problems can fit inside of the memory of a personal computer.

The two Lagrange multipliers must fulfill all of the constraints of the full problem. The inequality constraints cause the Lagrange multipliers to lie in the box (Figure 2). Therefore, one step of SMO must find an optimum of the objective function on a diagonal line segment. In figure2, $\gamma = \alpha_1(old) + s\alpha_2(old)$, is a constant that depends on the previous value of α_1 and α_2 , $s = y_1*y_2$.

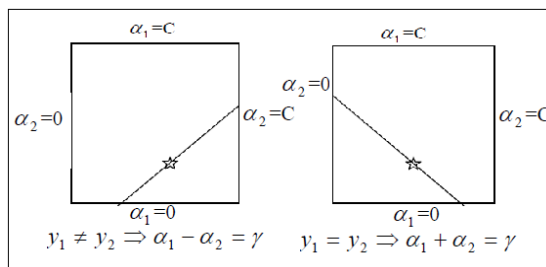


Fig. 4: Constraints for Lagrange multiplier

Experimental results and discussion:-In our research work, for training, 70 images (35 normal and 35 DR images) and for testing, 170 images (85 normal images and 85 DR images) are used and their features are extracted. Then these features are used by the SMO classifier to classify the input images into Normal and DR (MA/Exudates) images. The implementation and testing of this work is carried out using MATLAB.

Detection of Blood vessels:-

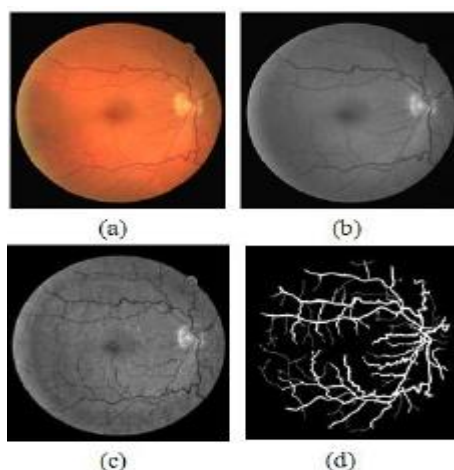


Fig. 5: (a)Original image (b)Green channel image (c)Pre-processed image (d)Detected blood vessels

Detection of Exudates:-

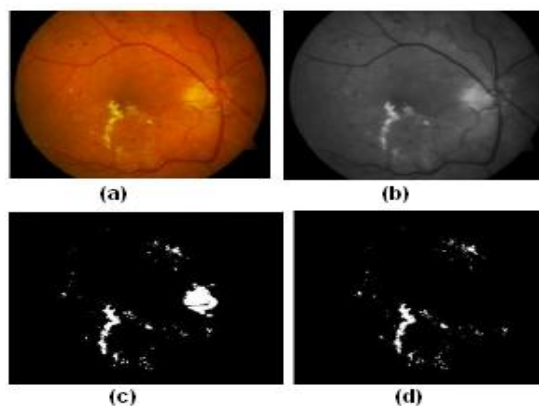


Fig. 6: (a)Original image (b) Pre-processed image (c) Optic disk and exudates (d) Detected Exudates

Detection of Microaneurysms:-

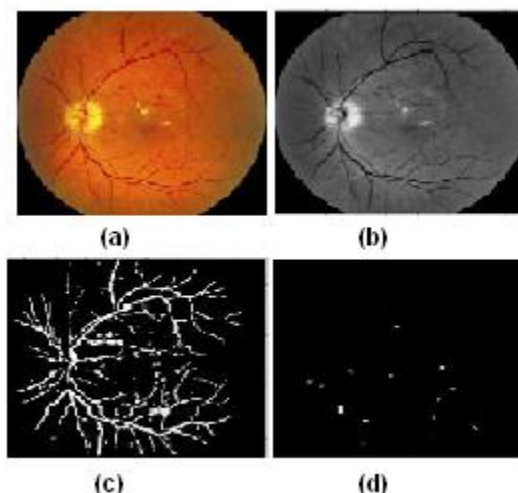


Fig. 7: (a)Original image (b) Pre-processed image (c)Blood vessels and MAs (d) Detected MAs

Table. 1 shows the results of accuracy of the proposed system.

Case of Classification	No. of Training	No. of Testing	No.of correctly classified	Accuracy of the classification method
DR (MA/Exudates)	35	85	81	96%
Normal	35	85	78	92%
Average Accuracy of the system				94%

Table. 1: Details of accuracy of the system

Conclusion:-

In our research work the digital image processing techniques like pre-processing, image segmentation and feature extraction are applied to publicly available retinal fundus image databases like **STARE**(Structured Analysis of Retina), **DRIVE**(Digital Retinal Images for Vessel Extraction) and also images provide by **NETHRA** Hospital, Bangalore. The extracted features are used to train the SMO classifier which provides average classification accuracy as 94%.

References:-

- [1] Vijaya Kumari, N. Suriyanarayanan, C.Thanka Saranya , “A Feature Extraction for Early Detection of Diabetic” International Conference on Recent Trends in Information Telecommunication and Computing, pp. 359 – 361, 2010.
- [2] Saiprasad Ravishankar, Arpit Jain, Anurag Mittal “Automatic Feature Extraction for Detection of Diabetic Retinopathy in Fundus Images”, International Conference on Computer Vision and Pattern Recognition, pp. 210-217, 2009.
- [3] Hussain F. Jaafar, Asoke K. Nandi and Waleed Aluy “Detection of Exudates in Retinal Images Using Pure Splitting Technique” 3rd Annual International Conference of the IEEE EMBS Buenos Aires, Argentina, pp. 6745 - 6748, 2010.
- [4] S. Kavitha, K. Duraiswamy, A. R. S. Sr Supreetha “Detection of Exudates and macula in fundus images to estimate severity of Diabetic Retinopathy” International Journal of Communications and Engineering Vol.7, Issue: 01, pp. 24-29, March 2012.
- [5] Sopharak, Akara, Dailey, Matthew N., Uyyanonvara, Bunyarit, Barman, Sarah, Williamson, Tom, Nwe, Khine Thet and Moe, Yin Aye, “ Machine learning approach to automatic exudates detection in retinal images from Diabetic Patients” Journal of Modern Optics, Vol. 5, Issue 2, pp. 124-135, 2010.
- [6] R. Vijayamadhewaran, Dr. M. Arthanari, Mr. M. Sivakumar, “Detection of Diabetic Retinopathy using RLS Function” International journal of Innovative technology & creative Engineering, Vol.1, pp. 41-47, January 2011.

- [7] María García, Clara I. Sánchez, María I. López, Daniel Abásolo, and Roberto Hornero “Neural Network based detection of Hard Exudates in Retinal Images”, *Computer Methods and Programs in Biomedicine*, Vol.93, Issue 1, pp. 9-19, January 2009.
- [8] Tomi Kauppi, Valentina Kalesnykiene, Joni-Kristian Kamarainen, Lasse Lensu, Iris Sorri, Asta Raninen, Raija Voutilainen, Hannu Uusitalo, Heikki Vessanen, and Juhani Pietiläinen “DI RETDB1 Diabetic Retinopathy database and evaluation protocol” Technical report, Faculty of medicine, University of Kuopio, Finland, 2007.
- [9] Ardimas Andi Purwita, Kresno Adityowibowo, Ashlih Dameitry, Made Widhi surya Atman, “Automated Microaneurysm Detection using Mathematical Morphology”, *International Conference on Instrumentation, Communication, Information Technology and Biomedical Engineering*, pp. 117 – 120, November 2011.
- [10] Dr.H.B. Kekre, Tanuja. K. Sarode Suchitra M. Patil, “2D Image Morphing With Wrapping Using Vector Quantization Based Colour Transition” *International Journal of Computer Science and Information Security*, Vol. 9, No. 7, pp. 75-82, 2011.
- [11] Xiaohou Zhang and Opas Chutape. “A SVM approach for detection of hemorrhages in background diabetic retinopathy”. In *Proceedings of International Joint Conference on Neural Networks*, pages 2435–2440, Montreal and Canada, July 2005.
- [12] John Attia “Moving Beyond Sensitivity And Specificity: Using Likelihood Ratios To Help Interpret Diagnostic Tests”. *Prescriber*, Vol.26, No.5, pp. 111-113, 2003.
- [13] Conference Report: Screening for Diabetic Retinopathy in Europe 15 years after the St. Vincent declaration the Liverpool Declaration 2005. Retrieved March 18, 2006, from
- [14] Abate Diabetes: Diabetes. Accessed March 21, 2006, from Website: <http://www.abatediabetes.com/diabetes.html>
- [15] SightSavers: The structure of the human eye. Accessed, August 2, 2006, from website: http://www.sightwavers.or.uk/html/eyeconditions/huma_eye_detailed.htm
- [16] My Eye World: Eye Structure and function. Referenced, August 2nd 2006, website http://www.myeyeworld.com/files/eye_structure.htm
- [17] St. LukesEye.Com: Eye Anatomy. Accessed August 2nd 2006, from website <http://www.stlukeseye.com/anatomy/Retina.asp>
- [18] Junichiro Hayashi, Takamitsu Kunieda, Joshua Cole, Ryusuke Soga, Yuji Hatanaka, Miao Lu, Takeshi Hara and Hiroshi Fujita: A development of computer-aided diagnosis system using fundus images. *Proceeding of the 7th International Conference on Virtual Systems and MultiMedia (VSMM 2001)*, pp. 429-438 (2001).
- [19] Jianxin Wu ,”Efficient HIK SVM Learning for Image Classification”, *IEEE TRANSACTIONS ON IMAGE PROCESSING*, VOL. 21, NO. 10, OCTOBER 2012
- [20] Vallabha,D., Dorairaj, R., Namuduri K. R., and Thompson, H., "Automated Detection and Classification of Vascular Abnormalities in Diabetic Retinopathy", 38th Asilomar Conference on Signals, Systems and Computers, November 2004.
- [21] Rafael C. Gonzalez and Richard E. Woods. ‘Digital Image Processing using MATLAB’, 2nd edition. Prentice Hall, 2002. ISBN 0-201-18075-8.

