



RESEARCH ARTICLE

The effect of expose the rat testis to low level laser light on changing serum LH and testosterone levels

Ahmed Saed Al-Ebady

College of Vet. Med. / University of Al-Qadisiya-Iraq

Manuscript Info

Manuscript History:

Received: 29 October 2014

Final Accepted: 23 November 2014

Published Online: December 2014

Key words:

luteinizing hormone, testosterone, testis, low level laser light.

*Corresponding Author

Ahmed Saed Al-Ebady

Abstract

In order to investigate the effect of low level laser light on changing serum LH (luteinizing hormone) and T (testosterone) levels, 24 male rats have 6 weeks of age, weighing about 200g of each were divided randomly into 3 groups, 8 rats for each. Group I was exposed to 4 joules/cm²/day (50 mW × 10 sec), and group II was exposed to 12 joules/cm²/ day (50 mW × 30 sec) of laser light by 660nm wave length probe for five days. Group III was used as control. At the sixth day, the serum LH and T levels were measured and the right testes were taken for histopathological examination. The results showed that there was significant (P<0.05) decrease in serum LH level in group II when compared with group I and control, while serum T levels were not significantly higher between groups, and there was clear histopathological changes in right testes seminiferous tubules of group II which exposed to 12 joules of laser light.

Copy Right, IJAR, 2014,. All rights reserved

INTRODUCTION

Spermatogenesis regulated by the release of LH and FSH which synthesized and secreted from the pituitary gland. Then, LH stimulate the syntheses and release of testosterone from the Leydig cells of the testis. A sequent of events controls the pituitary-testicular stimulation and testicular negative feed back. Pituitary gonadotrophs were regulated by both steroid testosterone and non steroid inhibin [1], and the peripheral blood levels of LH and T are consider the signals that regulates the hypothalamic-pituitary-testicular functions [2].

For more than 10 years, the low level laser light have been used as physical treatment in variety of medical applications. Applications such as treatment of injuries in both chronic and acute conditions [3,4], that may occur due to enhancing of neovascularisation, promoting of angiogenesis and increasing collagen synthesis to promote healing. Low level laser light also can stimulate healing of deeper structures such as nerves, tendons, bones and internal organs [5-8], furthermore, low level laser light can reduce pain and inflammation [9,10].

The photons of the laser light are absorbed by electronic absorption bands belonging to some molecular photoacceptors, or chromophores [11]. It has been documented that the cytochrome c which found in mitochondrial respiratory chain is the primary photoacceptor for the red-near infrared laser light range in mammalian cells, and the mechanism action of phototherapy is characterized by its ability to induce photobiological processes in cells, that when the light is absorbed, the cytochrome c is excited and bond with the oxygen to become cytochrome c oxidase (Cox) which is necessary to the formation of ATP, and the ATP is important for energy production in the cell which leads to many biological responses or secondary mechanisms related [12]. The range of low level laser light almost occur between (600 to 1100 nm) [13].

This study was conducted to investigate the effect of expose the rat testis to low level laser light in determining the levels of serum LH and T, and the histopathological changes that may occur in seminiferous tubules due to expose the testis to two different doses of low level laser light with the same wave length.

Materials and methods:

24 albino male rats about 6 weeks of age weighing around 200 g for each were divided randomly into 3 groups, 8 rats for each.

Group I, the right testis of every male were exposed by 660 nm probe to 4 joules of laser light in 50 mW intensity for 10 sec every day for five days.

Group II, the right testis of every male were exposed by 660 nm probe to 12 joules of laser light in 50 mW intensity for 30 sec every day for five days.

The rats were hold from the bag, and the probe were caught to be touch with the scrotum in a right angle with the middle of the testis.

Group III, used as control that the rats were placed daily on the operation table at the time of treatment without expose to any laser irradiation.

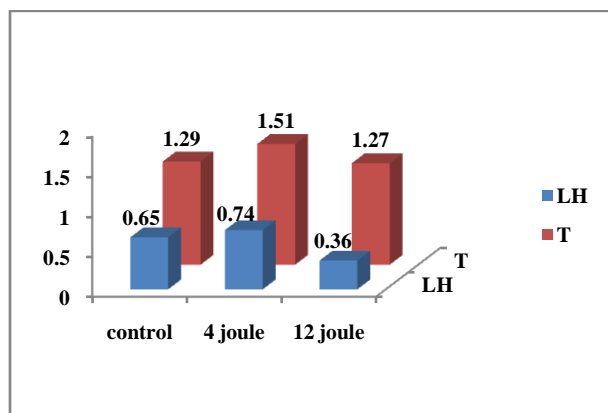
At the sixth day, the rats were killed and about 3 ml of blood were taken from the abdominal vein of each, and the serum was separated for investigation on LH and T levels. The right testes of each rat were taken in formalin for histopathological examination.

The laser apparatus used in this research was from Omega Laser System Limited-UK, and the LH, T tests were done by Minivedas (Biomerux).

Results:

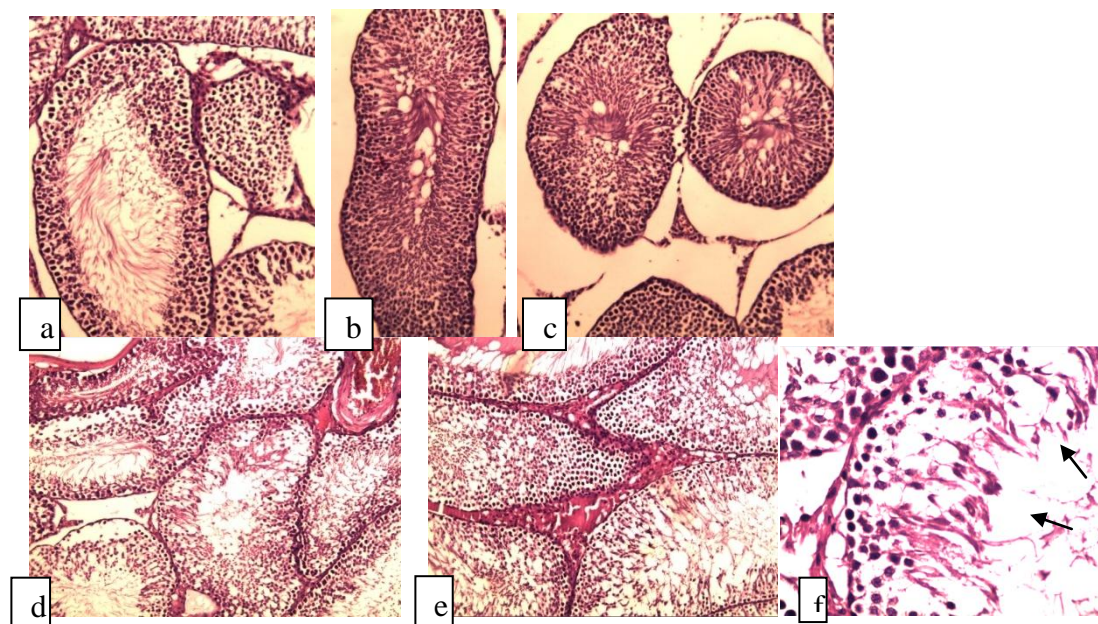
the mean serum LH and T levels for the first group was 0.740 ± 0.062 IU/ml and 1.51 ± 0.09 ng/ml respectively, and the second group was 0.368 ± 0.038 IU/ml and 1.27 ± 0.08 ng/ml, and the control group was 0.0655 ± 0.048 IU/ml and 1.29 ± 0.06 ng/ml.

The results which show in the following table and diagram are compare the differences of mean \pm SD between groups and the data were analyzed by ANOVA (analysis of variance) with SPSS version 13.



In histopathological examination of right testes that exposed to 4 joules of laser light, there were normal images of seminiferous tubular walls. The walls were compact and circulated with complete spermatogenesis and narrow or no lumen which filled with sperms, while in histopathological images of the right testes of group II which exposed to 12 joules of laser light there were vacuolation around spermatogonia within intercellular spaces of seminiferous tubules with degeneration of primary and secondary spermatocytes, and increase in the lumen of tubules with few sperms, also there was congestion and thrombosis in the interstitial tissue among the tubules.

Groups	LH (IU/ml) Mean \pm SD	T (ng/ml) Mean \pm SD
Control	0.655 ± 0.048 a	1.29 ± 0.06 a
Laser 4 Joules	0.740 ± 0.062 a	1.51 ± 0.09 a
Laser 12 Joules	0.368 ± 0.038 b	1.27 ± 0.08 a



histopathological examination of testis tissue stained with H & E day at 200x magnification. a- right testis, control. b and c- right testis exposed to 4 joules, notice the compact seminiferous tubule walls and complete spermatogenesis. d and e- right testis exposed to 12 joules, notice the vacuolation in seminiferous tubule walls and the congestion with thromboses in interstitial tissue. f- magnification of seminiferous tubule wall exposed to 12 joules, notice the degeneration of spermatocytes (arrows).

Discussion:

The results showed that there was no significant differences of serum LH and T levels between the control and group I which exposed to 4 joules of laser light, while in group II which exposed to 12 joules of laser light there was decrease in serum LH level with significant differences compared with control and group I levels, but there was no significant differences of T level compared with control and group I levels.

Positive and negative results were recorded after using low level laser light as a treatment in many reports, although the biochemical mechanisms of positive effects are still incompletely understood, those conflicting results were obtained after choosing different parameters in treatment such as different wave lengths, power density and treatment timing, but in general better effects were observed after treatment with low levels of laser light than using high levels [14,15]. Results of this study support the concept that better results were obtained after using lower levels of power density.

The results showed also, that there was significant decrease in serum LH level when expose the tests to 12 joules of laser light. Previous studies have been showed that cellular functions were altered when exposed to low level laser light, which may increase or decrease protein synthesis, membrane potential, binding affinities, neurotransmitter release, ATP synthesis [16], from the other hand, low level laser light may effect negatively or positively on the secretion of some endocrine glands such as thyroid gland and pancreatic islets [17,18], but there are no known mechanisms by which this actions occur.

Many researches indicated that reactive oxygen species (ROS) generated during expose the cells to low level laser light [19-21]. ROS form as a natural by-product of the normal metabolism of oxygen and have important roles in cell signaling [22], regulating nucleic acid synthesis, protein synthesis, enzyme activation and cell cycle progression [23]. Nitric oxide (NO) is one of the ROS which dissociate from its binding sites on the heme iron and copper centers after expose the cells to low level laser light [24]. NO can be either protective or harmful depending on the dose of light, which is possible that NO released in low amounts of low dose light may be beneficial, while high levels released by high dose of light may be deleterious [25,26].

We have been proposed in the introduction that the Cox in mitochondrial respiratory chain is important in the formation of ATP. Brown [27] mention that NO which produced in mitochondria can inhibit respiration by binding to Cox and competitively displacing oxygen, especially in stressed or hypoxic cells, which means that NO inhibit oxygen binding thereby reduce necessary enzymic activity. There is evidence that NO involve in the regulation of hypothalamic-pituitary-adrenal and gonadal axis functions [28], and the effect of increase NO on pituitary were

reported decrease LH secretion [29,30]. Results of Adams et al. [31] have been showed decrease in serum LH concentrations after systemic injection to male rats by L arginine methyl ester, which is one of the most known experimentally used NO donors.

Conclusion:

Results of the study indicate that expose the rat testes to higher joules of laser light within the range of low level laser light waves, effects negatively on both serum LH levels, and the histo-image of seminiferous tubules and the interstitial tissue of the testes.

References:

- 1-Fafioffe, A.; Ethier, J.F.; Fon taine, J. and Jeanpierre et al., (2004). Activin and inhibin receptor gene expression in the ewe pituitary throughout the oestrous cycle. *J. Endocrinol.* 182, 55-68.
- 2-Stanfield, C. and German, W. (2009). *Principles of Human Physiology*. San Francisco: Pearson Benjamin Cummings.
- 3-Yu W.; Naim J.O. and Lanzafame R.J.(1997). Effects of photostimulation on wound healing in diabetic mice. *Lasers Surg Med.* 20:56–63.
- 4-Hopkins J.T.; McLoda T.A.; Seegmiller J.G.; David Baxter G. (2004). Low-level laser therapy facilitates superficial wound healing in humans: a triple-blind, sham-controlled study. *J Athl Train.* 39:223–229.
- 5-Gigo-Benato D.; Geuna S.; de Castro Rodrigues A.; Tos P.; Fornaro M.; Boux E.; Battiston B. and Giacobini-Robecchi M.G.(2004). Low-power laser biostimulation enhances nerve repair after end-to-side neurorrhaphy: a double-blind randomized study in the rat median nerve model. *Lasers Med Sci.*19:57–65.
- 6-Fillipin L.I.; Mauriz J.L.; Vedovelli K.; Moreira A.J.; Zettler C.G.; Lech O.; Marroni N.P. and Gonzalez-Gallego J. (2005). Low-level laser therapy (LLLT) prevents oxidative stress and reduces fibrosis in rat traumatized Achilles tendon. *Lasers Surg Med.* 37:293–300.
- 7-Weber J.B.; Pinheiro A.L.; de Oliveira M.G.; Oliveira F.A. and Ramalho L.M.(2006). Laser therapy improves healing of bone defects submitted to autologous bone graft. *Photomed Laser Surg.* 24:38–44.
- 8-Shao X.H.; Yang Y.P.; Dai J.; Wu J.F. and Bo A.H.(2005). Effects of He-Ne laser irradiation on chronic atrophic gastritis in rats. *World J. Gastroenterol.* 11:3958–61.
- 9-Bjoridal J.M.; Johnson M.I.; Iversen V.; Aimbire F. and Lopes-Martins R.A.(2006a). Photoradiation in acute pain: a systematic review of possible mechanisms of action and clinical effects in randomized placebo-controlled trials. *Photomed Laser Surg.* 24:158–68.
- 10-Bjoridal J.M.; Lopes-Martins R.A. and Iversen V.V.(2006b). A randomized, placebo controlled trial of low level laser therapy for activated Achilles tendinitis with microdialysis measurement of peritendinous prostaglandin E2 concentrations. *Br J Sports Med.* 40:76–80.
- 11-Sutherland J.C. (2002). Biological effects of polychromatic light. *Photochem Photobiol.* 76:164–70.
- 12-Karu T.I. and Kolyakov S.F.(2005). Exact action spectra for cellular responses relevant to phototherapy. *Photomed Laser Surg.* 23:355–61.
- 13-Karu T.I. and Afanas'eva N.I.(1995). Cytochrome c oxidase as the primary photoacceptor upon laser exposure of cultured cells to visible and near IR-range light. *Dokl Akad Nauk.* 342:693–5.
- 14-Bjoridal J.M.; Coupe C.; Chow R.T.; Tuner J. and Ljunggren E.A.(2003) A systematic review of low level laser therapy with location-specific doses for pain from chronic joint disorders. *Aust J Physiother.* 49:107–16.
- 15-Tumilty S.; Munn J.; McDonough S.; Hurley D.A.; Basford J.R. and Baxter G.D.(2009). Low Level Laser Treatment of Tendinopathy: A Systematic Review with Meta-analysis. *Photomed Laser Surg.*
- 16- Karu T.I.(1988). Molecular mechanism of low-intensity laser radiation. *Lasers Life Sci.* 2: 53-74.
- 17-Azevedo L.H.; Aranha A.C.; Stolf S.F.; Eduardo C.D. and Vieira M.M.F. (2005). Evaluation of low intensity laser effects on the thyroid gland of male mice. *Photomedicine and laser surgery.* 23: 567-570.
- 18-Irani S.; Monfared S.S.M.S.; Akbari-Kamrani M.; Abdollahi M.; Larijani B.(2009). Effect of low-level laser irradiation on in vitro function of pancreatic islets. *Transplantation Proceedings.* 41: 4313-4315.
- 19-Alexandratou E.; Yova D.; Handris P.; Kletsas D. and Loukas S.(2002). Human fibroblast alterations induced by low power laser irradiation at the single cell level using confocal microscopy. *Photochem Photobiol Sci.* 1:547–52.
- 20-Lubart R.; Eichler M.; Lavi R.; Friedman H. and Shainberg A.(2005). Low-energy laser irradiation promotes cellular redox activity. *Photomed Laser Surg.* 23:3–9.
- 21-Pal G.; Dutta A.; Mitra K.; Grace M.S.; Romanczyk T.B.; Wu X.; Chakrabarti K.; Anders J.; Gorman E.; Waynant R.W. and Tata D.B.(2007). Effect of low intensity laser interaction with human skin fibroblast cells using fiber-optic nano-probes. *J Photochem Photobiol B.* 86:252–61.

- 22-**Storz P.(2007). Mitochondrial ROS--radical detoxification, mediated by protein kinase D. *Trends Cell Biol.* 17:13–8.
- 23-**Brondon P.; Stadler I. and Lanzafame R.J.(2005). A study of the effects of phototherapy dose interval on photobiomodulation of cell cultures. *Lasers Surg Med.* 36:409–13.
- 24-**Lane P. and Gross S.S.(1999). Cell signaling by nitric oxide. *Semin Nephrol.* 19:215–29.
- 25-**Calabrese E.J.(2001a). Nitric oxide: biphasic dose responses. *Crit Rev Toxicol.* 31:489–501.
- 26-**Huang S.S. and Zheng R.L.(2006). Biphasic regulation of angiogenesis by reactive oxygen species. *Pharmazie.* 61:223–9.
- 27-**Brown G.C.(2001). Regulation of mitochondrial respiration by nitric oxide inhibition of cytochrome c oxidase. *Biochim Biophys Acta.* 1504:46–57.
- 28-**Costa A.; Poma A.; Navarra P.; Forsling M.L. and Grossman A.(1996). Gaseous transmitters as new agents in neuroendocrine regulation. *Journal of Endocrinology.* 149:199–207.
- 29-**McCann S.M.(1996). The role of nitric oxide at hypothalamic and pituitary levels to alter the release of pituitary hormones: an invited commentary. *European Journal of Endocrinology.* 135:533–534.
- 30-**Ceccatelli S.; Hulting A.L.; Zhang X.; Gustafsson L.; Villar M. and Hokfelt T. (1993). Nitric oxide synthase in the rat anterior pituitary gland and the role of nitric oxide in the regulation of the luteinizing hormone secretion. *Proceedings of the National Academy of Sciences of the USA.* 90:11292–11296.
- 31-**Adams M.L.; Meyer E.R.; Sewing B.N. and Cicero Th.J.(1994). Effects of nitric oxide-related agents on rat testicular function. *Journal of Pharmacology and Experimental Therapeutics.* 269: 230–237.