



Journal Homepage: -www.journalijar.com
**INTERNATIONAL JOURNAL OF
 ADVANCED RESEARCH (IJAR)**

Article DOI:10.21474/IJAR01/ 9329
 DOI URL: <http://dx.doi.org/10.21474/IJAR01/9329>



RESEARCH ARTICLE

ADENOCARCINOMA OF VAGINA: A CASE REPORT AND REVIEW OF THE LITERATURE.

Hind Guerroum¹, Amal Rami¹, Mohamed Allaoui², Jihane habi¹, Meriem Kassimi¹, Nabil Chikhaoui¹ and Mohamed Mahi¹.

1. Department of Radiology, Cheikh Khalifa Hospital/University Mohammed VI Health of Sciences, Casablanca, Morocco.
2. Department of Anatomopathology, Mohammed V Military instruction Hospital. Casablanca, Morocco.

Manuscript Info

Abstract

Manuscript History

Received: 03 May 2019
 Final Accepted: 05 June 2019
 Published: July 2019

Key words:-

Vaginal cancer, Adenocarcinoma, MR imaging staging, Female pelvic MR imaging, Body MR imaging, FIGO classification.

Copy Right, IJAR, 2019, All rights reserved.

Introduction:-

Vaginal carcinoma is the rarest gynaecological neoplasm, accounting for only about 1% to 3% of all gynaecological malignancies and only 10% of all vaginal malignant neoplasms. Adenocarcinoma is even rarer accounting for 9% of primary vaginal carcinomas. (1, 2, 4)

Presentation with secondary involvement including metastatic disease or direct extension of extrvaginal tumours being far more frequent. (3)

Historically these cancers are more common in elderly and postmenopausal women. (2)

Human papillomavirus, particularly subtypes 16 and 18, has been implicated as a causative agent of malignancy, increasing incidence in the younger population. (3)

Vaginal cancer is most frequently diagnosed with physical examination and pelvic biopsy. It usually results in painless vaginal bleeding and discharge.

MR imaging (MRI) is the modality of choice for initial local staging and follow up of vaginal cancer. Due to its superlative soft tissue contrast and high-resolution multiplanar imaging.

Case report

A 57-year-old postmenopausal female patient, multipare, presented with abnormal vaginal bleeding of two years duration. This was complicated by dysuria just four months prior to presentation.

Corresponding Author:-Hind Guerroum.

Address:-Department of Radiology, Cheikh Khalifa Hospital/University Mohammed VI Health of Sciences, Casablanca, Morocco.

Patient sought medical consultation in our institution where physical examination revealed two vulvar nodules, one vaginal nodule, and hemi circumferential thickening in the anterior vaginal walls.

MRI of the pelvis demonstrates a hypo-intensity on T1 and T2, and hyper-intensity on diffusion-weighted hemi circumferential thickening measuring 13,6 x 37mm located in the anterior vaginal wall that extends into the urethra, and the urinary bladder neck. With infiltration of the adjacent paravaginal fat laterally.

T1-weighted Fat Sat (FS) postcontrast MR showed early enhancement of the primary vaginal thickening. Minimal numbers of enlarged pelvic and inguinal lymph nodes were also identified. with no appearance of the vulvar and vaginal nodes. (Fig. 1 A, B, C, D)

Diagnostic biopsy of the lesion revealed moderately differentiated infiltrated adenocarcinoma

Microscopic examination revealed a medium grade tumor with irregular tubular, surrounded by cells with increased kernel size, and dense eosinophilic cytoplasm.

Multiple foci of mucoid secretions within the tubules are also present (Fig. 2 A, B). Tumor cells were positive for CK7. They were negative for P16, CK20, progesterone receptors and oestrogen receptors. (Fig. 2 C)

The rest of the clinical examination in search of a primary lesion or metastasis was negative thus concluding to the diagnosis of primary malignant adenocarcinoma of the vagina, and the tumor stage was IVA according to FIGO classification, and MRI classification.

A percutaneous suprapubic catheter (cystostomy) was inserted because of the ureteral obstruction.

Treatment consisted of radiotherapy.

Three months later, A second MRI showed non-response of the tumor thickening. (Fig.1 E, F, G, H)

The patient refused radical surgery, and palliative care was proposed.

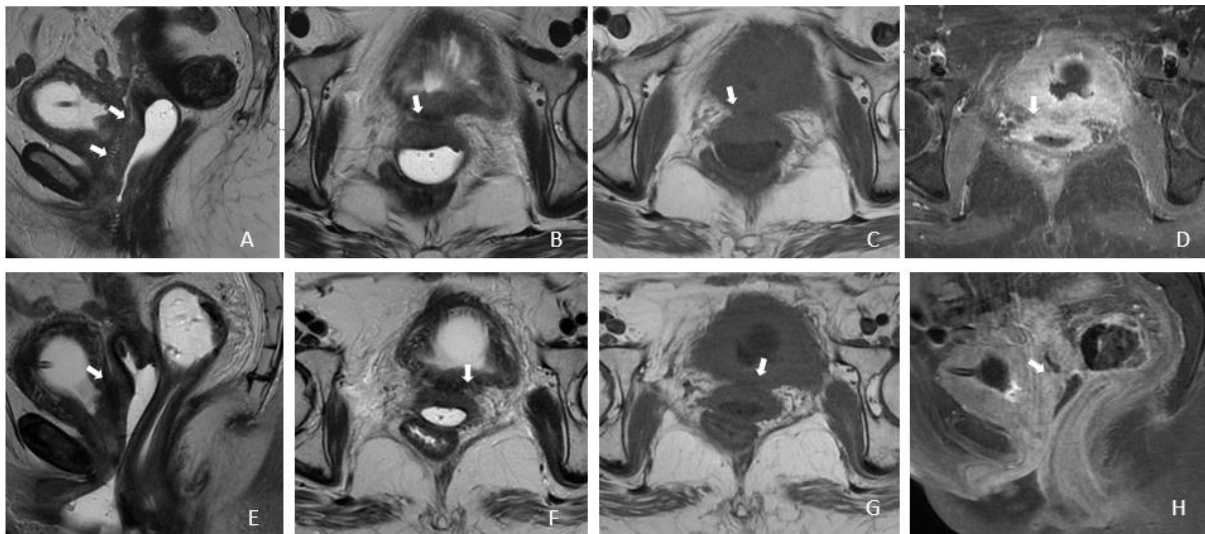


Figure 1: -First MRI:(A) Sagittal T2-weighted MR image, (B) Axial T2-weighted MR image, (C) Axial T1-weighted MR image, (D) Axial T1-weighted FS postcontrast MR image shows a hypo-intensity on T1 and T2, and early enhancement of the hemi circumferential thickening measuring 13,6 x 37mm arising from the anterior wall of the upper vagina. Invading the bladder neck and paravaginal fat (arrow).

-Three months later: A follow up MRI showed non-response of the tumor thickening (E) Sagittal T2-weighted MR image, (F) Axial T2-weighted MR image, (G) Axial T1-weighted MR image, (H) Sagittal T1-weighted FS postcontrast MR image.

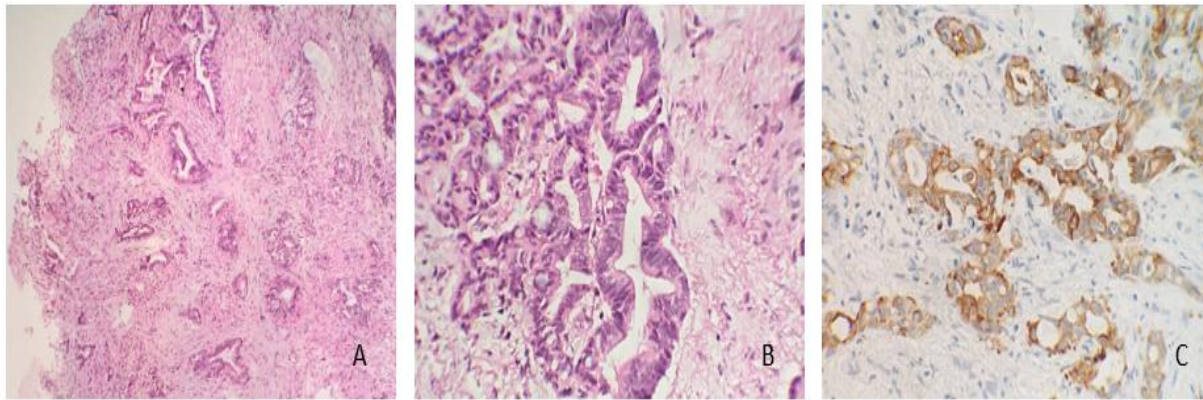


Figure 2: -Moderately differentiated infiltrated adenocarcinoma of vagina with irregular tubular, surrounded by cells with increased kernel size, and dense eosinophilic cytoplasm (A, B) Immunohistochemical study: Tumor cells were positive for CK7. (C)

Discussion:-

Primary carcinoma of the vagina is rare, Adenocarcinomas is even rarer accounting for only 9% of primary vaginal carcinomas. They typically occur in younger women aged 14–21 years. In these younger women, primary vaginal adenocarcinoma is thought to arise from areas of vaginal adenosis but may also arise in foci of endometriosis, wolffian rest remnants, and periurethral glands. (4)

In utero exposure to diethylstilbestrol (DES) used to be the main cause of adenocarcinoma from the fifties to the seventies in this category, but not anymore due to the cessation of the use of DES in pregnancy. In the gynecologic oncology literature, regarding older women, primary vaginal clear cell adenocarcinoma arises from area of müllerian tissue. (4)

Adenocarcinoma usually present with painless vaginal bleeding, abnormal discharge, urinary symptoms, and pelvic pain.

It occurs mainly in the upper third and anterior wall of the vagina. Macroscopically, primary vaginal adenocarcinoma appears as a polypoid, papillary, plaquelike, or ulcerated lesion. (4)

Clinical assessment may be difficult specially in detecting lymphadenopathy and the extension of tumour infiltration, therefore MR imaging is a powerful tool for local staging, owing to its superior soft tissue resolution.

MRI of the pelvis for vaginal cancer is similar to that for cervical cancer. The patient should be imaged supine with a torso- or pelvic-phased array coil.

For optimal tumour characterisation, instillation of vaginal gel into the vagina prior to the MR and a partially filled bladder may be helpful. (3)

Imaging protocol consists of axial T1-weighted and T2-weighted fast spin-echo imaging through the pelvis from the aortic bifurcation to below the vulva. This gives an overview of the whole pelvis and allows assessment of pelvic and inguinal lymphadenopathy. Sagittal T2-weighted fast spin-echo imaging from pelvic sidewall to sidewall allows assessment of vaginal tumor extension to the uterus, bladder, urethra, and rectum. These sequences are supplemented with high-resolution oblique axial (perpendicular to the long axis of the vagina) T2-weighted fast spin-echo imaging. This sequence allows detailed assessment of the vaginal tumor and its relation to the paravaginal tissues and thus accurately demonstrates the extent of disease. Vaginal tumors are almost always best seen with this sequence. Coronal T2-weighted images allow evaluation of the pelvic sidewall in larger tumors. (4)

Echo planar diffusion-weighted axial imaging with b values of 50, 500, and 1000 (with a calculated apparent diffusion coefficient (ADC) map).

Dynamic T1 spoiled gradient echo fat suppressed axial imaging is performed at 15 second intervals for 3scans

(arterial, venous, and equilibrium phase images) followed by sagittal and coronal oblique post-contrast-enhanced images. (3)

The appearances of primary vaginal adenocarcinoma at MR imaging have been described as a bulky lobulated vaginal mass or diffuse circumferential thickening of the vaginal wall, appearances that are compatible with a macroscopic polypoid or papillary lesion. Primary vaginal adenocarcinoma appears homogeneously hyperintense on T2-weighted images and isointense to muscle on T1-weighted images. Owing to the intrinsic high signal intensity of this epithelial tumor with T2-weighted sequences, MR imaging can demonstrate the low signal intensity of the vaginal wall and can therefore accurately demonstrate invasion into the paravaginal tissues. (4)

In primary vaginal tumors, clinical assessment may be difficult and MRI may be a useful tool in individual cases owing to its superior soft tissue resolution.

In our case, the tumor appears hypo-intense on T1 and T2 weighted images located in the two-thirds of the anterior vaginal wall, invading directly the urethra, bladder neck and paravaginal fat. with pelvic and inguinal lymph node.

Vaginal cancer is rare and, as a result, treatment is based on the case reports and series that have been collected over time. There is no level evidence to support best treatment options. It is recommended that a multidisciplinary team be involved in decisions regarding treatment. (2)

There is an increasing trend towards organ preservation and treatment strategies based on combined external beam radiation and brachytherapy, often with concurrent chemotherapy, surgery being reserved for those with in situ or very early-stage disease. (5)

Our patient received radiotherapy, three months later, a follow up MRI showed non-response of the tumor thickening. The patient refused radical surgery, and palliative care was proposed.

Conclusion: -

Adenocarcinoma of the vagina is rare, clinical assessment may be difficult, MR imaging is an important tool for initial local staging due to its superb soft-tissue contrast resolution in characterisation of the lesion and evaluating their extension and contact with the surrounding tissue and adjacent organs, providing a detailed assessment.

It's a powerful tool in follow up also without ionizing radiation allowing a better treatment planning.

The immunohistochemical study is very useful for the histologic diagnosis.

In the present literature it is recommended that a multidisciplinary team be involved in decisions regarding treatment.

Treatment strategies are based on combined external beam radiation and brachytherapy, often with concurrent chemotherapy, surgery being reserved for those with in situ or very early-stage disease.

The Prognosis is poor and depends on the stage of disease at the time of diagnosis, the MD Anderson Cancer Center reported five-year survival of 34% in elderly and postmenopausal women.

References: -

1. Tadeusz Fedus, Md, Renata Raś, Phd, Mariusz Książek And Al Primary Vaginal Squamous Cell Carcinoma With Bladder Involvement In Uterine Prolapsed Patient
2. Case report 2017 dec 15.
3. Tracey s. Adams mauricio a. Cuello and al cancer of the vagina international journal of gynecology & obstetrics 143:14-21 · october 2018
4. Anup s. Shetty, mda., christine o. Menias, mdb mr imaging of vulvar and vaginal cancer 2017.03.013 magnetic resonance imaging clinics of north america
5. jyoti h. Parikh, desmond p. J. Barton, thomas e. J. Ind, s. Aslam sohaibmr imaging features of vaginal malignancies 2008 radiographics

6. c s gardner, md, j sunil, md, a h klopp, md, c e devine, md, t sagebiel, md, c viswanathan, andp r bhosale, md and al . Primary vaginal cancer: role of mri in diagnosis, staging and treatment 2015 the british journal of radiology .