

# Jana Publication & Research

## AN UNUSUAL FOREIGN BODY IN OESOPHAGUS

 12 BioTech Institut Seni Indonesia Surakarta

---

### Document Details

**Submission ID**

trn:oid::1:3182683647

**Submission Date**

Mar 14, 2025, 11:43 AM GMT+7

**Download Date**

Mar 14, 2025, 12:05 PM GMT+7

**File Name**

IJAR-50621.docx

**File Size**

426.3 KB

**6 Pages****1,594 Words****9,349 Characters**





# 22% Overall Similarity

The combined total of all matches, including overlapping sources, for each database.




## Filtered from the Report

- Bibliography
- Quoted Text

## Match Groups

-  **15 Not Cited or Quoted 16%**  
Matches with neither in-text citation nor quotation marks
-  **6 Missing Quotations 5%**  
Matches that are still very similar to source material
-  **0 Missing Citation 0%**  
Matches that have quotation marks, but no in-text citation
-  **0 Cited and Quoted 0%**  
Matches with in-text citation present, but no quotation marks

## Top Sources

- 14%  Internet sources
- 19%  Publications
- 6%  Submitted works (Student Papers)

## Match Groups

- 15 Not Cited or Quoted 16%**  
Matches with neither in-text citation nor quotation marks
- 6 Missing Quotations 5%**  
Matches that are still very similar to source material
- 0 Missing Citation 0%**  
Matches that have quotation marks, but no in-text citation
- 0 Cited and Quoted 0%**  
Matches with in-text citation present, but no quotation marks

## Top Sources

- 14% Internet sources
- 19% Publications
- 6% Submitted works (Student Papers)

## Top Sources

The sources with the highest number of matches within the submission. Overlapping sources will not be displayed.

1	Internet	link.springer.com	3%
2	Internet	docshare.tips	2%
3	Internet	www.ijcap.org	2%
4	Internet	www.ncbi.nlm.nih.gov	1%
5	Student papers	University of Kent at Canterbury	1%
6	Internet	1library.net	1%
7	Publication	Mohammed Baseer, Nandkishor Shinde, Sam Joy. "Clinical profile and manageme...	1%
8	Publication	Iulia Cristina Pîrvulescu, Alfred Najm, Eduard Cristian Popa, Alexandru Laurentiu ...	<1%
9	Internet	juniperpublishers.com	<1%
10	Publication	Arijit Jotdar, Mainak Dutta, Sohag Kundu, Bhaskar Ghosh, Indranil Chatterjee. "Su...	<1%

11	Publication	Ryan M. Aronberg, Salman R. Punekar, Stewart I. Adam, Benjamin L Judson, Saral ...	<1%
12	Internet	kipdf.com	<1%
13	Internet	www.pubfacts.com	<1%
14	Publication	Hiroshi Sakaida, Kazuki Chiyonobu, Hajime Ishinaga, Kazuhiko Takeuchi. "Use of ...	<1%
15	Publication	Rodriguez, H.. "Management of foreign bodies in the airway and oesophagus", In...	<1%
16	Internet	file.scirp.org	<1%
17	Internet	mdpi-res.com	<1%
18	Publication	Satish Chandra Tripuraneni, Sameera Gera, G. Nanda Kishore, T. V. Rajinikanth, G....	<1%
19	Publication	V. T. Hammond. "Perforating Foreign Body of Pharynx", The Journal of Laryngolo...	<1%
20	Publication	Vijay Kalra, S. P. S. Yadav, Rupender Ranga, Himanshu Moudgil, Anshu Mangla. "E...	<1%

## AN UNUSUAL FOREIGN BODY IN OESOPHAGUS.

### ABSTRACT:

Foreign body in the oesophagus is one of the most common emergencies encountered in the otolaryngology practice. It's not unusual to come across abnormal things as foreign bodies apart from routine coins, bone pieces. Esophagoscopy happens to be the treatment of choice occasionally requires open approaches to remove impacted foreign bodies. In this case report we would like to share our experience in managing a patient, who accidentally ingested a plastic bottle cap. Despite multiple attempts of endoscopic retrieval, the bottle cap remained firmly lodged in the oesophagus, resulting in a partial tear of the oesophageal wall. We successfully retrieved the foreign body and managed complications with an open approach.

**Keywords:** foreign body oesophagus, esophagoscopy, transcervical approach.

### INTRODUCTION:

Foreign bodies in the oesophagus are twice common than bronchial foreign bodies <sup>(1)</sup>. Among the various items ingested, coins, pins, dentures, batteries, and chicken bones are frequently reported <sup>(2)</sup>. Unusual foreign bodies like spoons, thorns of babul tree, open safety pins were also reported <sup>(3,4)</sup>.

Impacted foreign body in oesophagus are considered to be a life-threatening condition in both children and adults due to its dreadful complications such as oesophageal perforation, mediastinitis, airway obstruction, retropharyngeal abscess with high mortality and morbidity <sup>(5,6)</sup>. Management of impacted foreign body depends on factors like anatomical location, shape and size of foreign body and duration of impaction of foreign body <sup>(7)</sup>.

Esophagoscopy is considered as gold standard for removal of foreign body in oesophagus <sup>(8,9)</sup>. Even though success rate of endoscopy is 94%-100%, it is not feasible in foreign bodies which are impacted in the mucosal walls of the oesophagus or large foreign bodies which got struck in the oesophageal lumen which cannot be grasped <sup>(10,11)</sup>. In such conditions transcervical oesophagotomy is considered as last resort. Major indications for an open approach are larger irregularly shaped foreign bodies, failed endoscopic attempts for retrieval, cervical oesophageal perforation <sup>(10)</sup>.

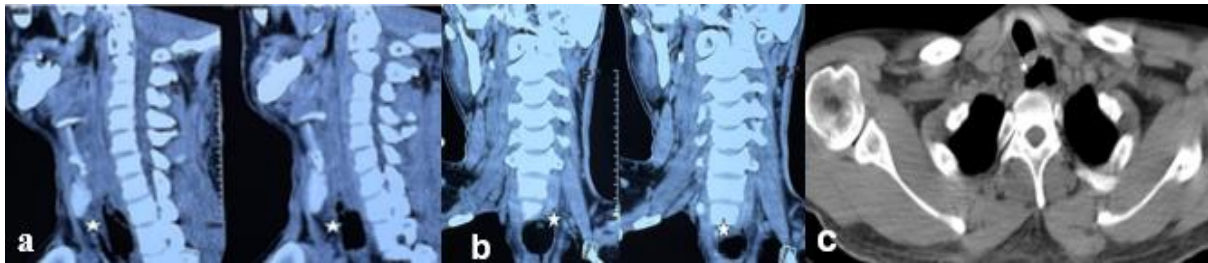
We report a case of foreign body oesophagus which was stuck in the oesophageal lumen which could not be retrieved after repeated attempts of endoscopic retrieval; hence we managed it with transcervical oesophagotomy.

### CASE REPORT:

14 A 29year old male patient, who is intellectually disabled and visually impaired, was referred to our institute following the accidental ingestion of a loose plastic bottle cap while attempting to drink water, the bottle cap became lodged in the oesophagus, leading to its impaction.

11 The patient was initially tried for the retrieval of the bottle cap through flexible esophagoscopy by a gastroenterologist, as well as rigid esophagoscopy by an ENT surgeon elsewhere, both these interventions got failed to retrieve the bottle cap, as it was firmly lodged with in the oesophageal lumen with its open surface was facing downwards, then patient was referred to our institute for further management.

17 The patient was evaluated with CT neck which revealed foreign body located in the upper oesophagus at C6 and C7 vertebrae and was seen impinging on the posterior wall of trachea. [Figure 1- (a), (b), (c)].



10 Figure 1: (a), (b) CT scan of sagittal and coronal views showing the foreign body (bottle cap) noted in the upper oesophagus at the level of C6 and C7 vertebrae which is seen impinging the posterior wall of trachea. (c) Axial cut of CT scan showing foreign body posterior to trachea.

The gastroenterologist performed a flexible esophagoscopy and attempted to utilize a loop device for retrieval, which resulted in bleeding and further impaction of the object.

19 We then proceeded for an open approach transcervical esophagotomy, on the left side of neck. A vertical skin incision was made just before the anterior border of sternocleidomastoid. The sternocleidomastoid muscle was retracted posteriorly. Then we entered the space between the trachea and the carotid sheath, carotid sheath is retracted laterally. The recurrent laryngeal nerve was identified and preserved. The oesophagus was palpated, an incision was given on the wall of oesophagus at the level of foreign body and the bottle cap is held and was retrieved successfully [Figure 2- (a), (b), (c)].

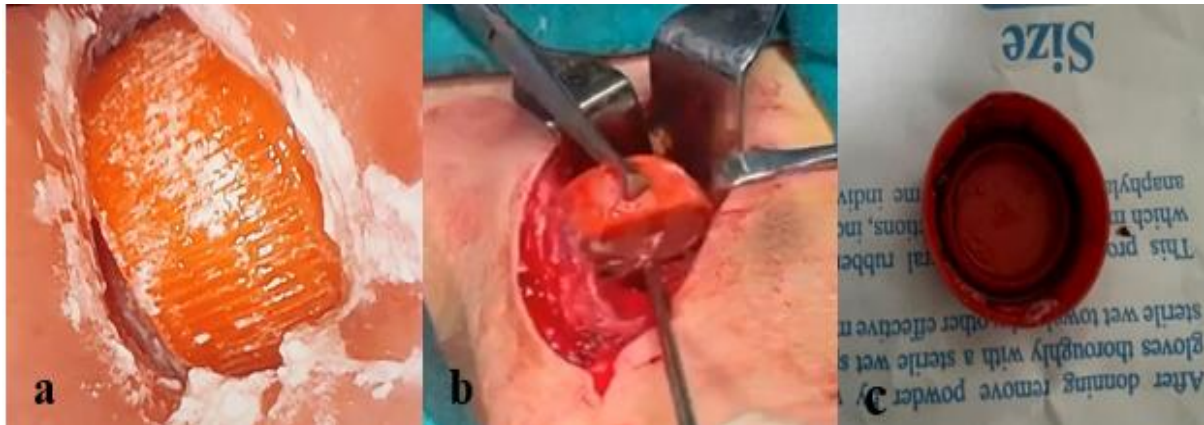


Figure 2: (a) Showing endoscopic view of the impacted bottle cap.

(b) Intraoperative picture of foreign body held by a forceps and the foreign body which was retrieved.

(C) Bottle cap which was retrieved.

Oesophagus was closed in three layers and Ryles tube was inserted. Patient was kept nil per oral for 10 days. On POD- 11 he was allowed clear fluids first and then followed by oral feeds which were well tolerated.

## DISCUSSION:

Accidental foreign body ingestion and its oesophageal impaction is a frequent emergency in otolaryngology <sup>(7)</sup>. The impaction of ingested foreign bodies usually occurs at anatomical constrictions of oesophagus like cricopharyngeal sphincter, at level of aortic arch and left main bronchus, lower oesophageal sphincter <sup>(12)</sup>.

Minimally invasive techniques such as flexible and rigid endoscopic methods, are widely employed as first line of management for the retrieval of oesophageal foreign bodies <sup>(13)</sup>. However, the endoscopic approaches may fail in certain circumstances due to the impaction of the foreign body or the presence of sharp objects such as open safety pins, dentures which can perforate the oesophageal mucosa during retrieval leading to life threatening complications like mediastinitis, thus necessitating alternative surgical interventions like open approaches <sup>(14)</sup>. Also in some instances, patients may present with significant complications resulting from neglected foreign bodies, which can perforate and migrate into adjacent structures, leading to severe complications such as formation of abscesses in the adjacent tissues and potentially extending to the upper mediastinum, airway obstruction which necessitates prompt intervention through open cervical surgery <sup>(15)</sup>.

However, the process of endoscopic retrieval itself carries risks, including potential local injury to the oesophageal mucosa causes lacerations leading to perforation reported at incidence of 0.34%, which in turn may lead to necrosis, or stricture formation <sup>(15)</sup>. In light of these complications and the specific indications for surgical intervention, in these cases the preferred treatment modality is an open surgical approach via cervical esophagotomy <sup>(16)</sup>.

## Declarations

**Funding:** There was no source of funding for the study.

**Conflict of interest:** The authors declare no conflict of interest.

**Compliance with Ethical standards:** The Ethics Committee at our institute has confirmed that no ethical approval is required.

**Financial interest:** Authors certify that they have no affiliations with or involvement in any organization or entity with any financial interest or non-financial interest in the subject matter or materials discussed in this manuscript.

## References:

1. Rodríguez, H., Passali, G. C., Gregori, D., Chinski, A., Tiscornia, C., Botto, H., ... Cuestas, G. (2012). Management of foreign bodies in the airway and oesophagus. *International Journal of Pediatric Otorhinolaryngology*, 76, S84–S91. doi:10.1016/j.ijporl.2012.02.010.
2. Arana, A., Hauser, B., Hachimi-Idrissi, S., & Vandenplas, Y. (2001). Management of ingested foreign bodies in childhood and review of the literature. *European Journal of Pediatrics*, 160(8), 468–472. doi:10.1007/s004310100788.
3. Kim SI, Jung SY, Song CE, Shim DB. Unusual Foreign Body, a Spoon, in the Esophagus of a Middle-Aged Female: A Case Report and Review of the Literature. *Ear Nose Throat J*. 2022 Jan;101(1):NP31-NP33. doi: 10.1177/0145561320942680. Epub 2020 Jul 22. PMID: 32697114.
4. Shinde K, Gupta A. An unusual foreign body in oesophagus. *Indian J Otolaryngol Head Neck Surg*. 1999 Aug;51(Suppl 1):62-4. doi: 10.1007/BF03001558. PMID: 23119600; PMCID: PMC3451023.



5. Ziad T, Rochdi Y, Benhoummad O, Nouri H, Aderdour L, Raji A. Retropharyngeal abscess revealing a migrant foreign body complicated by mediastinitis: a case report. *Pan Afr Med J.* 2014 Oct 3;19:125. doi: 10.11604/pamj.2014.19.125.5334. PMID: 25745532; PMCID: PMC4341256.
  
6. Akazawa, Y., Watanabe, S., Nobukiyo, S., Iwatake, H., Seki, Y., Umehara, T., ... Koizuka, I. (2004). The management of possible fishbone ingestion. *Auris Nasus Larynx*, 31(4), 413–416. doi:10.1016/j.anl.2004.09.007.
  
7. Sigdel B, Pokhrel A, Subedi B, Subedi I, Ghimire B, Paudel S. Use of a transcervical approach to retrieve a foreign body from the upper esophagus. *Clin Case Rep.* 2024 Aug 6;12(8):e9272. doi: 10.1002/ccr3.9272. PMID: 39109311; PMCID: PMC11300954.
  
8. Karaman, A., Çavuşoğlu, Y. H., Karaman, İ., Erdoğan, D., Aslan, M. K., & Çakmak, Ö. (2004). Magill forceps technique for removal of safety pins in upper esophagus: a preliminary report. *International Journal of Pediatric Otorhinolaryngology*, 68(9), 1189–1191. doi:10.1016/j.ijporl.2004.04.012.
  
9. Ikenberry, S. O., Jue, T. L., Anderson, M. A., Appalaneni, V., Banerjee, S., Ben-Menachem, T., ... Dominitz, J. A. (2011). Management of ingested foreign bodies and food impactions. *Gastrointestinal Endoscopy*, 73(6), 1085–1091. doi:10.1016/j.gie.2010.11.010.
  
10. Shreshtha, D., Sikka, K., Singh, C. A., & Thakar, A. (2013). Foreign Body Esophagus: When Endoscopic Removal Fails.... *Indian Journal of Otolaryngology and Head & Neck Surgery*, 65(4), 380–382. doi:10.1007/s12070-013-0662-6.
  
11. Li, Z.-S., Sun, Z.-X., Zou, D.-W., Xu, G.-M., Wu, R.-P., & Liao, Z. (2006). Endoscopic management of foreign bodies in the upper-GI tract: experience with 1088 cases in China. *Gastrointestinal Endoscopy*, 64(4), 485–492. doi:10.1016/j.gie.2006.01.059.
  
12. Jayachandra, S., & Eslick, G. D. (2013). A systematic review of paediatric foreign body ingestion: Presentation, complications, and management. *International Journal of Pediatric Otorhinolaryngology*, 77(3), 311–317. doi:10.1016/j.ijporl.2012.11.025.
  
13. Spitz L. Management of ingested foreign bodies in childhood. *Br Med J.* 1971 Nov 20;4(5785):469-72. doi: 10.1136/bmj.4.5785.469. PMID: 5125285; PMCID: PMC1799648.
  
14. Chinski A, Foltran F, Gregori D, Ballali S, Passali D, Bellussi L. Foreign Bodies in the Oesophagus: The Experience of the Buenos Aires Paediatric ORL Clinic. *Int J Pediatr.* 2010;2010:490691. doi: 10.1155/2010/490691. Epub 2010 Sep 20. PMID: 20886022; PMCID: PMC2945666.

15. Brinster CJ, Singhal S, Lee L, Marshall MB, Kaiser LR, Kucharczuk JC. Evolving options in the management of esophageal perforation. *Ann Thorac Surg*. 2004 Apr;77(4):1475-83. doi: 10.1016/j.athoracsur.2003.08.037. PMID: 15063302.

16. Brinster CJ, Singhal S, Lee L, Marshall MB, Kaiser LR, Kucharczuk JC. Evolving options in the management of esophageal perforation. *Ann Thorac Surg*. 2004;77(4):1475-83. doi: 10.1016/j.athoracsur.2003.08.037.