


# Jana Publication & Research

## Ischemic Stroke in a Young Adult Revealing Moyamoya Disease: A Rare Cause

 16

 BioTech

 Institut Seni Indonesia Surakarta

---

### Document Details

**Submission ID**

trn:oid::1:3188698528

**Submission Date**

Mar 20, 2025, 12:11 PM GMT+7

**Download Date**

Mar 20, 2025, 12:46 PM GMT+7

**File Name**

IJAR-50728.docx

**File Size**

1.3 MB

**6 Pages**

**1,891 Words**

**12,143 Characters**

# 28% Overall Similarity





The combined total of all matches, including overlapping sources, for each database.

## Filtered from the Report




- ▶ Bibliography
- ▶ Quoted Text

---

## Match Groups

-  **38 Not Cited or Quoted 28%**  
Matches with neither in-text citation nor quotation marks
-  **0 Missing Quotations 0%**  
Matches that are still very similar to source material
-  **0 Missing Citation 0%**  
Matches that have quotation marks, but no in-text citation
-  **0 Cited and Quoted 0%**  
Matches with in-text citation present, but no quotation marks

## Top Sources

- 21%  Internet sources
- 25%  Publications
- 6%  Submitted works (Student Papers)

### Match Groups

- **38 Not Cited or Quoted 28%**  
Matches with neither in-text citation nor quotation marks
- **0 Missing Quotations 0%**  
Matches that are still very similar to source material
- **0 Missing Citation 0%**  
Matches that have quotation marks, but no in-text citation
- **0 Cited and Quoted 0%**  
Matches with in-text citation present, but no quotation marks

### Top Sources

- 21% Internet sources
- 25% Publications
- 6% Submitted works (Student Papers)

### Top Sources

The sources with the highest number of matches within the submission. Overlapping sources will not be displayed.

1	Internet	www.dovepress.com	2%
2	Internet	openneuroimagingjournal.com	2%
3	Internet	www.mdpi.com	2%
4	Internet	www.ncbi.nlm.nih.gov	2%
5	Publication	Douglas J. Cook, Nitin Mukerji, Sunil V. Furtado, Gary K. Steinberg. "Chapter 102-1...	2%
6	Internet	wmjonline.org	2%
7	Internet	referencecitationanalysis.com	1%
8	Publication	Med Dheker Touati, Ahmed Bouzid, Mohamed Raouf Ben Othmane, Anis Belhadj, ...	1%
9	Publication	Moyamoya Disease Update, 2010.	1%
10	Publication	Van Gompel, J.J.. "Preoperative Embolization of the External Carotid Artery Branc...	1%

11	Publication	J. Takanashi, K. Sugita, Y. Tanabe, C. Ito, H. Date, H. Niimi. "T2 shortening in child...	1%
12	Publication	Kaoru Tateno, Koichiro Sugimura, Yoshihide Fujimoto, Akio Kawamura. "Altered p...	1%
13	Publication	Anna Cecilia Amaral, Waleed K. Hussain, Raj J. Shah, Samuel Han. "Troubleshootin...	<1%
14	Internet	d.docksci.com	<1%
15	Internet	scholar.archive.org	<1%
16	Publication	"Moyamoya Disease Explored Through RNF213", Springer Nature, 2017	<1%
17	Publication	Nomazulu Dlamini, Prakash Muthusami, Catherine Amlie-Lefond. "Childhood Mo...	<1%
18	Internet	discovery.researcher.life	<1%
19	Internet	ebin.pub	<1%
20	Internet	www.frontiersin.org	<1%
21	Publication	B. Sundaravadivazhagan, Sekar Mohan, Balakrishnaraja Rengaraju. "Recent Deve...	<1%
22	Publication	Eom, K. S., D. W. Kim, S.-S. Choi, and S. D. Kang. "Spontaneous Recanalization of a...	<1%
23	Publication	Mariano Velo, Giovanni Grasso, Miki Fujimura, Fabio Torregrossa et al. "Moyamoy...	<1%
24	Internet	j-stroke.org	<1%

25	Publication	"Management of Cerebrovascular Disorders", Springer Science and Business Med...	<1%
26	Publication	Carlee Oakley, Giuseppe Lanzino, James Klaas. "Neuropsychiatric Symptoms of M...	<1%
27	Publication	Giuseppe Mancia, Guido Grassi, Konstantinos P. Tsioufis, Anna F. Dominiczak, Enr...	<1%
28	Publication	Isabella Canavero, Ignazio Gaspare Vetrano, Marialuisa Zedde, Rosario Pascarella...	<1%

## Ischemic Stroke in a Young Adult Revealing Moyamoya Disease: A Rare Cause

### Abstract:

Moyamoya disease is a rare cerebrovascular disorder characterized by progressive stenosis or occlusion of the proximal cerebral arteries, resulting in the formation of abnormal collateral networks that create the angiographic 'puff of smoke' appearance, from which the Japanese term 'Moyamoya' is derived. Clinically, the disease presents with a broad spectrum of symptoms, ranging from transient ischemic attacks (TIAs) to intracranial hemorrhages and completed ischemic strokes. We present the case of a 47-year-old woman admitted for an altered state of consciousness. Magnetic resonance imaging (MRI) revealed findings consistent with Moyamoya disease. This case underscores the importance of early diagnosis, often facilitated by imaging, to guide therapeutic strategies and improve patient outcomes.

### Key words:

Moyamoya, ischemic stroke, stenosis, MRI, angiography.

### Introduction :

Moyamoya disease is a rare cerebrovascular disorder characterized by progressive stenosis or occlusion of the proximal cerebral arteries, leading to the development of abnormal collateral vessels that produce the angiographic 'puff of smoke' appearance—a feature from which the Japanese term 'Moyamoya' originates. Clinically, the disease manifests with a wide range of symptoms, including transient ischemic attacks (TIAs), intracranial hemorrhages, and completed ischemic strokes. We report the case of a 47-year-old woman who presented with an altered state of consciousness. Magnetic resonance imaging (MRI) demonstrated findings consistent with Moyamoya disease. This case highlights the critical role of early diagnosis, often achieved through imaging, in guiding therapeutic interventions and improving patient outcomes.

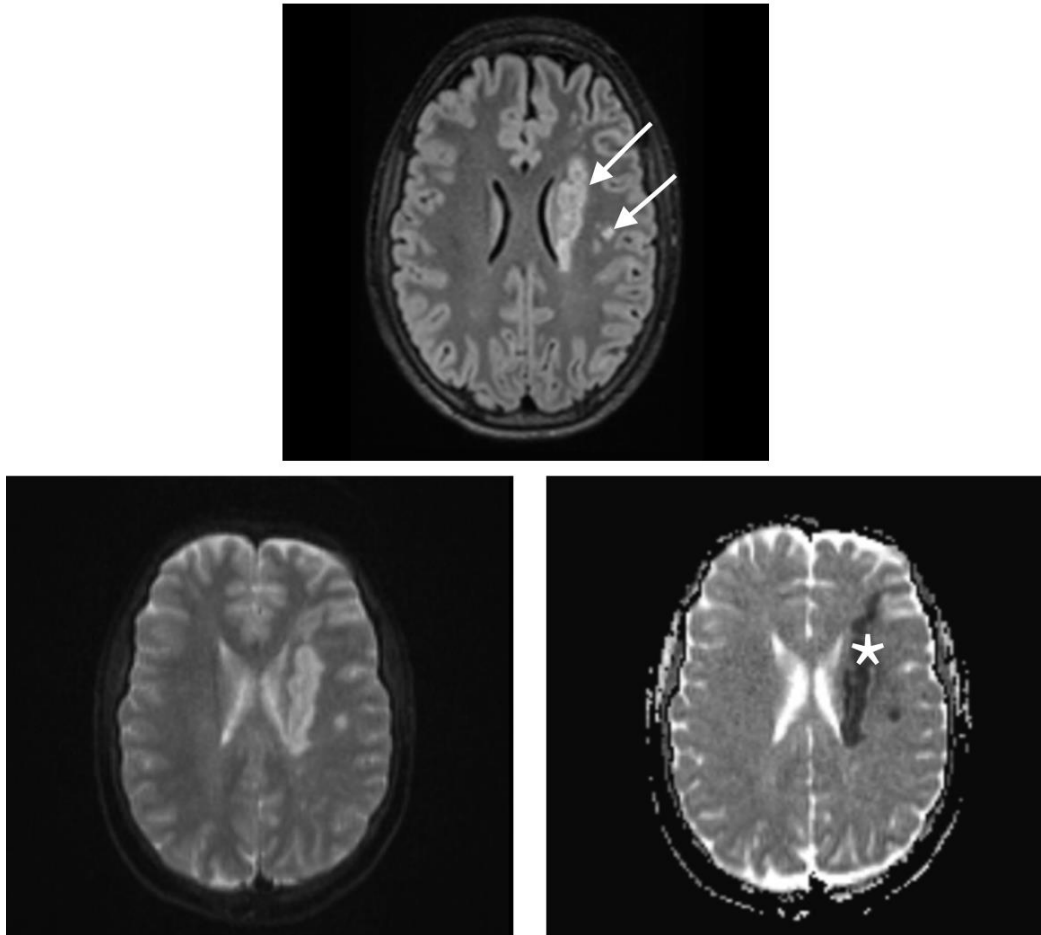
### Patient and Case Report:

We report the case of a 47-year-old woman with no significant medical history, who presented to the emergency department with sudden-onset altered consciousness in an afebrile context. Upon admission, the patient had a Glasgow Coma Scale (GCS) score of 10 (Motor: 5, Verbal: 1, Eye Opening: 4), with equal and reactive pupils, nuchal rigidity, no detectable sensorimotor deficits, and no clinical signs of seizures. The patient was hemodynamically stable, with a heart rate of 88 beats per minute and a blood pressure of 140/80 mmHg. Respiratory status was also stable, with an oxygen saturation of 97% on room air and eupnea. Blood glucose levels were measured at 1.6 g/L, and body temperature was normal at 37.3 °C.

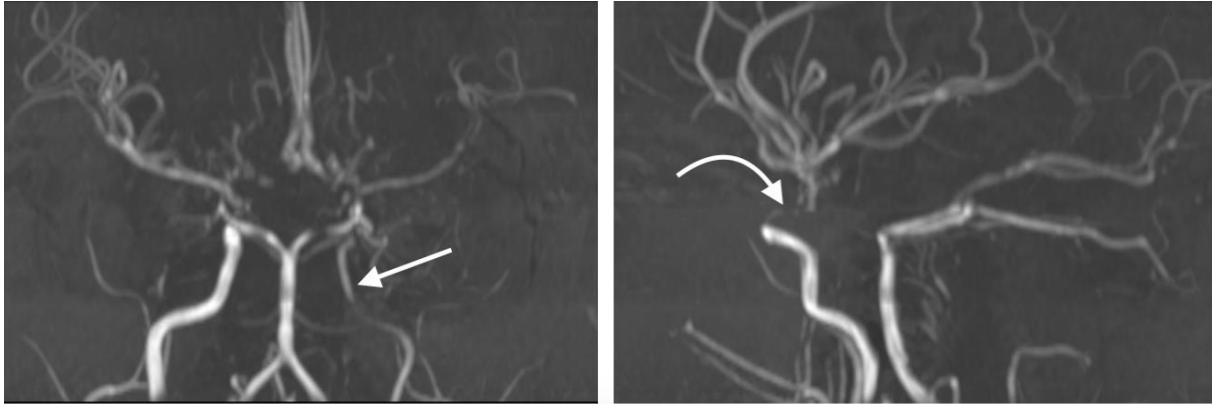
Due to further neurological deterioration, a modified rapid sequence intubation was performed. Preoxygenation was achieved with high-flow oxygen for 3 minutes, followed by administration of

fentanyl (3  $\mu\text{g}/\text{kg}$ , 250  $\mu\text{g}$ ), titrated propofol (140 mg), and rocuronium (1.2 mg/kg, administered due to the unavailability of succinylcholine). Intubation was classified as Cormack Grade 2 (easy), with proper endotracheal tube placement confirmed by symmetric bilateral auscultation. An additional dose of fentanyl (100  $\mu\text{g}$ ) was administered post-intubation for analgesia.

After stabilization, the patient was transferred to the imaging unit for MRI, which revealed a left subcortical ischemic lesion of acute appearance (Figure 1a). Magnetic resonance angiography (MRA) sequences demonstrated a reduced caliber of the left internal carotid artery, along with a slender and irregular appearance of the branches of the circle of Willis (Figure 1b).



**Figure 1a : FLAIR sequence demonstrating a signal abnormality in the left corona radiata (white arrow) with restricted diffusion (white star), consistent with acute ischemic stroke.**



**Figure 1b : TOF sequence, which is a no contrast angiography technique used to assess cerebral circulation, showing a reduced caliber of the left internal carotid artery (white arrow) with diminished flow in the left middle cerebral artery and tandem stenoses in its proximal segment (bended arrow).**

Following admission to the intensive care unit, the patient was placed under deep sedation, managed for acute secondary cerebral insults, and monitored using transcranial Doppler. On day 5, an external ventricular drain (EVD) was inserted due to the development of active hydrocephalus.

Despite these measures, the patient's neurological condition deteriorated by day 9, with a decline in GCS to 4, attributed to diffuse ischemic lesions and generalized cerebral edema. Despite aggressive therapeutic interventions, the clinical course remained unfavorable, and the patient passed away on day 13.

### Discussion

Moyamoya disease is characterized by stenosis of the cerebral arteries, which is compensated by the development of collateral vascular networks. However, these collateral vessels are fragile and prone to hemorrhages and aneurysms. Angiography typically reveals a characteristic 'puff of smoke' appearance, from which the disease derives its name (2).

Moyamoya disease encompasses two entities (6) :

- **Moyamoya disease:** Bilateral carotid involvement without an underlying condition.
- **Moyamoya syndrome:** Unilateral involvement or association with other conditions (e.g., Down syndrome, sickle cell disease, neurofibromatosis type 1).

The pathophysiology of Moyamoya disease (MMD) involves progressive, bilateral stenosis of the internal carotid arteries (ICAs), often accompanied by involvement of the proximal segments of the anterior and middle cerebral arteries (7). This stenosis leads to cerebral ischemia due to significantly reduced blood flow. In response, hemodynamic stress, including increased shear forces on vascular walls, triggers the production of molecules such as vascular endothelial growth factor (VEGF), promoting pathological vascular remodeling (8).

Moyamoya disease exhibits a complex etiology involving both genetic and environmental factors. A hereditary component is observed in approximately 10% of cases, with several genetic mutations implicated (10):



- RNF213 (11): Located on chromosome 17, this gene is the primary genetic factor associated with MMD, particularly in Asian populations. The p.R4810K mutation is strongly correlated with disease susceptibility and severity.
- ACTA2: Encoding smooth muscle cell alpha-2 actin, mutations in this gene impair vascular cell function, contributing to MMD.
- GUCY1A3: Involved in guanylate cyclase signaling, this gene regulates vascular tone. Mutations may contribute to progressive stenosis of cerebral vessels.

Other mutations located on various chromosomes have been reported, reflecting significant genetic heterogeneity. Although genetic factors are predominant, interactions with environmental influences, such as infections or inflammation, may play a triggering role in some cases.

The diverse clinical manifestations of Moyamoya disease reflect the combined impact of vascular stenosis and fragile collateral vessels on cerebral blood flow (12). Transient ischemic attacks (TIAs) often represent the initial clinical manifestation in children, frequently triggered by physical exertion, crying, or hyperventilation, which increase cerebral oxygen demand. In younger patients (4), ischemic strokes predominate due to hypoperfusion related to stenosis. Conversely, in older patients, particularly those over 40, hemorrhagic strokes are more frequent (5), resulting from the rupture of fragile collateral vessels in deep brain regions. This bimodal distribution is typical of Moyamoya disease (3).

In addition to TIAs and strokes, seizures may occur, particularly in children, as a result of cerebral ischemia. Some patients may also experience progressive cognitive decline, linked to chronic ischemia and structural brain damage.

The diagnosis of MMD relies on cerebral angiography, which visualizes progressive vessel stenosis and the development of characteristic collateral networks. Disease progression is classified into six stages based on Suzuki's classification (14).

- Stage I** : Narrowing of the terminal segments of the internal carotid artery.
- Stage II** : Appearance of Moyamoya-type vessels in the basal circulation, with dilation of intracerebral arteries.
- Stage III** : Intensification of Moyamoya vessels, severe carotid stenosis, and involvement of the anterior and middle cerebral arteries.
- Stage IV** : Reduction in Moyamoya vessels and involvement of the posterior cerebral arteries.
- Stage V** : Further reduction of Moyamoya vessels and disappearance of major cerebral arteries.
- Stage VI** : Disappearance of Moyamoya collaterals and ICAs; cerebral perfusion depends on external carotid arteries via leptomeningeal anastomoses.

**Figure 2 : Classification in 6 stages according to Suzuki.**

The management of Moyamoya disease primarily focuses on preventing ischemic and hemorrhagic events while enhancing cerebral blood flow. Antiplatelet agents, such as aspirin, are used to reduce the risk of thrombosis; however, surgical intervention is generally recommended, particularly for symptomatic patients (15).

Several surgical techniques are employed for cerebral revascularization. Among direct approaches, anastomosis between the superficial temporal artery (STA) and the middle cerebral artery (MCA) is the most common, providing immediate restoration of blood flow. Indirect techniques, such as encephaloduro-arterio-synangiosis (EDAS), encephalo-myosynangiosis (EMS), and multiple burr holes, promote the development of collateral vessels through natural mechanisms, although their effects may take several months to become apparent. Combined revascularization, which integrates both direct and indirect approaches, is often preferred due to its superior outcomes in improving cerebral blood flow (16, 17).

During acute episodes, such as strokes or hemorrhages, treatment is symptomatic and focuses on stabilizing the patient before considering surgical intervention.

The prognosis of Moyamoya disease improves significantly when surgical treatment is performed early, prior to the occurrence of major strokes or intracerebral hemorrhages (18). Direct revascularization techniques offer immediate benefits in blood flow restoration, whereas indirect techniques require months to demonstrate significant improvements. Despite treatment, patients who have experienced major strokes or hemorrhages remain at high risk of permanent neurological sequelae.

### Conclusion :

Moyamoya disease can occasionally be associated with rare conditions, such as dural arteriovenous fistulas, highlighting its clinical complexity and diversity. The biomechanical theory provides a valuable framework for unifying the pathophysiological mechanisms underlying both idiopathic and syndromic forms of the disease. A deeper understanding of these mechanisms could lead to the development of novel therapeutic strategies aimed at preventing and treating complications associated with Moyamoya disease.

### Références :

- (1) Ihara, Masafumi et al. "Moyamoya disease: diagnosis and interventions." *The Lancet. Neurology* vol. 21,8 (2022): 747-758. doi:10.1016/S1474-4422(22)00165-X
- (2) Tahir, M, and U Khan. "Moyamoya disease." *QJM : monthly journal of the Association of Physicians* vol. 109,12 (2016): 815-816. doi:10.1093/qjmed/hcw196
- (3) Zhang, Xin et al. "Progression in Moyamoya Disease: Clinical Features, Neuroimaging Evaluation, and Treatment." *Current neuropharmacology* vol. 20,2 (2022): 292-308. doi:10.2174/1570159X19666210716114016
- (4) Ibrahim, David M et al. "Moyamoya disease in children." *Child's nervous system : ChNS : official journal of the International Society for Pediatric Neurosurgery* vol. 26,10 (2010): 1297-308. doi:10.1007/s00381-010-1209-8
- (5) Gonzalez, Nestor R et al. "Adult Moyamoya Disease and Syndrome: Current Perspectives and Future Directions: A Scientific Statement From the American Heart Association/American Stroke Association." *Stroke* vol. 54,10 (2023): e465-e479. doi:10.1161/STR.0000000000000443
- (6) Scott, R Michael, and Edward R Smith. "Moyamoya disease and moyamoya syndrome." *The New England journal of medicine* vol. 360,12 (2009): 1226-37. doi:10.1056/NEJMra0804622
- (7) Peña-Tapia, P G et al. "Enfermedad de moyamoya" [Moyamoya disease]. *Revista de neurologia* vol. 43,5 (2006): 287-94.
- (8) Park, Young Seok et al. "The role of VEGF and KDR polymorphisms in moyamoya disease and collateral revascularization." *PloS one* vol. 7,10 (2012): e47158. doi:10.1371/journal.pone.0047158
- (9) Matsuo, Muneaki et al. "Vulnerability to shear stress caused by altered peri-endothelial matrix is a key feature of Moyamoya disease." *Scientific reports* vol. 11,1 1552. 15 Jan. 2021, doi:10.1038/s41598-021-81282-9
- (10) Mertens, R et al. "The Genetic Basis of Moyamoya Disease." *Translational stroke research* vol. 13,1 (2022): 25-45. doi:10.1007/s12975-021-00940-2

- (11) Bang, Oh Young et al. "Moyamoya Disease and Spectrums of RNF213 Vasculopathy." *Translational stroke research* vol. 11,4 (2020): 580-589. doi:10.1007/s12975-019-00743-6
- (12) Velo, Mariano et al. "Moyamoya Vasculopathy: Cause, Clinical Manifestations, Neuroradiologic Features, and Surgical Management." *World neurosurgery* vol. 159 (2022): 409-425. doi:10.1016/j.wneu.2021.11.026
- (13) Funaki, Takeshi. *No shinkei geka. Neurological surgery* vol. 49,2 (2021): 262-270. doi:10.11477/mf.1436204387
- (14) Kuroda, Satoshi et al. "Diagnostic Criteria for Moyamoya Disease - 2021 Revised Version." *Neurologia medico-chirurgica* vol. 62,7 (2022): 307-312. doi:10.2176/jns-nmc.2022-0072
- (15) Kuroda, Satoshi. *No shinkei geka. Neurological surgery* vol. 50,4 (2022): 806-818. doi:10.11477/mf.1436204624
- (16) Kuroda, Satoshi, and Kiyohiro Houkin. "Bypass surgery for moyamoya disease: concept and essence of surgical techniques." *Neurologia medico-chirurgica* vol. 52,5 (2012): 287-94. doi:10.2176/nmc.52.287
- (17) Hara, Shoko, and Tadashi Nariai. *No shinkei geka. Neurological surgery* vol. 50,4 (2022): 826-838. doi:10.11477/mf.1436204626
- (18) Li, Qifeng et al. "Meta-Analysis of Prognosis of Different Treatments for Symptomatic Moyamoya Disease." *World neurosurgery* vol. 127 (2019): 354-361. doi:10.1016/j.wneu.2019.04.062