


# Jana Publication & Research

## A comparative study of accuracy of FAST vs CECT abdomen in blunt trauma abdomen patients with Solid Organ Injury

 07

 BioTech

 Institut Seni Indonesia Surakarta

---

### Document Details

Submission ID

trn:oid::1:3201388588

Submission Date

Apr 1, 2025, 11:52 AM GMT+7

Download Date

Apr 1, 2025, 12:35 PM GMT+7

File Name

IJAR-50835.docx

File Size

159.2 KB

8 Pages

1,833 Words

10,060 Characters

# 15% Overall Similarity





The combined total of all matches, including overlapping sources, for each database.

## Filtered from the Report




- ▶ Bibliography
- ▶ Quoted Text

---

## Match Groups

-  **22 Not Cited or Quoted 14%**  
Matches with neither in-text citation nor quotation marks
-  **2 Missing Quotations 1%**  
Matches that are still very similar to source material
-  **0 Missing Citation 0%**  
Matches that have quotation marks, but no in-text citation
-  **0 Cited and Quoted 0%**  
Matches with in-text citation present, but no quotation marks

## Top Sources

- 13%  Internet sources
- 11%  Publications
- 0%  Submitted works (Student Papers)

### Match Groups

- **22 Not Cited or Quoted 14%**  
Matches with neither in-text citation nor quotation marks
- **2 Missing Quotations 1%**  
Matches that are still very similar to source material
- **0 Missing Citation 0%**  
Matches that have quotation marks, but no in-text citation
- **0 Cited and Quoted 0%**  
Matches with in-text citation present, but no quotation marks

### Top Sources

- 13% Internet sources
- 11% Publications
- 0% Submitted works (Student Papers)

### Top Sources

The sources with the highest number of matches within the submission. Overlapping sources will not be displayed.

1	Internet	<b>ejrn.springeropen.com</b>	1%
2	Internet	<b>www.researchgate.net</b>	1%
3	Internet	<b>impactfactor.org</b>	1%
4	Internet	<b>www.worldwidejournals.com</b>	1%
5	Publication	<b>P. E. Pepe, L. P. Roppolo, R. L. Fowler. "Chapter 12 Prehospital Endotracheal Intub...</b>	1%
6	Internet	<b>www.ijrcog.org</b>	<1%
7	Internet	<b>ijars.net</b>	<1%
8	Internet	<b>sportdocbox.com</b>	<1%
9	Publication	<b>Zoë A Smith, Darryl Wood. "Emergency focussed assessment with sonography in ...</b>	<1%
10	Publication	<b>Maria A. Parker, Bryson G. Hicks, Matt Kaili, Aaron Silver et al. "The Lipliner Sign: ...</b>	<1%

11	Internet	rfppl.co.in	<1%
12	Internet	jder.ssu.ac.ir	<1%
13	Internet	medicolegalupdate.org	<1%
14	Internet	discovery.researcher.life	<1%
15	Internet	journalmedicalthesis.com	<1%
16	Internet	www.annaliitalianidichirurgia.it	<1%
17	Internet	www.ijmse.com	<1%
18	Internet	www.pjs.com.pk	<1%
19	Internet	www.wjpmr.com	<1%
20	Publication	Reuven Rabinovici, Heidi Lee Frankel, Orlando Kirton. "Trauma, Critical Care and ...	<1%

## “A comparative study of accuracy of FAST vs CECT abdomen in blunt trauma abdomen patients with Solid Organ Injury”

### ABSTRACT

**Aim** -To compare the accuracy of FAST vs CECT abdomen in patients presenting with blunt trauma abdomen with solid organ injuries. **Objectives** - To determine the sensitivity and specificity of FAST and CECT abdomen in blunt trauma abdomen patients with solid organ injuries and to evaluate the management of blunt trauma abdomen patients according to FAST and CECT abdomen finding. **Material and Methodology** - 100 patients above 18 years came to emergency /casualty of department of surgery of Dr BRAM Hospital Raipur with history of blunt trauma to abdomen with positive clinical findings were investigated for FAST and CECT abdomen. Data is collected prospectively from FAST scans and CECT scans conducted in blunt trauma abdomen (BTA) patients. Outcome of treatment were analysed according to FAST and CECT findings. **Result** – In this study, the most common age group affected were between 26 -35 years of age in which 88 patients were male and 12 patients were female. Most cases were due to road traffic accident followed by fall from height. Out of 100, organ injury was detected in 88 patients by FAST and in 98 patients by CECT scan. 94 patients were managed conservatively and 6 patients were managed by surgery. **Conclusion** - CECT is more accurate than e-FAST in detecting abdominal injuries, offering higher sensitivity and specificity, especially for minor injuries and retroperitoneal damage. While e-FAST is useful for initial evaluation, CECT remains the gold standard for definitive diagnosis and management in blunt trauma abdomen patients.

### INTRODUCTION

Blunt abdominal trauma is a major cause of injury, primarily resulting from road traffic accidents, which account for 75-80% of cases. Other causes include falls from height, assaults, sports injuries, and bomb blasts. Despite its high frequency, blunt abdominal trauma is often difficult to detect early, making it prone to misdiagnosis. Delays in diagnosis, inadequate treatment, and associated injuries (such as head, thorax, and pelvic trauma) contribute to the high morbidity and mortality rates.

The **Focused Assessment with Sonography for Trauma (FAST)** is a key diagnostic tool, especially for hemodynamically unstable patients. According to the ATLS (Advanced Trauma Life Support) protocol, FAST should be performed immediately after the primary survey. It is a rapid, non-invasive procedure (taking only about 5 minutes) that identifies free fluid in the abdomen, which can indicate internal bleeding. FAST has a high specificity (98-100%) and accuracy (98-99%) for detecting free fluid and significantly reduces the time needed for diagnosis and intervention. Additionally, it is safe for pregnant women and children and can be performed serially without radiation or contrast agents. Despite these advantages, FAST has limitations. It has lower sensitivity (73-88%) for detecting peritoneal fluid and is not effective in detecting retroperitoneal fluid or organ lesions. Its accuracy can be affected by factors such as the operator's skill and difficulty in obese patients.

**CT scans**, considered the gold standard for diagnosing blunt abdominal trauma, can provide more detailed information and detect organ injuries and retroperitoneal fluid. However, CT has its own drawbacks, including potential artifacts due to patient movement, risk of renal toxicity, radiation exposure, and higher costs compared to FAST.

In summary, while FAST is a valuable tool for rapid diagnosis, its limitations make CT the preferred imaging modality for detailed assessment, despite the associated risks.

## MATERIAL AND METHODOLOGY

The current study is a **prospective analytical study** conducted from **February 2023 to April 2024** in the **Department of General Surgery at Dr. B.R.A.M. Hospital and Pt. J.N.M. Medical College, Raipur**. The study lasted for **one year and two months**.

**Study type** - Prospective analytical study.

**Study Site** - Department of General Surgery, Dr. B.R.A.M. Hospital, Raipur.

**Study Population:** Patients who met the inclusion criteria for blunt abdominal trauma.

**Sample Size:** 100 patients.

**Inclusion Criteria:** all patients Over 18 years of age presenting to the emergency department with a history of blunt trauma abdomen and solid organ injuries.

**Exclusion Criteria:** Patients showing obvious signs of hollow viscus injury, Patients who refused to consent for participation and hemodynamically unstable patients who could not undergo CECT.

**Methodology:** The study received clearance from the Institute of Scientific Committee and Ethical Committee and conducted in **Dr BRAM Hospital and Pt. J.N.M. Medical College, Raipur**. Prior to the study, detailed explanations of the study methodology and interventions were provided to patients and their attendants. Consent was taken, and queries were addressed. Hemodynamically unstable patients received resuscitation, including airway management, normal breathing, and maintenance of adequate blood pressure and saturation. These patients were then sent for **FAST (Focused Assessment with Sonography for Trauma)** and **CECT (Contrast-Enhanced Computed Tomography)** examinations. Patients requiring surgical intervention were taken for **exploratory laparotomy**. Patients who did not require surgery were managed conservatively in the **ICU**, with strict immobilization for 3-4 days.

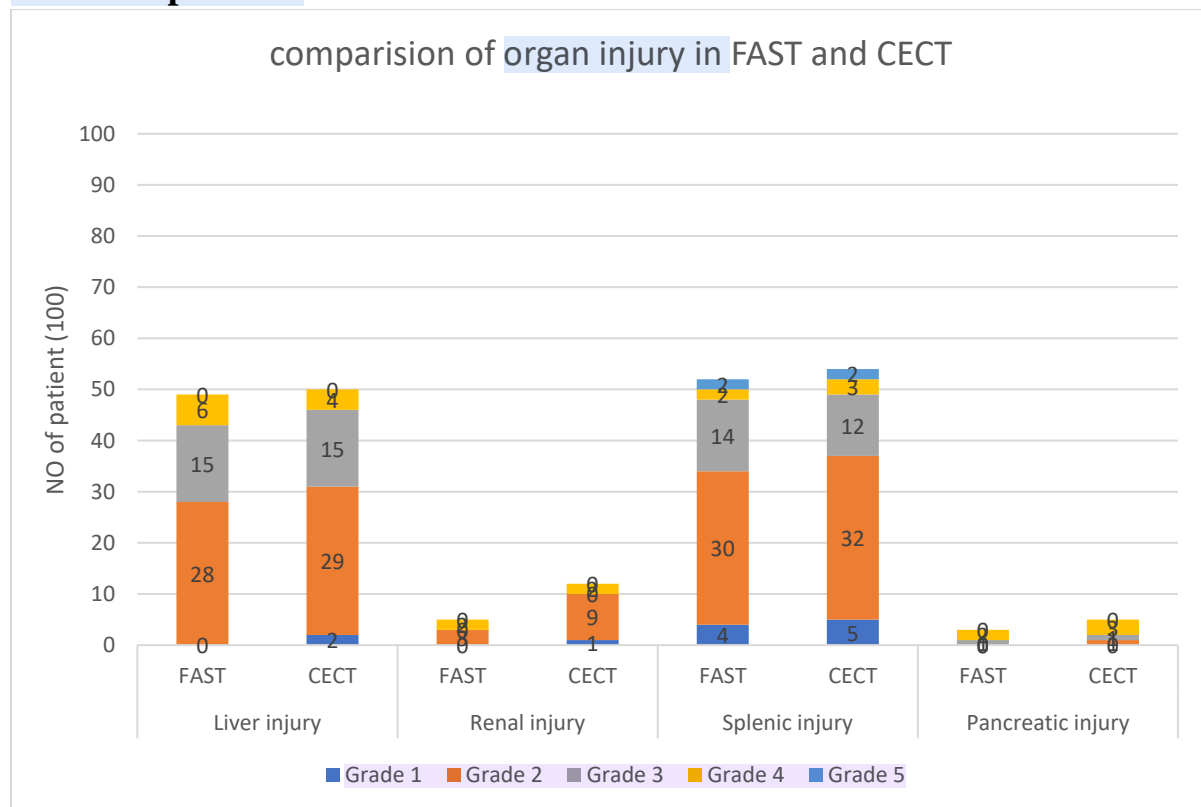
## RESULTS AND OBSERVATIONS

Out of 100, CECT detected 98 cases of organ injury, while FAST detected 88. This suggests that CECT is slightly more sensitive at identifying organ injuries than FAST. CECT has a significantly higher detection rate for organ injuries compared to FAST. Only 2 missed cases for CECT compared to 12 for FAST further highlights the higher sensitivity of CECT. Table 1 compares the severity of organ injuries detected using FAST and CECT in blunt trauma abdomen patients. CECT has a more comprehensive detection rate, especially for retroperitoneal collections and injuries like renal and pancreatic injuries.

**Table 1: Comparison of organ injury in FAST and CECT in blunt trauma abdomen patients.**

Variable	Liver injury		Renal injury		Splenic injury		Pancreatic injury	
	FAST	CECT	FAST	CECT	FAST	CECT	FAST	CECT
<b>Grade 1</b>	0	2	0	1	4	5	0	0
<b>Grade 2</b>	28	29	3	9	30	32	0	1
<b>Grade 3</b>	15	15	0	0	14	12	1	1
<b>Grade 4</b>	6	4	2	2	2	3	2	3
<b>Grade 5</b>	0	0	0	0	2	2	0	0
<b>TOTAL</b>	49	50	5	12	52	54	3	5

**Graph 1: Comparison of organ injury in FAST and CECT in blunt trauma abdomen patients.**

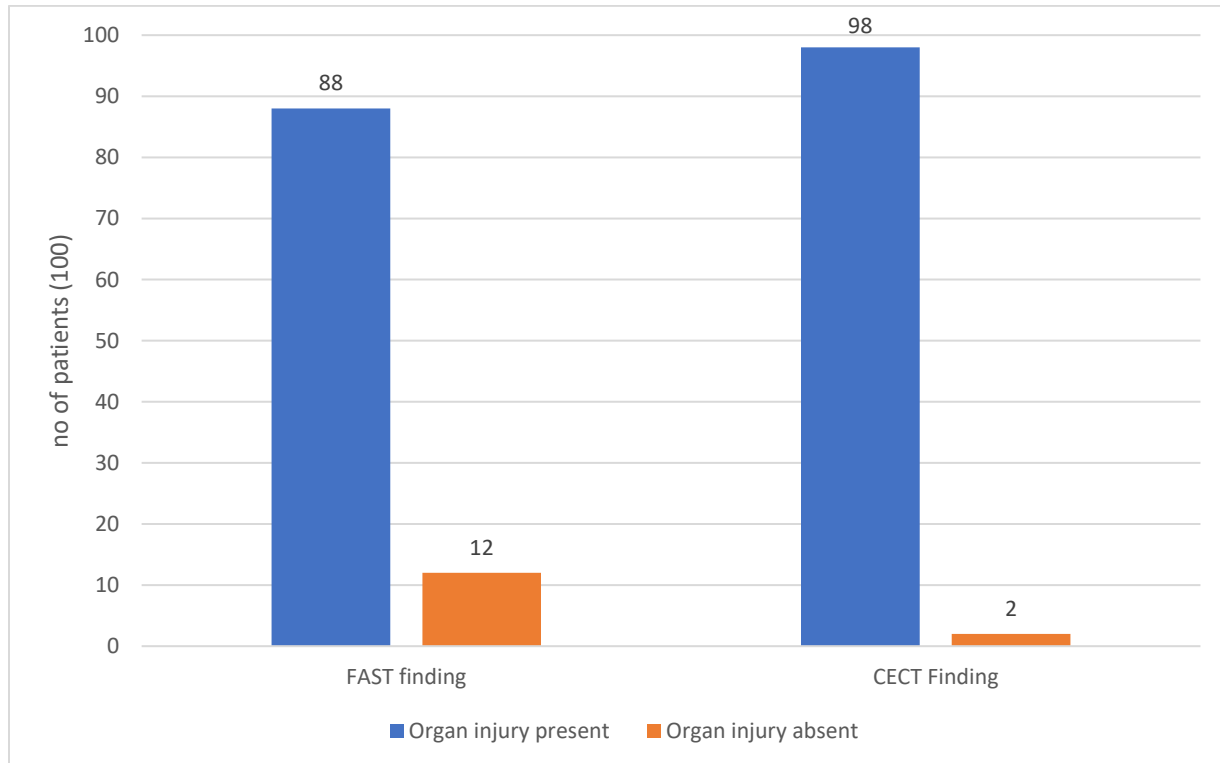


**Table 2: COMPARISON OF FAST AND CECT FINDINGS IN BLUNT TRAUMA ABDOMEN PATIENTS.**

Variable	FAST finding	CECT Finding
Organ injury present	88	98

Organ injury absent	12	2
---------------------	----	---

**Graph 2: Comparison of FAST and CECT findings in blunt trauma abdomen patients.**



This data shows FAST detected organ injury in 88 patients while 12 were missed and in CT, 98 patients were detected with organ injury and only 2 were missed.

**Table 3: Sensitivity of CT Scan.**

	CECT finding		Total
	Organ injury present	Organ injury absent	



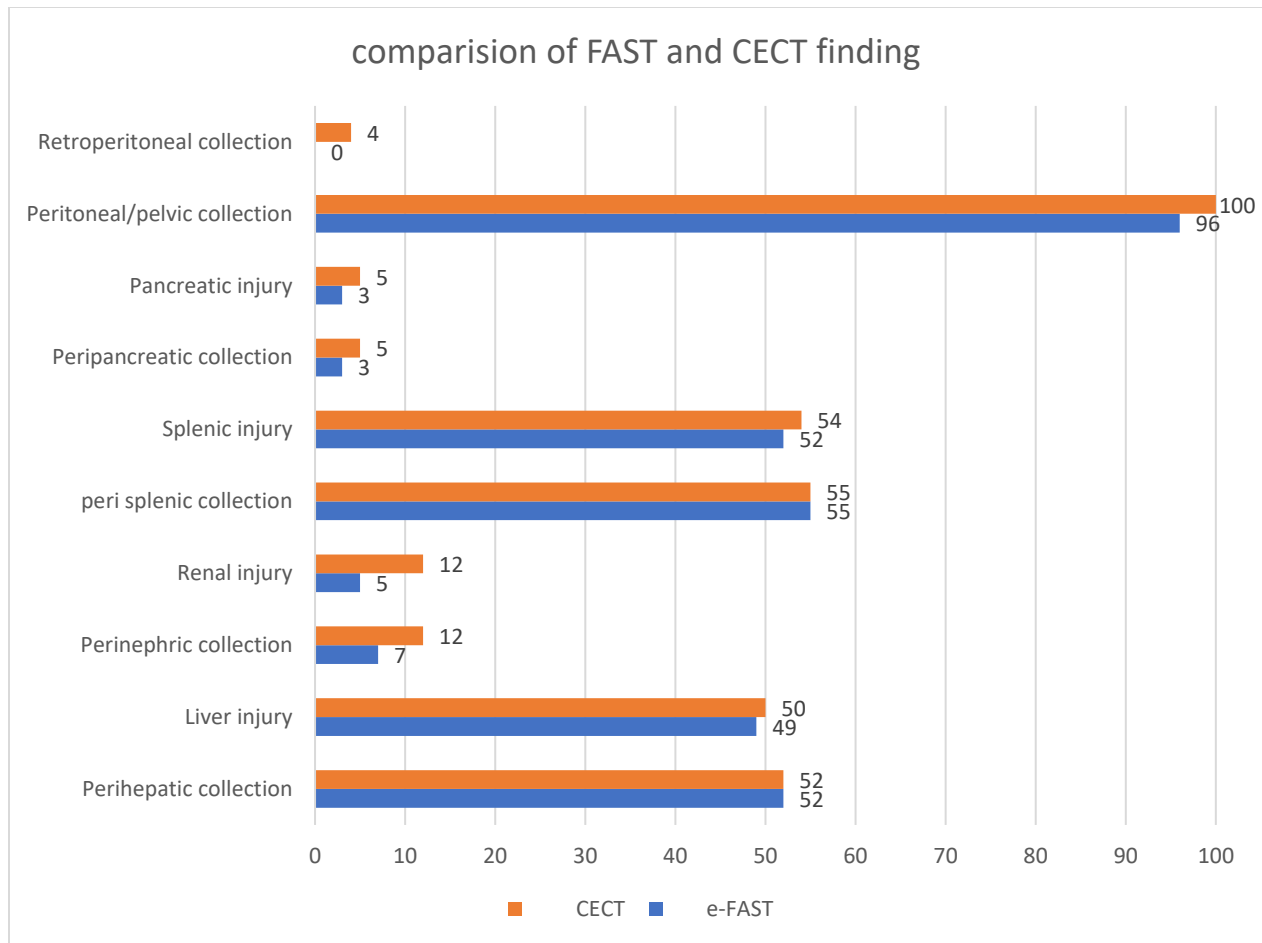
<b>FAST Findings</b>	Organ injury present	87	1	88
	Organ injury absent	11	1	12
	<b>Total</b>	98	2	100

Sensitivity -88.78%, Specificity 50.00%, PPV-98.86%, NPP-8.33% p-value is 0.006.

**Table 4: e-FAST and CECT findings in blunt trauma abdomen patients.**

<b>Variable</b>	<b>e-FAST</b>	<b>CECT</b>
Perihepatic collection	52	52
Liver injury	49	50
Perinephric collection	7	12
Renal injury	5	12
peri splenic collection	55	55
Splenic injury	52	54
Peripancreatic collection	3	5
Pancreatic injury	3	5
Peritoneal/pelvic collection	96	100
Retroperitoneal collection	0	4

**Graph 3: e-FAST and CECT findings in blunt trauma abdomen patients.**



## DISCUSSION

1 This study compares the accuracy of e-FAST (Focused Assessment with Sonography for Trauma) and CECT (Contrast-Enhanced Computed Tomography) in diagnosing blunt trauma abdomen injuries. Most patients were young males (18-35 years) involved in road traffic accidents. X-rays, e-FAST, and CECT were used to detect associated injuries. e-FAST was effective in identifying peritoneal fluid in 96% of cases, while CECT identified fluid in all patients, including cases missed by e-FAST. CECT also detected more organ injuries (98 vs. 88 cases), including mild liver and renal injuries and retroperitoneal injuries not visible on e-FAST. Most patients (94%) were managed conservatively, with 6% requiring surgery. The length of stay varied based on injury severity, and there were 3 deaths due to associated injuries.

## CONCLUSION

CECT is more accurate than e-FAST in detecting abdominal injuries, offering higher sensitivity and specificity, especially for minor injuries and retroperitoneal damage. While e-FAST is useful for initial evaluation, CECT remains the gold standard for definitive diagnosis and management in blunt trauma abdomen patients.

## LIMITATIONS

- Sample size was small which is insufficient to provide comparative data for this type of study.
- The study was done in a single center so hospital bias cannot be ruled out.
- Both diagnostic methods are observer-dependent.

## REFERENCES

1. Khanna R, Khanna S, Singh P, Puneet, Khanna AK. Spectrum of blunt abdominal trauma in Varanasi; Quart J.1999 Mar&Jun;35(1, 2):25-28.
2. World Health Organization (WHO). Injuries and Violence: The Facts 2014. Geneva, Switzerland: WHO Press; 2014.
3. Karamercan A, Yilmaz TU, Karamercan MA, Blunt abdominal trauma: evaluation of diagnostic options and surgical outcomes. Travma Acil Cerrahi Derg. 2008;14(3):205-10.
4. Singh M, Kumar A, Verma AK, Kumar S, Singh AK. Abdominal organ involvement in blunt injuries. Journal of Indian Academy of Forensic Medicine. 2012;34(1):24-6.
5. Pandey VK, Shahi HP, Singh R, Pratap P. A prospective study of injury pattern and outcome of blunt trauma abdomen patients in a tertiary care hospital in eastern part of India. International Surgery Journal. 2020 Jul 23;7(8):2557-62.
6. American College of Surgeons Committee on Trauma (2004) Advanced trauma life support program for doctors, 7th edn. American College of Surgeons, Chicago.
7. Patel NY, Riherd JM. Focused assessment with sonography for trauma: methods, accuracy, and indications. Surg Clin North Am 2011;91(1):195-207.
8. Vadodariya K, Hathila VP, Mehta K. The role of computed tomography in management of blunt abdominal trauma conducted at Government tertiary hospital, Western India: A prospective observational study. Int J Sci Res. 2014;3(2):368-70.
9. Lateef AU, Khan AA, Rana MM. Comparison of efficacy of FAST and CT scan in patients with blunt abdominal trauma. Annals of Punjab Medical College. 2019 Feb 6;13(1):10-3.
10. Hanif H, Bibi T, Raja R, Malik S. Accuracy of FAST (Focused Abdominal Sonography in Trauma) scan in diagnosis of significant abdominal trauma using CT abdomen as gold standard. The Professional Medical Journal. 2020 Oct 10;27(10):2067-71.
11. Nayak SR, Yeola MP, Nayak SR, Kamath K, Raghuwanshi PS. Role of focused assessment with sonography for trauma in the assessment of blunt abdominal trauma– a review. Journal of Evolution of Medical and Dental Sciences. 2021 Jan 4;10(1):45-51.

12. Jamal AF, Muhammad BS, Sadeq MG. A prospective evaluation of computerized tomography scan findings in blunt abdominal trauma. *Zanco Journal of Medical Sciences (Zanco J Med Sci)*. 2023 Apr 26;27(1):64-73.
13. Mahendra Reddy GS, Gautam R, Shah A, Sonawane A, Abrol A, Bhadavankar A, Solanki H, Siddhartha V, Kinjalk T. Which is better?? e-Fast or contrast enhanced computed tomography in blunt abdominal trauma: An observational study in tertiary care center. *International Journal of Surgery*. 2023;7(1):70-3.
14. Mobeen A, Arshad K, Maqbool S, Mazhar R, Ahmad F, Aslam F, Yaseen A, Hussain B. Utility of Fast Scan in Blunt Abdominopelvic Trauma Patients in Lahore District. *Pakistan Journal of Medical & Health Sciences*. 2023 May 6;17(04):197.
15. Marathu K, Budigireddy J. Role of Ultrasonography and CT in the Evaluation of Blunt Abdominal Trauma-A Prospective Study. *Int J Anatomy, Radiology and Surgery*. 2019.