

# Hypercalcemia Revealing Isolated Renal Sarcoidosis

## Abstract:

Renal involvement in sarcoidosis is rare and is most often a consequence of calcium metabolism disorders or interstitial granulomatous involvement, while glomerular involvement remains exceptional. We report the case of a 56-year-old patient admitted for unexplained renal failure, associated with hypercalcemia, leukocyturia, and minimal proteinuria. A renal biopsy revealed granulomatous interstitial nephritis without caseous necrosis, along with focal areas of mild tubular necrosis. No involvement of other organs was observed. The patient was treated with corticosteroid therapy and symptomatic management of hypercalcemia, leading to a favorable outcome.

**Keywords:** Isolated Renal sarcoidosis; Granulomatous interstitial nephritis; Hypercalcemia

## Introduction:

Sarcoidosis is a multisystem granulomatous disease of unknown etiology, characterized by tissue infiltration with non-caseating tuberculoid granulomas containing multinucleated giant cells. Renal involvement remains rare, with renal failure reported in only 1–3% of patients [1-2]. We present the case of a patient with renal failure and hypercalcemia, revealing isolated renal sarcoidosis.

## Case report:

A 56-year-old patient with a history of surgery two years prior for intestinal obstruction, was admitted to the nephrology department for an etiological workup of severe kidney failure, incidentally discovered.

The patient's medical history dates back one month prior to admission, marked by the insidious onset of asthenia, which prompted a consultation in general medicine. A routine workup was performed, revealing incidentally discovered kidney failure without major hydro electrolytic disturbances. A renal ultrasound ruled out obstructive etiology.

Upon admission, the patient was hemodynamically and respiratory stable, with preserved urine output and no signs of fluid overload. The remainder of the physical examination was unremarkable.

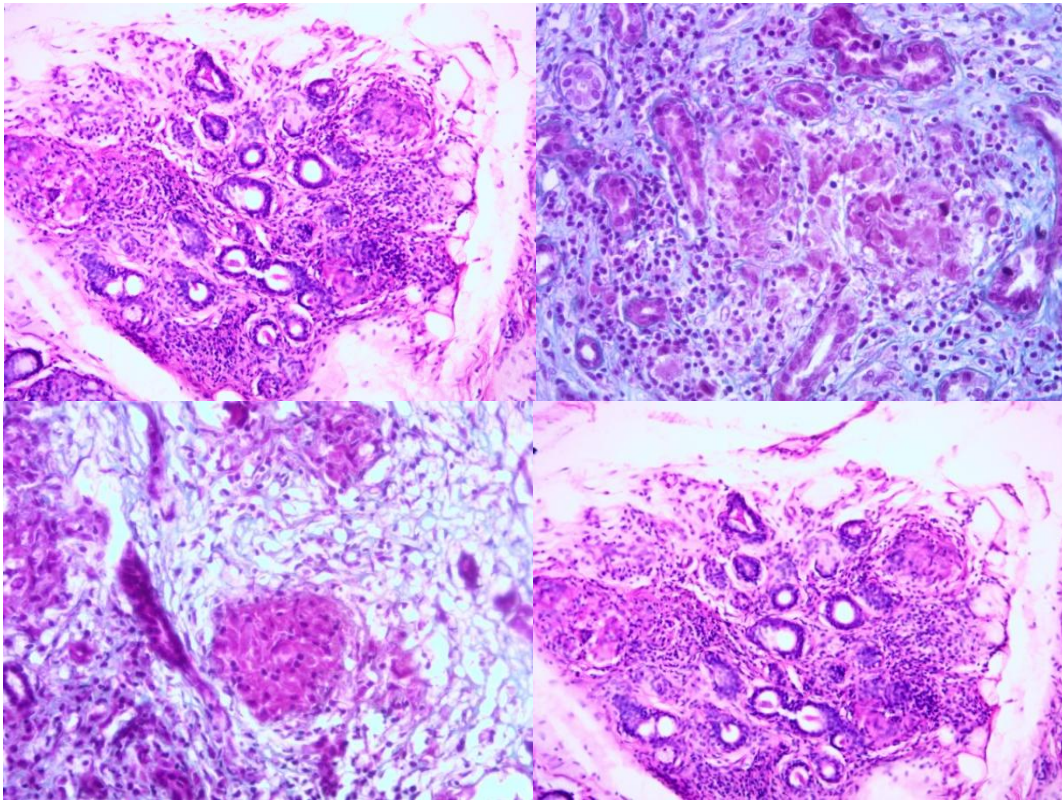
Blood tests revealed renal failure (Urea: 1.16 g/L, Creatinine: 67 mg/L) alongside with hypercalcemia (125 mg/L), hyperphosphatemia (57 mg/L) and mild proteinuria (0.3 g/day).

The ultrasound revealed two kidneys of normal size with preserved corticomedullary differentiation and no signs of excretory tract dilation.

Urine cytobacteriological analysis was sterile, showing leukocyturia but no hematuria. Plasma protein electrophoresis showed polyclonal gammaglobulinemia.

Given the unexplained acute kidney injury, a renal biopsy was performed, revealing moderate tubulointerstitial inflammation with nodular and diffuse epithelioid and multinucleated giant cell granulomas affecting the entire cortical surface, along with focal areas of mild tubular necrosis

42 (Figure 1). Direct immunofluorescence for C3, IgA, IgM, IgG, and kappa/lambda light chains was  
43 negative.  
44



45

46

47 **Figure1** : Renal biopsy fragment stained with standard techniques, showing granulomatous  
48 interstitial nephritis without caseous necrosis, along with focal areas of mild tubular necrosis.

49

50 An extension workup was initiated to search for other organ involvement. A thoraco-abdominal CT  
51 scan was normal, as were ophthalmologic and ENT examinations. Dermatologic and lymph node  
52 assessments were unremarkable. Serum Mycobacterium Tuberculosis GeneXpert was negative.  
53 Angiotensin-converting enzyme (ACE) levels were at the upper limit of normal. Immunological tests,  
54 including antinuclear antibodies (ANA), anti-double-stranded DNA (anti-dsDNA), anti-extractable  
55 nuclear antigen (anti-ENA), anti-neutrophil cytoplasmic antibodies (ANCA), and complement levels,  
56 were within normal ranges.

57

58 The patient received three consecutive daily pulses of methylprednisolone (500 mg), followed by oral  
59 corticosteroid therapy at an initial daily dose of 1 mg/kg. Additional treatment for hypercalcemia  
60 included hydration and bisphosphonates, with no need for renal replacement therapy.

61

62 The patient's condition improved progressively, with a follow-up creatinine level of 30 mg/L at two  
63 months.

64

#### 65 **Discussion:**

66

67 Renal involvement is an uncommon manifestation of sarcoidosis, with its prevalence varying across  
68 studies depending on the diagnostic methods used [3-4]. While it is typically reported in fewer than  
69 10% of cases, autopsy studies have detected granulomas in renal parenchyma in up to 25% of  
70 sarcoidosis patients [5-6].

71 The increased production of calcitriol, resulting from macrophage activation within sarcoid  
72 granulomas, leads to hypercalcemia in approximately 10% of cases and hypercalciuria in 30–45% of  
73 cases. These calcium metabolism disturbances can cause nephrocalcinosis or calcium nephrolithiasis  
74 [7].

75 Renal involvement generally occurs in patients with multiorgan sarcoidosis. However, in our case, the  
76 patient presented with isolated renal sarcoidosis. In the study by Mahevas et al. [8], renal  
77 involvement revealed sarcoidosis in most cases, whereas in 19% of cases, it developed later in the  
78 disease course.

79 Granulomatous tubulointerstitial nephritis is the most specific renal lesion in sarcoidosis. Renal injury  
80 may remain isolated for several years, as observed in our patient, but it more commonly occurs in  
81 the setting of florid multifocal sarcoidosis. Proteinuria is usually absent or minimal, while  
82 leukocyturia is often present and may be accompanied by hematuria [9].

83 Renal biopsy is essential for diagnosing granulomatous interstitial nephropathy, as it reveals  
84 interstitial lymphoid and macrophage infiltrates without glomerular or vascular lesions. Non-caseous  
85 epithelioid granulomas are highly specific but are identified in only 40% of cases. Tubular  
86 abnormalities secondary to interstitial lesions are observed in 50% of cases [10].

87 Glomerular involvement in sarcoidosis is rare but can coexist with granulomatous interstitial  
88 nephropathy. The most frequently reported glomerular pathology is membranous  
89 glomerulonephritis [11].

90 The mainstay of treatment for renal sarcoidosis is corticosteroid therapy, initiated at a dose of 1  
91 mg/kg/day [12]. Early corticosteroid initiation is crucial to prevent fibrosis. While there is no  
92 standardized treatment duration, most experts recommend prolonged therapy (at least 18 months)  
93 to reduce the risk of renal relapse.

94 For patients with hypercalcemia and hypercalciuria, dietary calcium restriction, avoidance of  
95 hypercalcemic medications, and limited sun exposure are advised. Alternative therapeutic options  
96 include chloroquine and hydroxychloroquine, which may help correct calcitriol levels. Additionally,  
97 ketoconazole (a steroidogenesis inhibitor) at a dose of 800 mg/day has been proposed as a  
98 treatment for hypercalciuria, as it reduces calcitriol synthesis [13].

99

## 100 **Conclusion:**

101

102 Our case highlights the importance of systematically assessing renal function and calcium  
103 metabolism in patients with sarcoidosis, both at initial evaluation and during follow-up. It also  
104 underscores the need to consider performing a renal biopsy in cases of renal injury with  
105 hypercalcemia in order to ensure the diagnosis of isolated renal sarcoidosis is not overlooked.

## 106 **Bibliography:**

107 [1] Duvic C, Herody M, Rossignol P, Lecoules S, Didelot F, Nedelec G. Les manifesta-  
108 tions rénales de la sarcoïdose : à propos de neuf observations. *Rev Med Interne* 1999;20:226–33.

109 [2] Muther RS, McCarron DA, Bennett WM. Renal manifestations of sarcoidosis. *Arch Intern Med*  
110 1981;141:643.

111 [3] Chapelon C, Uzzan B, Piette JC, Jacques C, Coche E, Godeau P. Sarcoido-  
112 sis in internal medicine. A cooperative study of 554 cases. *Ann Med Interne* 1984;135:125–31.

113 [4] Wirnsberger RM, de Vries J, Wouters EF, Drent M. Clinical presentation of sarcoidosis in the  
114 Netherlands: an epidemiological study. *Neth J Med* 1998;53:53–60.

- 115 [5] Branson JH, Oark JH. Sarcoidosis hepatic involvement: presentation of a case with fatal liver  
116 involvement including autopsy findings and review of the evidence for sarcoid involvement of the  
117 liver as found in the literature. *Ann Intern Med* 1954;40:111–45.
- 118 [6] Longscope WT, Freiman DG. A study of sarcoidosis based on a combined investigation of 160  
119 cases including 30 autopsies from the John Hopkins Hospital and Massachusetts General Hospital.  
120 *Medicine (Baltimore)* 1952;31:1–132.
- 121 [7] Ikeda A, Nagai S, Kitaichi M, Hayashi M, Hamada K, Shigematsu M, et al. Sarcoidosis with  
122 granulomatous interstitial nephritis: report of three cases. *Intern Med* 2001;40:241–5.
- 123 [8] Mahevas M, Lescure FX, Boffa JJ, Delastour V, Belenfant X, Chapelon C, et al. Renal sarcoidosis:  
124 clinical, laboratory, and histologic presentation and outcome in 47 patients. *Medicine (Baltimore)*  
125 2009;88:98.
- 126 [9] Awasthi A, Nada R, Malhotra P, Goel R, Joshi K. Fatal renal failure as the first manifestation of  
127 sarcoidosis diagnosed on necropsy in a young man: a case report. *J Clin Pathol* 2004;57:1101–3.
- 128 [10] Laroche M, Ader JL, Mazieres B. Tubulopathie sarcoïdique simulant une hyperparathyroïdie.  
129 *Press Med* 1990;19:1548.
- 130 [11] Khan I, Simpson J, Catto G, MacLeod A. Membranous nephropathy and granulomatous  
131 interstitial nephritis in sarcoidosis. *Nephron* 1994;66:459–61.
- 132 [12] Berliner AR, Haas M, Choi MJ. Sarcoidosis: the nephrologist's perspective. *Am J Kidney Dis*  
133 2006;48:856–70.
- 134 [13] Sharma OP. Hypercalcemia in granulomatous disorders: a clinical review. *Curr Opin Pulm Med*  
135 2000;6:442–7.

136

137

138

139

140 **Conflict of Interest Statement:** The authors declare that they have no conflicts of  
141 interest.