

# Jana Publication & Research

## ACCESSORY PAROTID GLAND TUMOR EXCISION – PRESENTING AS MID CHEEK MASS

 03 BioTech Institut Seni Indonesia Surakarta

---

### Document Details

**Submission ID**

trn:oid:::1:3219568510

**Submission Date**

Apr 17, 2025, 11:42 AM GMT+7

**Download Date**

Apr 17, 2025, 1:13 PM GMT+7

**File Name**

IJAR-51068.docx

**File Size**

1.0 MB

**6 Pages****1,629 Words****9,445 Characters**





# 28% Overall Similarity

The combined total of all matches, including overlapping sources, for each database.




## Filtered from the Report

- Bibliography
- Quoted Text

## Match Groups

-  **31 Not Cited or Quoted 22%**  
Matches with neither in-text citation nor quotation marks
-  **7 Missing Quotations 5%**  
Matches that are still very similar to source material
-  **0 Missing Citation 0%**  
Matches that have quotation marks, but no in-text citation
-  **0 Cited and Quoted 0%**  
Matches with in-text citation present, but no quotation marks

## Top Sources

- 23%  Internet sources
- 19%  Publications
- 0%  Submitted works (Student Papers)

## Match Groups

- 31 Not Cited or Quoted 22%**  
Matches with neither in-text citation nor quotation marks
- 7 Missing Quotations 5%**  
Matches that are still very similar to source material
- 0 Missing Citation 0%**  
Matches that have quotation marks, but no in-text citation
- 0 Cited and Quoted 0%**  
Matches with in-text citation present, but no quotation marks

## Top Sources

- 23%** Internet sources
- 19%** Publications
- 0%** Submitted works (Student Papers)

## Top Sources

The sources with the highest number of matches within the submission. Overlapping sources will not be displayed.

<b>1</b>	Internet	<b>www.ncbi.nlm.nih.gov</b>	<b>12%</b>
<b>2</b>	Internet	<b>indexarticles.com</b>	<b>2%</b>
<b>3</b>	Internet	<b>www.hindawi.com</b>	<b>1%</b>
<b>4</b>	Internet	<b>repozitorij.unizg.hr</b>	<b>1%</b>
<b>5</b>	Publication	<b>Management of Extended Parotid Tumors, 2016.</b>	<b>1%</b>
<b>6</b>	Internet	<b>www.ijcrisurgery.com</b>	<b>1%</b>
<b>7</b>	Internet	<b>www.ejmcm.com</b>	<b>&lt;1%</b>
<b>8</b>	Internet	<b>assets-eu.researchsquare.com</b>	<b>&lt;1%</b>
<b>9</b>	Internet	<b>journals.lww.com</b>	<b>&lt;1%</b>
<b>10</b>	Internet	<b>healthdocbox.com</b>	<b>&lt;1%</b>

11	Internet	onlinelibrary.wiley.com	<1%
12	Publication	Darrell A. Klotz, John U. Coniglio. "Prudent Management of the Mid-Cheek Mass: ...	<1%
13	Publication	Zachary T. Boyd. "Pediatric salivary gland imaging", Pediatric Radiology, 03/27/20...	<1%
14	Publication	SM El-Khateeb, AE Abou-Khalaf, MM Farid. "A prospective study of three diagnosti...	<1%
15	Internet	banglajol.info	<1%
16	Internet	www.ijmhr.org	<1%
17	Publication	Bettina Hohlweg-Majert. "Salivary Gland Lipomas", Journal of Craniofacial Surger...	<1%
18	Publication	Guowen Sun, Qingang Hu, Enyi Tang, Xudong Yang, Xiaofeng Huang. "Diagnosis ...	<1%
19	Publication	I. Luksic, M. Mamic, P. Sutton. "Management of accessory parotid gland tumours: ...	<1%

# ACCESSORY PAROTID GLAND TUMOR EXCISION – PRESENTING AS MID CHEEK MASS

## Abstract

## Introduction

Accessory parotid gland tumors only account for approximately 1% of all parotid gland tumors. The tumors of such glands are rare but have a higher predisposition to turn malignant (26 – 50%). These tumors usually present as painless, mid cheek mass which can be confirmed using radiological and histological investigations. We report a case of pleomorphic adenoma of the accessory parotid gland.

## Case presentation

A 47 year old male presented with painless, swelling in the mid cheek region for the past 6 months. On examination, the mass measured approximately 2x2 cm, was non-tender, firm, mobile in both axes, and not adherent to the underlying structures. Ultrasonography (USG) and Fine needle aspiration cytology (FNAC) confirmed the diagnosis of pleomorphic adenoma of the accessory parotid gland. Managed surgically by mid cheek incision and excision of the accessory parotid gland tumor. Post operatively, there were no signs of facial nerve palsy. Pathologic examination was consistent with Pleomorphic adenoma.

## BACKGROUND & INTRODUCTION

Accessory parotid glands are a common anatomical variation found in a significant portion of the general population (21-61%)<sup>[1,2]</sup>. They are usually found anterior to the parotid gland near or above the Stensons duct and connected to it by its own ducts. However Accessory parotid gland tumors only account for approximately 1% of all parotid gland tumors<sup>[3]</sup>. The tumors of such glands are rare but have a higher predisposition to turn malignant (26 – 50%) compared to tumors of parotid gland (18.5%)<sup>[4]</sup>. These tumors usually present as painless, mid cheek mass which can be confirmed using radiological and histological investigations. The treatment consists of Modified Blairs incisions, mid cheek or transoral incisions followed by the complete removal of the accessory parotid tumor.

## CASE PRESENTATION

A 47-year-old male with a medical history of type 2 diabetes mellitus and hypertension, currently under medication, presented with a complaint of a right mid-cheek mass that had been present for the past six months. The swelling was gradually increasing in size, painless, and slow growing. There was no noticeable change in size when chewing or eating. On examination, the mass measured approximately 2x2 cm, was non-tender, firm, mobile in both axes, and not adherent to the underlying structures.

2 An ultrasound of the right cheek revealed a hypoechoic lesion in the accessory parotid gland, with posterior acoustic enhancement. The lesion measured 2.2x1.4 cm and was likely an adenoma. No calcifications, cystic changes, or vascularity were observed. The right parotid gland appeared normal.

Fine needle aspiration cytology (FNAC) of the right preauricular swelling revealed a cellular smear showing sheets of ductal epithelial cells along with numerous myoepithelial cells embedded in a fibrillary chondromyxoid stroma, which was consistent with a diagnosis of pleomorphic adenoma. This lesion was classified as a Milan category 4A benign neoplasm.

1 After obtaining the patient's consent, which included a discussion about the risk of injury to the distal branches of the facial nerve, surgical intervention was planned. A 4 cm horizontal incision was made over the skin overlying the tumor, and the mass was carefully dissected from the underlying masseter muscle while preserving the distal facial nerve branches.

1 Excision of accessory parotid tumour was performed and sent for histopathological analysis.

1 The patient tolerated the surgery well, with no facial nerve injury or paralysis noted postoperatively, and only a minimal scar was visible on the face. Histopathological examination confirmed the lesion to be a pleomorphic adenoma measuring 1.7\*1.5\*1.3cm, confirming the preoperative diagnosis.

## DISCUSSION

13 The parotid gland, the earliest major salivary gland to develop, originates from an ectodermal groove around the 6th week of fetal development. In contrast, the accessory parotid gland is a common anatomical variant consisting of additional salivary tissue, typically situated in front of the main parotid gland<sup>[5]</sup>. Accessory parotid tumors can pose significant diagnostic and surgical challenges for clinicians. Typically, these tumors manifest as a palpable mass, often found in the peri-parotid area. In some cases, these tumors may encircle the parotid duct, leading to obstruction of glandular function. When this occurs, patients may experience symptoms associated with ductal obstruction, such as swelling or discomfort. Furthermore, the facial nerve's complex course means that these masses may lie between the buccal and zygomatic branches, complicating their identification and removal. The differential diagnosis of these tumors includes benign and malignant accessory parotid gland tumors, parotid cysts, neural tumors, metastatic diseases, Kimura disease, and vascular lesions like hemangiomas. Pleomorphic adenoma, as seen in this case, is the most common tumor found in the accessory parotid gland, followed by mucoepidermoid carcinoma<sup>[6-8]</sup>.

5 To accurately diagnose these tumors, a thorough evaluation is essential, involving careful physical examination, radiological studies, and fine needle aspiration cytology (FNAC). Ultrasonography is often the first imaging technique of choice, as it helps identify the tumor's origin, visualize the parotid duct, and detect any ductal obstructions like calculi or calcifications. Contrast-enhanced computed tomography (CECT) is highly effective in assessing the tumor's internal structure, distinguishing solid from cystic masses, and evaluating vascularity. While Magnetic Resonance Imaging (MRI) offers superior soft tissue

8 resolution, making it ideal for the detailed evaluation of salivary gland tumors, CECT remains valuable in certain cases. Since ultrasound and FNAC were sufficient for diagnosis in our study, we did not require the patient to undergo further tests. However, in more complex cases, contrast-enhanced CT and MRI are recommended to assess bony and soft tissue invasions, respectively <sup>[6]</sup>.

1 FNAC provides the definitive histological diagnosis, helping determine whether the tumor is benign or malignant, which guides the surgical approach <sup>[10]</sup>. There are several surgical options for resecting tumors in the accessory parotid lobe, including the standard parotidectomy incision, direct cheek incision, and transoral incision. These approaches often involve extracapsular dissection, which is an effective technique for removing the tumor while preserving surrounding tissues.

1 The modified Blair's incision, a common approach for parotidectomy, offers good exposure and minimizes functional and cosmetic deformities, with a lower risk of facial nerve injury compared to the cheek incision. Studies have shown a 7% incidence of temporary facial palsy with the modified Blair's incision, while cheek incisions are associated with a higher 40% incidence of nerve damage <sup>[7]</sup>. The recovery of the facial nerve is typically better with the Blair's incision. The transoral approach is particularly useful for tumors located anteriorly, as it avoids facial scars and offers direct access to the parotid duct. However, it carries a higher risk of facial nerve injury, like the cheek incision.

1 In our experience, the standard parotidectomy incision, involving extensive facial nerve exposure, can sometimes cause unnecessary nerve branch injuries. In contrast, the cheek incision offers a quicker, less invasive procedure, resulting in fewer complications and reduced tumour implantation <sup>[11]</sup>, making it the preferred approach in this case. These practical considerations are crucial when deciding the appropriate surgical approach for accessory parotid tumours. It is often emphasized that the distal branches of the facial nerve should be identified before beginning the dissection of the tumour from its bed. Our experience aligns with this principle, highlighting the importance of carefully identifying and preserving the facial nerve branches during tumour removal. This cautious approach helps to

minimize unnecessary exposure to the peripheral nerves, thereby reducing the risk of damage.

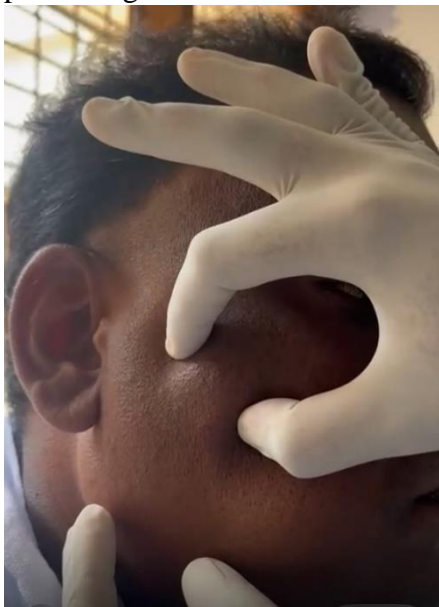

Fig 1: A well-defined mid cheek swelling on the right side of the face



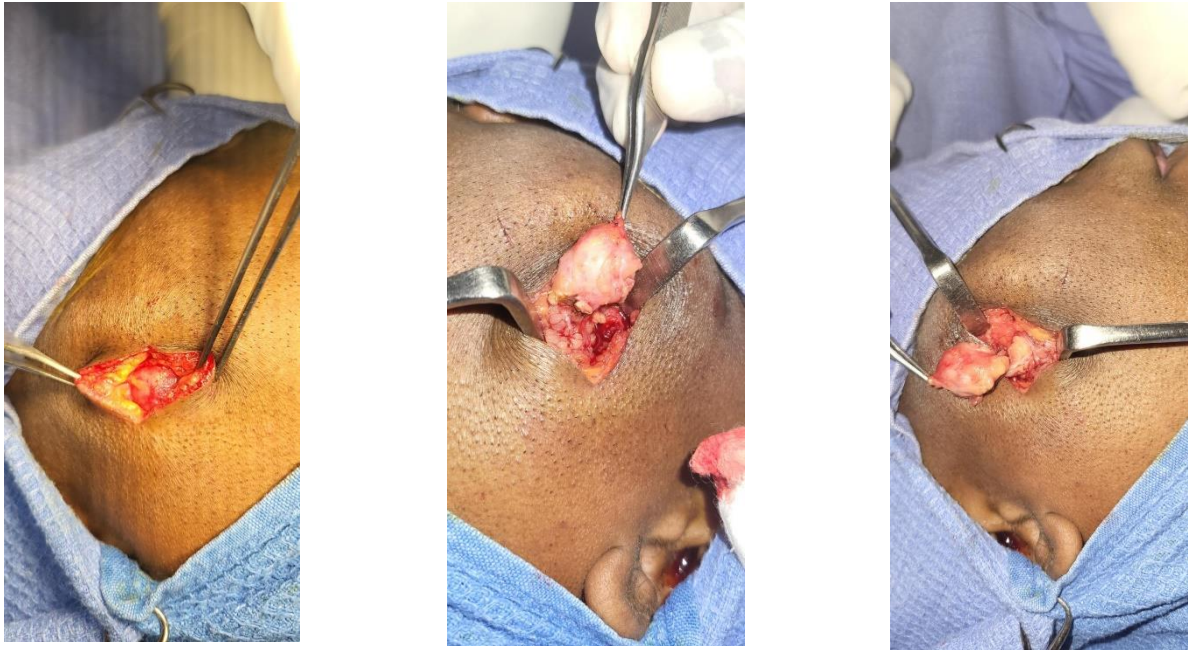


Fig 2: Intra operative finding of right accessory parotid tumour through right cheek incision

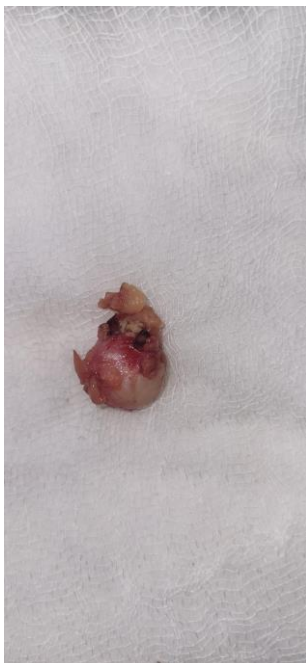
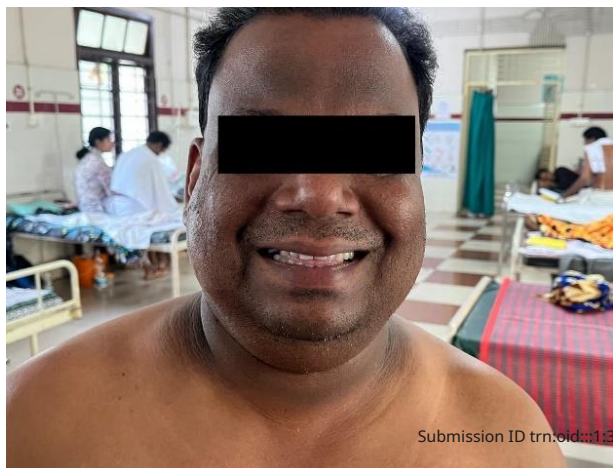
Fig 3: Accessory parotid gland excision specimen





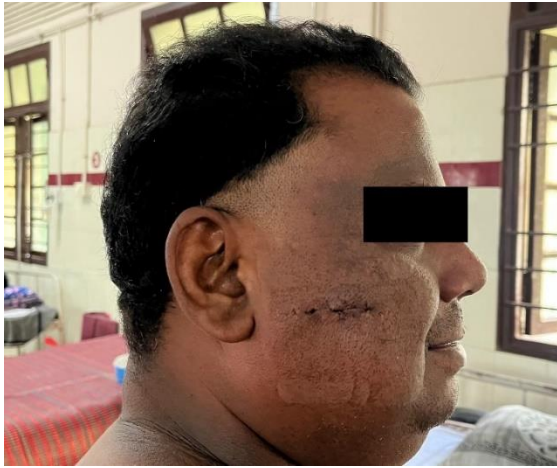

Fig 4: Post operative status of the patient with cheek scar and no postoperative facial paralysis

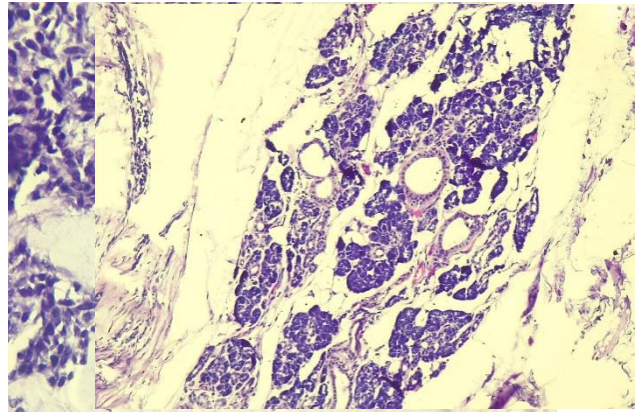


Fig 5: H&E-stained specimen of Accessory Parotid gland tumor (triphasic tumor) showing ductal (epithelial), myoepithelial and stromal components. The stromal component is typically chondromyxoid or myxoid.

## CONCLUSION:

Accessory parotid gland tumors account for approximately 1% of all parotid gland tumors. However, the higher incidence of them turning malignant is a concern for the surgeon. The diagnostic aids helping to provide the diagnosis include : USG, CECT, MRI and definitive diagnosis by FNAC. The procedure followed in this case study includes a mid-cheek incision followed by excision of the accessory parotid gland. Post operatively, there was no evidence of facial palsy. Histopathological examination confirmed the lesion to be a pleomorphic adenoma, confirming the preoperative diagnosis. The rarity of this tumor and the limited available literature should highlight the need for further research on this condition.

## REFERENCES:

1. Frommer J. The human accessory parotid gland: Its incidence, nature, and significance. Oral Surg Oral Med Oral Pathol 1977;43:671

2. Jinbo Y, Sugamata A, Nomoto T. Surgical management of neoplasms of accessory parotid gland – A report of two cases. *J Jpn Plast Reconstr Surg* 1984;4:326-32.
3. Afify SE, Maynard JD. Tumors of the accessory lobe of the parotid gland. *Postgrad Med J* 1992;68:461-2.-6.
4. Singh RP, Alaani A, Oakley R, Jeannon JP, Simo R: Outcomes and surgical tips in the management of accessory parotid lobe tumours. *Adv Oral Maxillofac Surg*. 2021, 1:100016. 10.1016/j.adoms.2021.100016
5. Bialek EJ, Jakubowski W, Zajkowski P, Szopinski KT, Osmolski A. US of the major salivary glands: anatomy and spatial relationships, pathologic conditions, and pitfalls. *Radiographics*. 2006 May-Jun;26(3):745-63.
6. Hamano T, Okami K, Sekine M, Odagiri K, Onuki J, Iida M, et al. A case of accessory parotid gland tumor. *Tokai J Exp Clin Med* 2004;29:131-3.
7. Johnson FE, Spiro RH. Tumors arising in accessory parotid tissue. *Am J Surg* 1966;165:183-9.
8. Perzik SL, White IL. Surgical management of preauricular tumors of the accessory parotid apparatus. *Am J Surg* 1966;112:498-503.
9. Polayes IM, Rankow RM. Cysts, masses, and tumors of the accessory parotid gland. *Plast Reconstr Surg* 1979;64:17-23.
10. Sun, Guowen et al. *Journal of Oral and Maxillofacial surgery*, Volume 67, Issue 7, 1520- 1523
11. Hamza M, Anand G (February 13, 2023) Resection of Accessory Parotid Gland Tumors: A Multidisciplinary Feat and Review of Literature. *Cureus* 15(2): e34945. DOI 10.7759/cureus.34945