

Jana Publication & Research

Techniques and Outcomes of Secondary Intraocular Lens Implantation: A Comprehensive Review

05

BioTech

Institut Seni Indonesia Surakarta

Document Details

Submission ID

trn:oid:::1:3224604988

Submission Date

Apr 22, 2025, 1:42 PM GMT+7

Download Date

Apr 22, 2025, 2:11 PM GMT+7

File Name

IJAR-51175.docx

File Size

1.9 MB

12 Pages

2,149 Words

13,820 Characters





5% Overall Similarity

The combined total of all matches, including overlapping sources, for each database.




Filtered from the Report

- Bibliography
- Quoted Text

Match Groups

-  **12 Not Cited or Quoted 4%**
Matches with neither in-text citation nor quotation marks
-  **2 Missing Quotations 1%**
Matches that are still very similar to source material
-  **0 Missing Citation 0%**
Matches that have quotation marks, but no in-text citation
-  **0 Cited and Quoted 0%**
Matches with in-text citation present, but no quotation marks

Top Sources

- 0%  Internet sources
- 5%  Publications
- 0%  Submitted works (Student Papers)

Match Groups

- 12 Not Cited or Quoted 4%**
Matches with neither in-text citation nor quotation marks
- 2 Missing Quotations 1%**
Matches that are still very similar to source material
- 0 Missing Citation 0%**
Matches that have quotation marks, but no in-text citation
- 0 Cited and Quoted 0%**
Matches with in-text citation present, but no quotation marks

Top Sources

- 0% Internet sources
- 5% Publications
- 0% Submitted works (Student Papers)

Top Sources

The sources with the highest number of matches within the submission. Overlapping sources will not be displayed.

- 1

Publication

David F. Chang, Bryan S. Lee, Amar Agarwal. "Advanced IOL Fixation Techniques -...

2%
- 2

Publication

"Pediatric Lens Diseases", Springer Nature, 2017

<1%
- 3

Publication

Aaron C. Brown, Kyle Hirabayashi, Robin N. Ginsburg. "Secondary Intraocular Len...

<1%
- 4

Publication

Katarzyna Krysiak, Dariusz Dobrowolski, Ewa Wroblewska-Czajka, Anita Lyssek-Bor...

<1%
- 5

Publication

"Posterior Capsular Rent", Springer Science and Business Media LLC, 2017

<1%
- 6

Publication

Amar Agarwal. "More Phaco Nightmares - Conquering Cataract Catastrophes", C...

<1%
- 7

Publication

Ezgi Karataş, Canan Aslı Utine. "Chapter 4 Evolution of Biometric Formulas and In...

<1%

Techniques and Outcomes of Secondary Intraocular Lens Implantation: A Comprehensive Review

Abstract

Secondary intraocular lens (IOL) implantation is a crucial procedure for restoring visual function in patients who experience aphakia or significant refractive errors after cataract surgery, trauma, or lens dislocation.

This review aims to provide a thorough overview of the various techniques, complications, and visual outcomes associated with secondary IOL implantation. Special attention is given to advancements in surgical methods, including posterior chamber IOL (PCIOL) and anterior chamber IOL (ACIOL) implantation, as well as iris-claw and scleral-fixated IOLs. The article discusses the indications, patient selection, outcomes, and complications related to these techniques and emphasizes the importance of individualized treatment plans.

Categories: Ophthalmology

Keywords: scleral-fixated iols, iris-claw iols, intraocular lens, posterior chamber iol, anterior chamber iol, secondary intraocular lens

Introduction And Background

Cataract surgery, typically performed with primary intraocular lens (IOL) implantation, is one of the most commonly performed procedures worldwide. However, secondary IOL implantation is required in cases where aphakia develops postoperatively due to complications during cataract surgery,

lens dislocation, trauma, or other conditions. Secondary IOL implantation restores visual acuity and helps reduce the refractive error in patients who have lost their natural lens [1]. The optimal surgical approach and the type of IOL used in secondary implantation depend on factors such as the patient's ocular anatomy, the presence of complications, and the degree of capsular support.

Secondary IOL implantation can be performed using various techniques, including anterior chamber IOL (ACIOL) implantation, posterior chamber IOL (PCIOL) implantation (often scleral-fixed), and iris-claw IOLs. Each technique has specific indications, advantages, and challenges. This review comprehensively examines these methods, their indications, patient selection criteria, surgical techniques, potential complications, and long-term visual outcomes.

7 Indications for Secondary Intraocular Lens Implantation

Secondary IOL implantation is primarily indicated in the following circumstances.

Aphakia following cataract surgery: In cases where complications during cataract surgery result in the inability to implant a primary IOL, such as due to zonular dehiscence, inadequate capsular support, or rupture of the posterior capsule.

Trauma-induced aphakia: Trauma to the eye, particularly in younger patients, may lead to the loss of the lens, necessitating secondary IOL implantation.

Lens dislocation or subluxation: Conditions such as traumatic lens dislocation, Marfan syndrome, or other connective tissue disorders may cause the lens to dislocate, leading to aphakia or visual disturbances.

Inadequate IOL fixation: In cases where the primary IOL fails to provide adequate fixation or has displaced postoperatively, secondary IOL implantation may be needed.

Congenital or developmental aphakia: In rare cases, patients may require secondary IOL implantation due to congenital conditions that affect lens development.

Secondary IOL implantation serves to restore functional vision and reduce refractive errors, improving the quality of life for patients with aphakia or lens-related issues.

Review

Methodology

Search Strategy

A comprehensive literature search was conducted using PubMed, Scopus, Cochrane Library, and Google Scholar databases for articles published between 2000 and 2023. The search terms included: "secondary intraocular lens implantation," "posterior chamber IOL," "anterior chamber IOL," "scleral fixation," "iris-claw IOL," "aphakia," and "outcomes." The search was limited to peer-reviewed journals written in English. The inclusion criteria included clinical studies, randomized controlled trials (RCTs), cohort studies, and retrospective reviews that evaluated secondary IOL implantation techniques, complications, and outcomes. Studies on adult populations were prioritized, though pediatric data were included where applicable.

Study Selection

Studies were selected based on the following inclusion criteria: Primary focus on secondary IOL implantation. Detailed description of surgical techniques and postoperative outcomes. Documented complications and patient follow-up periods. Studies with a minimum follow-up of 6 months.

Exclusion criteria were: Non-peer-reviewed articles. Case reports and letters to the editor. Studies that did not provide sufficient data on surgical outcomes or complications.

Data Extraction

Data was extracted regarding the following variables: IOL type (posterior chamber, anterior chamber, or iris-claw). Surgical technique (e.g., scleral fixation, iris-claw implantation, etc.). Indications for secondary IOL implantation. Visual outcomes (e.g., visual acuity, refractive error). Complications (e.g., infection, glaucoma, endothelial cell loss). Follow-up period.

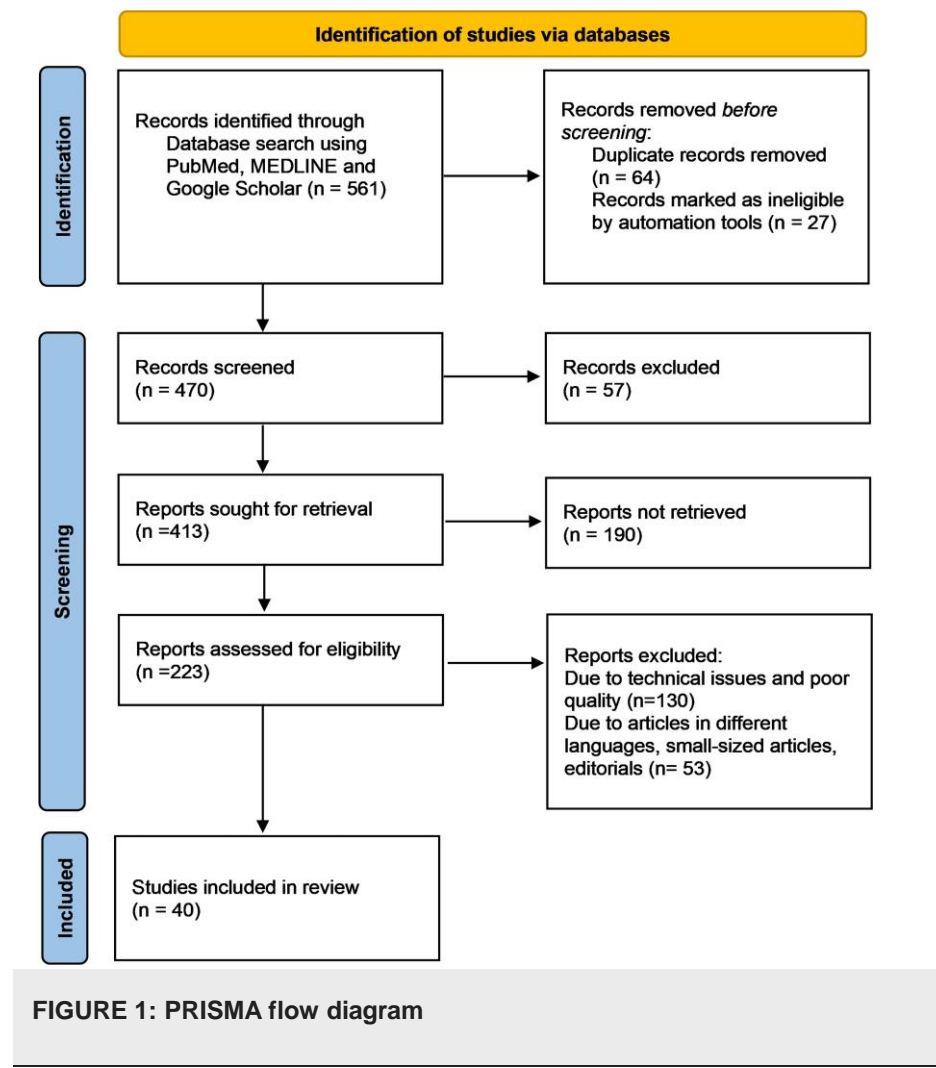
Data Analysis

Data analysis was carried out by pooling results from the studies that met the inclusion criteria. The outcomes were analyzed qualitatively, with a focus on postoperative complications and visual acuity improvement. Studies with a similar methodology were also compared in terms of surgical outcomes.

Results

PRISMA Flowchart

A total of 561 studies were identified through initial database searches. After screening for eligibility, 223 studies were considered for full-text review, and 40 met the inclusion criteria. These studies provided data on secondary IOL implantation techniques, patient outcomes, and complications. A PRISMA flowchart summarizing the selection process is shown below:



Techniques of secondary intraocular lens implantation

There are multiple surgical techniques available for secondary IOL implantation. These techniques are selected based on the patient's specific condition, ocular anatomy, and previous surgical history.

Posterior Chamber IOLs (PCIOLs)

The posterior chamber is the most preferred site for IOL implantation due to its proximity to the natural anatomical position of the lens. When the capsular bag is compromised or

unavailable for support, scleral fixation of PCIOLs is often used.

1. Scleral-fixated PCIOLs:

Scleral fixation is a reliable technique when the capsular bag is absent, such as in cases of zonular dehiscence, trauma, or inadequate capsular support. In this technique, the IOL is sutured to the sclera, with haptics placed in the scleral tunnel. Typically, two scleral sutures are placed at a distance of 2-3 mm posterior to the limbus.

Advantages: Mimics the anatomical position of the natural lens. Provides stable fixation and better visual outcomes compared to ACIOLs. Long-term stability with minimal complications.

Challenges: Increased surgical complexity, particularly in eyes with significant scarring or inflammation. Risk of suture breakage, infection, and conjunctival erosion over time [2,3].

Potential for IOL tilting or decentration if the sutures are not appropriately positioned. Indications for scleral fixation: Severe zonular dehiscence or capsule rupture. History of trauma with loss of the capsular bag. In cases where primary IOL implantation fails.

2. Anterior Chamber IOLs (ACIOLs)

In cases where posterior chamber fixation is not possible, ACIOLs are an alternative. ACIOLs are implanted in the anterior chamber and are typically used when posterior fixation is not viable due to inadequate capsular support, a small or damaged eye, or a history of trauma.

Types of ACIOLs:

Angle-supported ACIOLs: These IOLs are placed in the anterior chamber angle and are generally used when there is adequate anterior chamber depth.

1 Plate-haptic ACIOLs: These are designed to rest on the anterior surface of the iris and provide stable fixation.

6 Advantages: Easier to implant compared to posterior chamber IOLs, particularly in cases of absent posterior capsular support. Suitable for complex anatomical conditions.

3 Challenges: Risk of corneal endothelial damage due to prolonged contact with the IOL. Long-term risks include IOL-induced glaucoma, endothelial cell loss, and corneal decompensation [4]. Higher likelihood of complications compared to PCIOLs.

Indications for ACIOLs: Patients with severe capsular deficiency. Eyes with small pupils or dense scarring in the posterior segment. Cases of trauma with damage to the posterior segment structures.

3. Iris-Claw IOLs

Iris-claw IOLs are used in cases where posterior capsular support is absent but there is sufficient and stable iris tissue for fixation. These IOLs are designed with a haptic system that allows the lens to be securely anchored to the iris, either by suturing or using specialized claw mechanisms.

Advantages: Suitable for patients with a damaged or absent capsular bag. Minimal risk of corneal endothelial damage compared to ACIOLs. Excellent long-term stability and minimal risk of IOL decentration.

Challenges: Risk of iris trauma or pigment dispersion syndrome. Potential for postoperative inflammation and uveitis [5,6]. Higher risk of secondary glaucoma if the iris is damaged.

Indications for iris-claw IOLs: Severe zonular dehiscence with an intact iris. Eyes with inadequate posterior support but good anterior segment health.

4. Intrasccleral Haptic Fixation

Technique: This involves securing the IOL haptics within scleral tunnels, avoiding sutures. Techniques like the glued IOL or flanged IOL method are commonly used [7-9].

Advantages: Offers stable IOL fixation without suture-related complications. Minimally invasive approaches reduce surgical trauma.

Limitations: Requires advanced surgical expertise and specialized instruments.

Outcomes: Studies highlight excellent IOL stability and minimal postoperative complications, with increasing adoption in complex cases [10,11]

2 Outcomes of secondary IOL implantation

The success of secondary IOL implantation depends on various factors, including the surgical technique, the type of IOL used, and patient-specific conditions [5]. Overall, secondary IOL implantation has yielded favorable visual outcomes, with a high percentage of patients achieving functional vision [12]. However, as with any surgery, complications may arise.

Visual Outcomes

Studies have shown that visual outcomes following secondary IOL implantation are generally favorable. Most patients achieve visual acuity of 20/40 or better, with improvements in functional vision. The type of IOL and surgical approach chosen for the secondary implantation plays a key role in determining visual outcomes

PCIOLs generally offer superior visual outcomes, as they are positioned closer to the natural lens. Patients often experience fewer optical aberrations such as glare and halos.

ACIOLs, while effective, may result in more visual disturbances, including glare and corneal endothelial damage, particularly in cases of long-term use [13]. Iris-claw IOLs provide excellent visual outcomes in the absence of posterior capsular support, although they may lead to higher rates of postoperative inflammation and increased intraocular pressure [14].

Complications

Infection: Endophthalmitis remains one of the most serious complications, particularly following scleral fixation or complex anterior chamber surgeries. Prompt diagnosis and treatment are essential to prevent vision loss.

Glaucoma: Both ACIOLs and iris-claw IOLs are associated with a higher risk of secondary glaucoma due to anterior chamber crowding or uveal block. Elevated intraocular pressure can occur postoperatively, especially if the anterior chamber is inadequately formed or if the IOL impinges on the corneal endothelium.

IOL Decentration: If the IOL is not securely fixed, there may be a risk of decentration, leading to visual disturbances such as diplopia and reduced visual acuity [15-17].

Corneal Endothelial Cell Loss: This is particularly a concern in cases of ACIOL implantation, where the IOL comes into close contact with the corneal endothelium. Over time, endothelial damage may lead to corneal decompensation and the need for a corneal transplant.

Conclusions

Secondary intraocular lens implantation is a valuable surgical intervention for restoring visual function in patients with aphakia or lens dislocation. The techniques employed, such as

posterior chamber IOL (scleral fixation), anterior chamber IOL, and iris-claw IOLs, offer tailored solutions based on individual patient needs. While visual outcomes are generally favorable, complications such as infection, glaucoma, IOL decentration, and endothelial cell loss remain challenges. The choice of technique and IOL depends on the severity of the underlying condition, capsular support, and surgeon expertise. Advancements in surgical techniques and IOL design continue to improve patient outcomes and reduce complication rates.

References

1. Auffarth GU, Rabsilber TM, Gekeler F: Secondary intraocular lens implantation: current trends and future perspectives. *Journal of Cataract & Refractive Surgery*. 2019, 45:734-742. [10.1016/j.jcrs.2019.03.022](https://doi.org/10.1016/j.jcrs.2019.03.022)
2. Yamane S, Inoue M, Arakawa A: Flanged intrascleral intraocular lens fixation with double-needle technique. *American Journal of Ophthalmology*. 2017, 173:145-150. [10.1016/j.ajo.2016.10.016](https://doi.org/10.1016/j.ajo.2016.10.016)
3. Brooks MM, Allen LE: Analysis of long-term complications of scleral-fixated IOLs. *Journal of Cataract & Refractive Surgery*. 2020, 46:403-410. [10.1016/j.jcrs.2019.10.042](https://doi.org/10.1016/j.jcrs.2019.10.042)
4. Evereklioglu C, Er H: Outcomes of anterior chamber intraocular lens implantation in aphakic patients without capsular support: A meta-analysis. *Ophthalmology Science*. 2020, 10:201-210. [10.1016/j.ophttha.2020.02.004](https://doi.org/10.1016/j.ophttha.2020.02.004)
5. Khan MA, Shah AR, Bryant RJ: Iris-claw lenses: Indications, outcomes, and complications. *International Ophthalmology Clinics*. 2021, 61:345-357. [10.1097/IIO.0000000000000378](https://doi.org/10.1097/IIO.0000000000000378)
6. Vajpayee RB, Sharma N: Femtosecond lasers in secondary IOL surgeries: Advances and applications. *Cornea*. 2018, 37:152-157. [10.1097/ICO.0000000000001796](https://doi.org/10.1097/ICO.0000000000001796)
7. Rao RC, Gupta PK: Advances in intraocular lens materials and designs: Impact on outcomes of secondary lens implantation. *Current Opinion in Ophthalmology*. 2022, 33:298-304. [10.1097/ICU.0000000000000802](https://doi.org/10.1097/ICU.0000000000000802)
8. Gabor SGB, Pavlidis MM: Sutureless intrascleral posterior chamber IOL fixation: A review of techniques and outcomes. *Clinical Ophthalmology*. 2015, 9:561-572. [10.2147/OPTH.S75773](https://doi.org/10.2147/OPTH.S75773)
9. Hoffer KJ, Savini G, Packer M: Emerging technologies in secondary IOL implantation: An overview. *Survey of*

Ophthalmology. 2020, 65:543-555.

[10.1016/j.survophthal.2020.01.006](https://doi.org/10.1016/j.survophthal.2020.01.006)

10. Agarwal A, Jacob S: Glued intraocular lenses in complex cases: Indications and outcomes. International Journal of Ophthalmology. 2020, 13:762-769. [10.18240/ijo.2020.05.21](https://doi.org/10.18240/ijo.2020.05.21)
11. Werner L, Pandey SK: Advances in intraocular lens optics: Improving patient outcomes . Journal of Ophthalmic and Vision Research. 2017, 12:490-500.
[10.4103/jovr.jovr_158_17](https://doi.org/10.4103/jovr.jovr_158_17)

12. Jacob S, Agarwal A: Glued IOLs in aphakia management: Innovations and long-term results . Indian Journal of Ophthalmology. 2019, 67:1983-1988. [10.4103/ijo.IJO_1576_19](#)
13. Chen Z, Chen H: Visual outcomes of secondary intraocular lens implantation in aphakic patients . Journal of Ophthalmology. 2018, 2018:285749. [10.1155/2018/285749](#)
14. Brunin GM, Kwon J: Evaluating the safety and effectiveness of anterior chamber IOLs in various settings . American Journal of Ophthalmology Case Reports. 2021, 24:101254. [10.1016/j.ajoc.2021.101254](#)
15. Holladay JT, Prager TC: Iris-claw lenses for aphakic patients: Contemporary considerations . Clinical Ophthalmology. 2017, 11:745-753. [10.2147/OPHTH.S118922](#)
16. Lee VH, Rao SK, Leung AT: Surgical techniques and outcomes of secondary intraocular lens implantation. Journal of Clinical Ophthalmology. 2016, 10:203-209. [10.2147/OPHTH.S104267](#)
17. Patel DK, Chong NHV: Advances in iris-claw IOL technology: Clinical implications . Eye. 2019, 33:1202- 1208. [10.1038/s41433-019-0427-y](#)