

Knee pigmented villonodular synovitis with an atypical multi-system syndrome : case report

Table of Contents

Authors.....	1
Keywords	2
Highlights	2
Background	2
Case presentation	3
Patient information	3
Demographic details	3
Past medical and surgical history	3
Family history	3
Presentation.....	3
Timeline	3
Clinical findings	3
Diagnostic Assessment	5
Diagnostic assessments	5
Diagnostic reasoning.....	8
Management	8
Medical management.....	8
Surgical management	9
Discussion	9
Conclusion	10
Citations	11
Declaration of competing interest	12
Statement of Ethics	13
Funding	13
Author's contribution.....	13
Data Availability Statement	13
Registration of research studies	13
Guarantor	13
Provenance and peer review	13

Keywords

Villonodular synovitis, Pigmented Villonodular synovitis, Noonan syndrome, Rasopathy, Knee synovitis, Arthritis, Pangastritis, Diabetes, Anemia, Osteoporosis, Amenorrhea, Urethrohydronephrosis, Hypoplastic amelogenesis imperfecta, case report, SCARE criteria.

Highlights

- Pigmented villonodular synovitis is still of an unknown etiology.
- This article presents a case with knee pigmented villonodular synovitis associated with an new atypical multi-systemic syndrome.
- It also presents the peculiarities of clinical and para-clinical findings.
- Our ambition is this case report would help better understand PNVS.

Background

Pigmented Villonodular Synovitis is a locally aggressive neoplastic non metastatic synovial disease characterized by joint effusions, expansion of the synovium, bony erosions, and hemosiderin deposit [1], [2].

This affection is a rare entity with an incidence 1.8 per million per year, and its etiology is not yet elaborated [3].

Pigmented villonodular synovitis has been shown to have neoplastic components. Translocations of chromosome 1p13 are present in the majority of PVNS cases with the endpoint effect of overexpressing colony-stimulating factor 1 (CSF1) [4], [5].

PNVS was associated with many syndromes such as Noonan syndrome, Rasopathies, Sweet's syndrome and Chediak-Higashi syndrome [6]–[10].

And hereby we presents a case with knee pigmented villonodular synovitis associated with an new atypical multi-systemic syndrome; Our ambition is this case report would help better understand PNVS. This report has been written in line with the SCARE criteria [11].

Case presentation

Patient information

Demographic details

The patient is a female 19 years old originating from North Africa with a BMI of 23.5, she's the 8th child of 8 sibilings (4 males, 4 females) from a non-consanguineous couple.

Past medical and surgical history

The patient was followed for type 1 diabetes with insulin injections since the age of 7 years, she was also followed for primary amenorrhea, with no history of knee trauma.

Family history

The patient has a sister that is too followed for type 1 diabetes and a mother with an anemia of unknown cause.

Presentation

The onset of the symptomatology dates back to 6 months ago with the progressive onset of a painless subacute monoarthritis of the right knee evolving in a context of apyrexia with a negative infectious anamnesis.

Moreover, the patient was referred to our hospital for abdominal pain, vomiting and hypotension.

Timeline

The patient was first diagnosed with a chronic mono arthritis of the knee and treated as a septic arthritis, then the patient has developed an acute pyelonephritis with *Pseudomonas Aeruginosae* before being transferred to our hospital for further investigations.

Clinical findings

On clinical examination, we found a short statue of 135cm, partial functional impotency, knee swelling without any inflammatory signs, an internal and posterior-anterior laxity of the knee, patellar burying, a positive patellar shock; a painless gentle active and passive mobilization of the knee with a normal vascular-nervous examination.

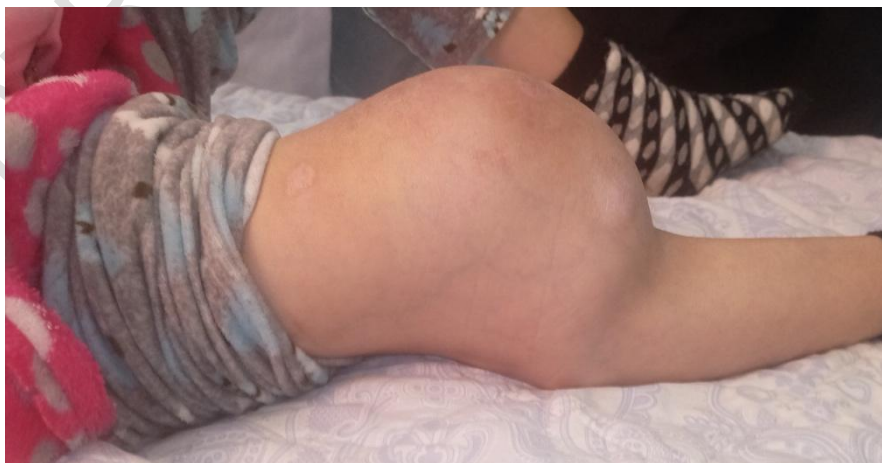

Figure 1: side view of the knee shows effusion

On abdominal examination, we found a generalized meteorism of the abdomen and a diffuse tympany without any hepatomegaly nor any splenomegaly.

The skin examination shows a diffuse depilation of glabrous skin, the Tanner score was of S1 P1.

Facial features shows an hypoplastic amelogenesis imperfecta, with no dysmorphic facial features including no hypertelorism and no short neck.

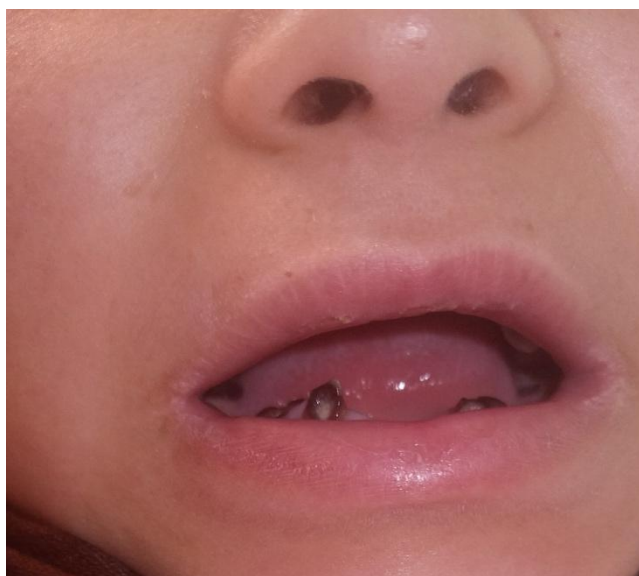

Figure 2: facial features shows amelogenesis imperfecta

Diagnostic Assessment

Diagnostic assessments

We conducted a routine blood panel, with a complete blood count with shows a normocyte normochromic anemia of 8.3g/dL, with low lymphocytes count of 840/mm, a thromocytosis of 520 to 1032G, sedimentation speed was of 123, with a normal kidney and liver function.

The phosphocalcic shows a low Vitamine D3 value of 6 ng/ml, normal PTH value of 42pg/ml, elevated phosphorous levels of 56mg/L, a high PAL value of 227 (x2 normal value).

Proteins panels shows a high 24h urine proteins value of 0.21g/L, a low blood proteins of 54.2g/L, protein electrophoresis shows a generic inflammatory mark (hypo albuminemia,

hyper alpha1 and alpha 1, and a poly clonal hyper-gamma), bone densitometry shows advanced osteoporosis with T scores of -5.6 RL and -4.5 DF.

The hormonal assessment shows a high HBA1C level of 14,3 (x2 normal value), a normal estradiol of 21.6, cortisol, T4, T3 and TSH levels and low FSH (6.3) and LH (6.5) levels.

The auto-immune panel shows a negative AAN and ACPA along with a negative auto-immune hepatitis markers.

Syphilis, hepatitis serology were all negative; Tuberculosis screening was negative using Xpert Gene PCR.

Undernutrition panel shows a low cholesterol level of 75mg/L, low blood iron level of 0.18g/L, a low levels of Protein T of 34.2 and Albumine of 17.1g/L, and a low prothrombin level of 59%, Ceoliac disease markers was all negative.

Oesogastric fibroscopy shows an erythematous pangastritis, gastric biopsy shows a minimal chronic pangastritis of minimal activity, non-atrophic without metaplasia or dysplasia without HP, duodenal biopsy shows a subacute non-specific duodenitis.

Cervical ultrasound shows a thyroid hypotrophy with thyroiditis, abdominal ultrasound shows an atrophic uterus of impubescent appearance, with an ascites of moderate abundance.

Pituitary MRI shows a 3.6 mm pituitary microadenoma on the anterolateral side of the right pituitary fin in T1 isosignal, T2 hypersignal with late enhancement after gadolinium injection.

CT scan shows minimal alveolar pneumopathy, minimal bilateral ureterohydronephrosis, bladder with minimal circumferential parietal thickness of 6mm, 17cm of hepatomegaly and moderate ascites.

The skeletal X-ray shows a persistence of the conjugation cartilage with diffuse demineralization.

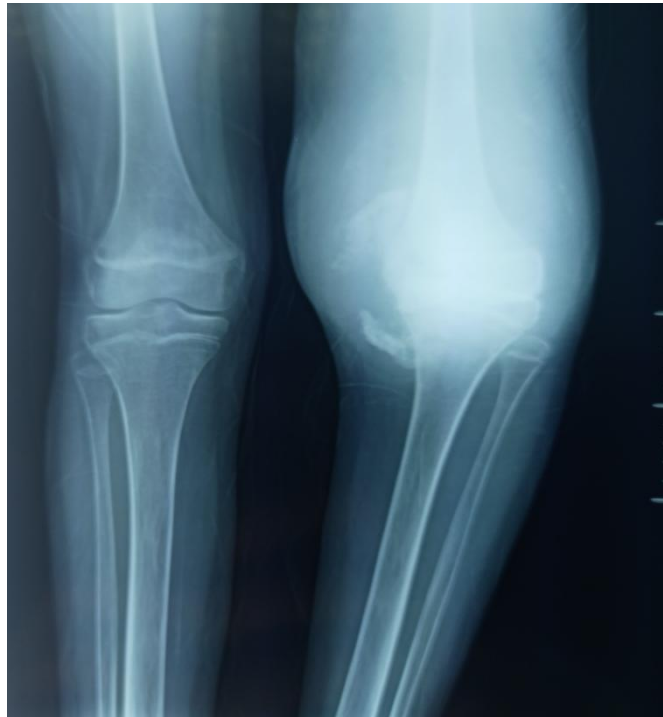

Figure 3: X ray of the knee

Knee X-ray shows swelling of the PM with calcifications, whereas Knee CT scan shows a collection of the quadricipital recess with polymorphous peripheral calcifications with posterior femorotibial dislocation with medial remodeling.

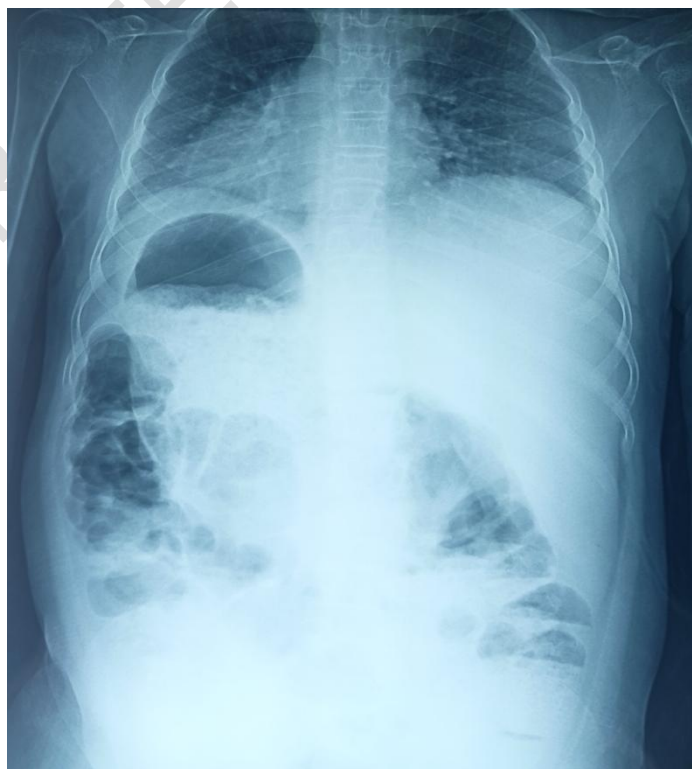

Figure 4: X ray of the abdomen

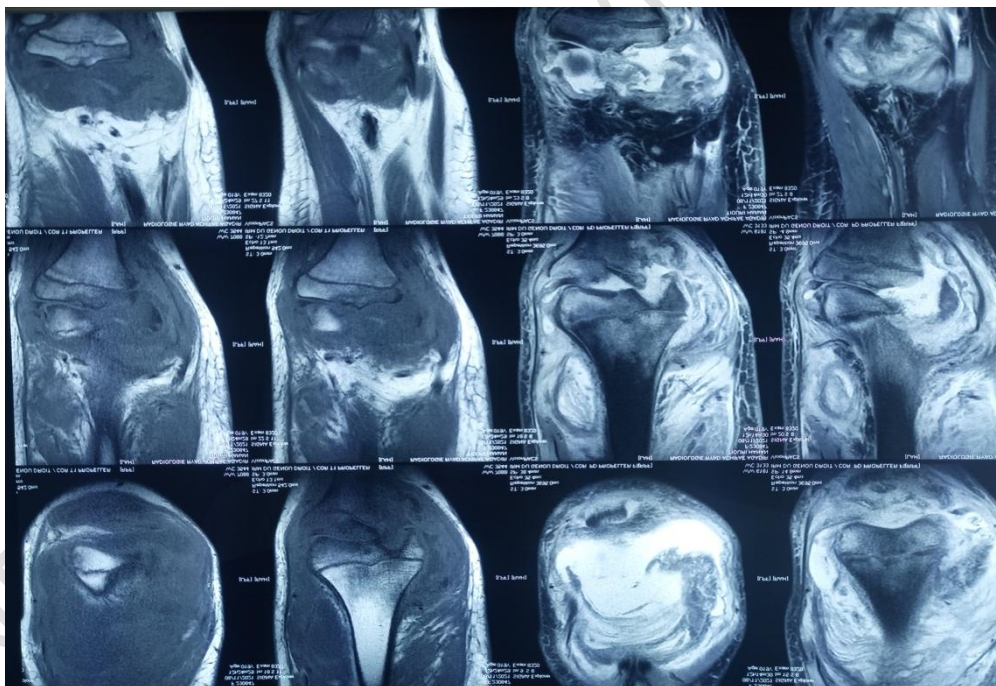
The MRI of the knee shows a large heterogeneous joint effusion with thickening of the synovium with dislocation of the knee and total rupture of the cruciate ligaments and detachment of a medial meniscus (in favor of a tabotic or microcrystalline arthritis).

Figure 5: MRI slices of the knee

The aspiration of the ascites fluid shows an exudative fluid, sterile culture, with negative adenosine desaminase dosage.

The joint aspiration shows a brownish serum fluid, negative direct examination and absent crystals.

A surgical biopsy was proposed and then conducted; several soft tissue and bone



fragment was collected and sent for anatomopathological analysis.

Anatomopathological analysis of the fragments found a a connective tissue devoid of its own epithelium and subject to inflammatory angiogenesis is associated with a polymorphic inflammatory infiltrate with numerous hemosiderophages and dystrophic calcification suggesting a pigmented villonodular synovitis.

Diagnostic reasoning

The first diagnosis to suggest was neuropathic arthropathy which can either be explained by a diabetic neuropathy or a congenital neuropathy, we also suspected a syphilitic arthropathy; Genetic accountability was not to be avoided due to multi-systemic nature of the syndrome, therefore, we a conducted genetic assessment; We also suspected a auto-immune accountability and we conducted an auto-immune assessment.

Management

Medical management

The patient when first admitted to our hospital was suffering from a septic shock secondary to an acute pyelonephritis; therefore the patient undergo a cytology-bacteriological examination of urine which concluded an infection by a sensible *Pseudomonas Aeruginosae* which was treated successfully with a Tazocillin and Amikacin association in addition to the correction of the hyperglycemia and the diabetic keto-acidosis regular insulin and hydration.

The glucose levels were highly unstable, we started we a premixed two injections insulin, we then switched to a two three injections basal-bolus lent-ultra rapid insulin, and then to a 4 injections injections basal-bolus lent-ultra rapid insulin.

Surgical management

A two times intervention as an open enlarged synovectomy with an external fixation; followed by a total knee replacement arthroscopy was proposed to the patient; After-more the patient refused the intervention and was discharged.

Discussion

PVNS of the knee associate with the syndrome described above is an entity that to our knowledge has not been described in the literature.

Patient family history of a mother with anemia of unknown cause with a sister with type 1 diabetes leads us to think of a genetic background or an autoimmune background; Auto-immune panels and karyotype were negative but that does not exclude an anomaly on the genes level rather than the chromosome level.

The syndrome described in this report does not exhibit facial dysmorphities, or lymphedema which are associated with Noonan syndrome [6], [7]; or mental retardation which is associated with Legius and Noonan syndromes [7], [12]; or heart anomalies which are associated with Costello syndrome [13].

Our patient exhibits a normal to slightly high white blood cells count, no fever (outside an infectious episode), no rashes unlike the Sweet's syndrome [9].

The short stature that the patient exhibits is related to a metabolic and an endocrine disorder (diabetes and under-nutrition) rather to genetic disorders like in Castello syndrome [12]; yet a genetic disorder with stature sequels cannot be excluded.

We hypothesize an abnormal activation of the immune system, particularly the monocyte-macrophage pathway including CSF-1 [4], TNF alpha for various reasons: hemosiderophages being the main marker of PVNS, in addition to synoviocyte A being of a macrophage lineage, and normocyte normochrome anemia with normal levels of ferritine often being associated with inflammation as a macrophage sideration response; and the incrimination of abnormal macrophage response in type 1 diabetes, pan gastritis, exudative ascites, and osteoporosis.

Oehler S et al,. suggested the implication of the chronic inflammation which increases the risk of articular bleeding and probably deranges the iron processing capacity of local synovial macrophages; This observation is in line with our report we also also incriminate the low prothrombin levels in the local bleeding phenomena [14].

Victoria L et al,. Reported a case of PVNS associated with Chediak–Higashi syndrome and also incriminated a dysregulated histiocyte function/control as replacement of recipient histiocytes; CHS is often high fever, anaemia of chronic disease, night sweats and highly elevated CRP levels and ESRs which are present in our patient. Yet many our patient exhibit a normal to high WBC, thrombocytosis instead of low platelet count nor any sensitivity to light which are key markers of CHS [10].

Conclusion

We reported a case of a 19-year-old female with knee PVNS and a novel multi-systemic syndrome involving endocrine, hematological, gastrointestinal, respiratory, urinary, and skeletal abnormalities. We suggested that an aberrant monocyte-macrophage pathway

might underlie this rare association, as evidenced by the presence of hemosiderophages in PVNS and other inflammatory markers in the patient. PVNS of the knee associate with the syndrome described above is an entity that to our knowledge has not been described in the literature. Findings describe in our syndrome does not exhibits features from the syndromes known to be associated with PVNS such as RASopathies (Noonan, Legius or Castello). We hypothesize an abnormal activation of the immune system, particularly the monocyte-macrophage pathway for various reasons: hemosiderophages being the main marker of PVNS, in addition to synoviocyte A being of a macrophage lineage, and normocyte normochrome anemia with normal levels of ferritine often being associated with inflammation as a macrophage sideration response; and the incrimination of abnormal macrophage response in type 1 diabetes, pangastritis, exudative ascites, and osteoporosis; in addition to macrophage incrimination in PVNS like Chediak–Higashi syndrome.

Citations

- [1] F. Flandry and J. C. Hughston, "Pigmented villonodular synovitis.," *JBJS*, vol. 69, no. 6, p. 942, Jul. 1987.
- [2] O. Ofluoglu, "Pigmented Villonodular Synovitis," *Orthop. Clin.*, vol. 37, no. 1, pp. 23–33, Jan. 2006, doi: 10.1016/j.ocl.2005.08.002.
- [3] W. K. Tyler, A. F. Vidal, R. J. Williams, and J. H. Healey, "Pigmented Villonodular Synovitis," *JAAOS - J. Am. Acad. Orthop. Surg.*, vol. 14, no. 6, p. 376, Jun. 2006.
- [4] J. S. Cupp *et al.*, "Translocation and Expression of CSF1 in Pigmented Villonodular Synovitis, Tenosynovial Giant Cell Tumor, Rheumatoid Arthritis and Other Reactive Synovitides," *Am. J. Surg. Pathol.*, vol. 31, no. 6, p. 970, Jun. 2007, doi: 10.1097/PAS.0b013e31802b86f8.
- [5] U. Fiocco *et al.*, "Molecular pathways involved in synovial cell inflammation and tumoral proliferation in diffuse pigmented villonodular synovitis," *Autoimmun. Rev.*, vol. 9, no. 11, pp. 780–784, Sep. 2010, doi: 10.1016/j.autrev.2010.07.001.
- [6] A. B. Meyers, A. O. Awomolo, and S. Szabo, "Multifocal tenosynovial giant cell tumors in a child with Noonan syndrome," *Pediatr. Radiol.*, vol. 47, no. 3, pp. 361–365, Mar. 2017, doi: 10.1007/s00247-016-3743-3.
- [7] O. Miri *et al.*, "Multifocal pigmented villonodular synovitis in the noonan syndrome," *Case Rep. Orthop.*, vol. 2018, 2018.
- [8] S. Mocellin, "Diffuse Tenosynovial Giant Cell Tumor," in *Soft Tissue Tumors : A Practical and Comprehensive Guide to Sarcomas and Benign Neoplasms*, S. Mocellin, Ed., Cham: Springer International Publishing, 2021, pp. 247–250. doi: 10.1007/978-3-030-58710-9_73.

- [9] G. Gosheger, A. Hillmann, T. Ozaki, H. Buerger, and W. Winkelmann, "Sweet's syndrome associated with pigmented villonodular synovitis," *Acta Orthop. Belg.*, vol. 68, no. 1, pp. 68–71, 2002.
- [10] V. L. True *et al.*, "A severe systemic presentation of pigmented villonodular synovitis in a child with underlying Chediak–Higashi syndrome," *J. Pediatr. Orthop. B*, vol. 24, no. 6, p. 526, Nov. 2015, doi: 10.1097/BPB.000000000000190.
- [11] R. A. Agha *et al.*, "The SCARE 2020 Guideline: Updating Consensus Surgical Case Report (SCARE) Guidelines," *Int. J. Surg.*, vol. 84, pp. 226–230, Dec. 2020, doi: 10.1016/j.ijsu.2020.10.034.
- [12] M. Zenker, "Clinical manifestations of mutations in RAS and related intracellular signal transduction factors," *Curr. Opin. Pediatr.*, vol. 23, no. 4, p. 443, Aug. 2011, doi: 10.1097/MOP.0b013e32834881dd.
- [13] S. Manoukian, F. Lalatta, A. Selicorni, G. Tadini, R. Cavalli, and G. Neri, "Cardio-facio-cutaneous (CFC) syndrome: Report of an adult without mental retardation," *Am. J. Med. Genet.*, vol. 63, no. 2, pp. 382–385, 1996, doi: 10.1002/(SICI)1096-8628(19960517)63:2<382::AID-AJMG11>3.0.CO;2-G.
- [14] S. Söder, S. Sesselmann, T. Aigner, S. Oehler, and A. Agaimy, "Tenosynovial giant cell tumour (pigmented villonodular synovitis-)-like changes in periprosthetic interface membranes," *Virchows Arch. Int. J. Pathol.*, vol. 468, no. 2, pp. 231–238, Feb. 2016, doi: 10.1007/s00428-015-1874-9.

Declaration of competing interest

The authors declare that there is no conflict of interest.

Statement of Ethics

The study was approved by the Scientific Committee and the Medical Council of our establishment. Written informed consent was obtained from the patient for publication of this report and any accompanying images in accordance with the principles of the Declaration of Helsinki.

Funding

No funding to declare.

Author's contribution

This article was written and drafted by El moula Abdelhamid . All the authors read and approved the final manuscript.

Data Availability Statement

All data generated or analyzed during this study are included in this published article.

Registration of research studies

Not applicable.

Guarantor

El moola Abdelhamid .

Provenance and peer review

Not commissioned.

UNDER PEER REVIEW IN IJAR