

MIESCHERS CHEILITIS: A CASE REPORT AND LITERATURE REVIEW

by Jana Publication & Research

Submission date: 21-May-2025 11:42AM (UTC+0700)

Submission ID: 2665079842

File name: IJAR-51726.docx (837.34K)

Word count: 1427

Character count: 9797

MIESCHER'S CHEILITIS: A CASE REPORT AND LITERATURE REVIEW

ABSTRACT

INTRODUCTION: Miescher's cheilitis is an unusual chronic inflammatory condition, which typically presents with episodic, painless swelling of the lips. It is group of orofacial granulomatosis and may appear as isolated or part of Melkersson-Rosenthal syndrome. The aetiology is unknown, but proposed theories include genetic predisposition, immune dysfunction, allergies and infections.

CASE PRESENTATION: Herein, we describe a 54-year-old female patient who developed slowly progressive non-tender upper lip swelling, without any evidence of fever or systemic features. McMeel's examination findings were consistent with idiopathic macrocheilitis. Inflammatory parameters in routine blood work were only mildly increased with normal results of immunologic assays and imaging. A lip biopsy revealed non-caseating granulomatous inflammation with epithelioid histiocytes and multinucleated giant cells, compatible with a diagnosis of Miescher's cheilitis. The patient had an excellent response to systemic corticosteroids and repeated attacks were managed by repeated short courses of oral corticosteroids and intralesional corticosteroid injections.

CONCLUSION: This case underscores the diagnosis and management of Miescher's cheilitis is difficult because of the lack of specific presentation and the chronic relapsing nature of the condition. Histologic evaluation continues to be the cornerstone tool for diagnosis and corticosteroids are considered as the standard of treatment. Continual clinic follow-up is needed to evaluate the activity of the disease, and assess control of any recurrences and modify therapeutic approach if necessary.

KEYWORDS: Miescher's Cheilitis, Orofacial Granulomatosis, Melkersson-Rosenthal Syndrome, lip biopsy, corticosteroids.

1 INTRODUCTION:

Granulomatous cheilitis is a rare clinical condition that presents most commonly as a painless, gradually enlarging swelling of the lip with a relapsing and remitting course (Plantier, 2016; Miest et al., 2016). Isolated, without facial paralysis or lingua plicata is called Miescher's cheilitis, a monosymptomatic form of the Melkersson–Rosenthal syndrome, (Greene & Rogers, 1989; Worsaae et al., 1982). The etiology is not clearly understood; it is supposed to be genetics, immune dysregulation and delayed hypersensitivity (Hornstein, 1973; Tilakaratne et al., 2008). Because of its vague clinical, and paraclinical, picture especially in our context, the diagnosis usually needs confirmation histopathologically and after exclusion of a systemic granulomatous disease as Crohn's disease or sarcoidosis (Jamil et al., 2023; Sciubba, 2005). We present a case with diagnostic difficulties and highlight the role of biopsy and individualized approach in the management of this uncommon disease.

6 CASE PRESENTATION:

A 54 year old married woman without any significant past medical history presented with a four month history of gradually increasing, painless swelling of the upper lip. There was no pruritus, facial asymmetry, ocular symptoms, fever, joint pain or systemic symptoms. Her general condition was uneventful.

Clinical examination showed a localized, painless swelling of the upper lip without any mucosal ulceration (figure 1). Central nervous system, cardiopulmonary, musculoskeletal, and ENT exams were noncontributory. Ophthalmologic evaluation ruled out uveitis and retinal vasculitis were excluded.

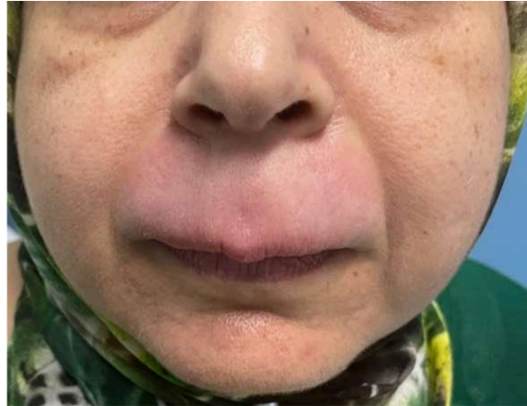

Figure 1: swollen upper lip

Among the inflammatory markers, the Erythrocyte Sedimentation Rate (ESR) (30 mm/hour) and C-Reactive Protein (CRP) (10 mg/L) were slightly elevated. Hematological and biochemical parameters including serum calcium, renal and liver function, and Angiotensin-Converting Enzyme (ACE) level, were found to be within normal limits. The Tuberculin Skin Test (TST), Quantiferon, Acid-Fast Bacilli (AFB), Venereal Disease Research Laboratory test -Treponema pallidum Hemagglutination Assay (VDRL-TPHA), hepatitis B/C, Toxoplasmosis infectious work-up was negative. Autoimmune and complement studies: Antinuclear Antibodies (ANA), Antineutrophil Cytoplasmic Antibodies (ANCA), anti-C1q, C3, C4, and CH50 were unremarkable.

Imaging studies: chest and sinus X-rays, cervico-thoraco-abdomino-pelvic Computed Tomography, brain Magnetic Resonance Imaging (MRI), and Fluorodeoxyglucose Positron Emission Tomography (FDG-PET) scan excluded intrinsic disease, systemic illness or malignancy.

Due to the presence of a chronic macrocheilitis, a lip biopsy was done. Biopsy revealed non-caseating granulomas with epithelioid and multinucleated giant cells in areas of

lymphoplasmacytic infiltrate (figure 2, 3, 4), establishing the diagnosis of granulomatous cheilitis. There was no granuloma in minor salivary gland. The absence of fissured tongue or facial palsy was suggestive of Miescher's cheilitis but an incomplete form of Melkersson-Rosenthal syndrome couldn't be entirely excluded.

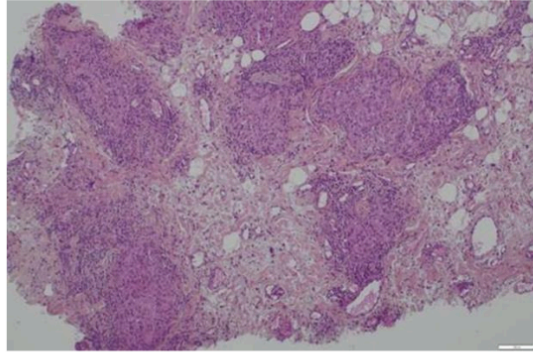


Figure 2: low power view (HE x 100) showing fibrotic connective tissue with multiple well-demarcated, non-caseating epithelioid granulomas embedded in a collagen-rich stroma, consistent with Miescher's cheilitis.

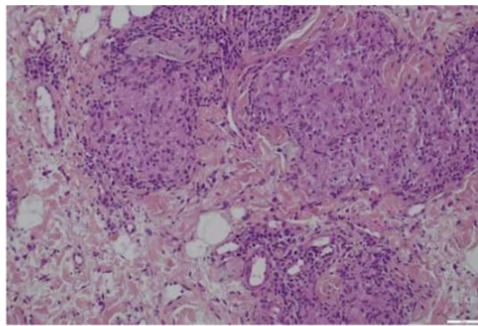


Figure 3: intermediate magnification (HE x 250) highlighting the structure of epithelioid granulomas composed of cohesive histiocytes with abundant eosinophilic cytoplasm and oval nuclei, without a fibrotic background

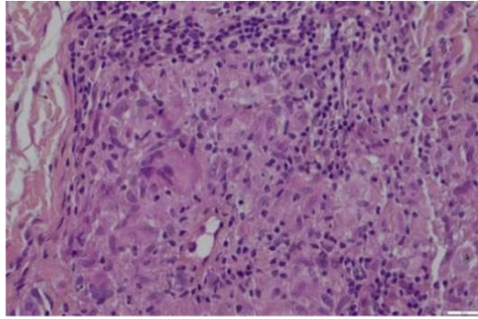


Figure 4: High power view (HE x 400) demonstrating the cytologic detail of epithelioid cells with finely dispersed chromatin and indistinct cell borders, arranged in compact granulomas.

Oral prednisone (60 mg per day) induced a prompt decrease in the swelling, followed by 3 weeks of tapering. Future recurrences were treated with short courses of steroids over the course of one year. Intralesional triamcinolone injections were initiated to minimize the systemic effects, and maintained long-term remission with no side effects.

DISCUSSION:

Miescher's Granulomatous Cheilitis (GC) or Miescher's cheilitis is a rare chronic inflammatory disease of unknown etiology, which presents clinically as recurrent or persistent asymptomatic swelling of the lips (Plantier, 2016). It is a monosymptomatic variant of the Melkersson-Rosenthal syndrome (MRS) which is characterized by a classic triad of recurrent orofacial edema, facial nerve palsy, and fissured tongue (Miest et al., 2016). In contrast with MRS, isolated CGM is not associated with neurological involvement and lingual enhancement, as seen in our patient.

The clinical features in our case which involved a 54-year-old woman with slowly progressive, painless, and non-febrile swelling of the upper lip are consistent with the classic demographic and symptomatology described in the reports. The majority of the presented

cases involve middle aged adults, with a slight female preponderance (Greene & Rogers, 1989; Worsaae et al., 1982). Our patient neither demonstrated systemic symptoms nor associated facial paralysis and lingua plicata, thus highlighting isolated CGM.

Histopathological analysis remains the cornerstone for diagnosis, typically revealing ² non-caseating granulomas composed of epithelioid histiocytes and multinucleated giant cells within the lamina propria, often associated with perivascular lymphocytic infiltration and edema (Jamil et al., 2023). The biopsy findings in our patient corroborated these classical features, thus excluding other granulomatous diseases ⁹ such as Crohn's disease, sarcoidosis, and infectious etiologies.

The etio-pathogenesis of CGM is still obscure. Hypothesis is anergy, delayed type sensitivity, chronic infection, especially of odontogenic or gastrointestinal origin and genetic predispositions (Hornstein, 1973). Nevertheless, our patient had no underlying systemic disease or focus of infection, and immunological work-up was found to be negative, which favored the diagnosis of idiopathic CGM.

Therapeutically, corticosteroids remain the mainstay of treatment, both topical and systemic, though their effects may be temporary with frequent relapses (Sciubba, 2005). In our case systemic corticosteroid treatment produced only a partial but a distinct effect, similar to what has been reported. Other adjunctive therapies described in literature is intralesional corticosteroids, clofazimine, dapsone, hydroxychloroquine, and surgical excision in resistant cases (Campbell et al., 2011; Neville et al., 2016). Given the chronic-relapsing nature of CGM, long-term follow-up is essential to monitor therapeutic response and detect recurrences early.

A differential diagnosis in these cases is orofacial granulomatosis (OFG), Melkersson-Rosenthal syndrome (MRS), Crohn's disease (oral involvement), sarcoidosis and specific

granulomatous diseases such as tuberculosis or deep mycotic infections (Tilakaratne et al., 2008). Our exhaustive clinical and paraclinical evaluation ruled out these conditions.


CONCLUSION:

Our case adds to the literature on CGM with a classical presentation, on histological confirmation and good therapeutic response. It highlights the necessity to consider CGM in patients of isolated macrocheilitis and emphasis on the importance of multi-disciplinary approach to exclude the systemic diseases.

REFERENCES:

- Campbell, H. E., Escudier, M. P., Patel, P., Challacombe, S. J., & Sanderson, J. D. (2011). Review article: Orofacial granulomatosis—a challenge for the gastroenterologist? *Alimentary Pharmacology & Therapeutics*, 34(6), 654–667. <https://doi.org/10.1111/j.1365-2036.2011.04784.x>
- Greene, R. M., & Rogers, R. S. (1989). Melkersson-Rosenthal syndrome: A review of 36 patients. *Journal of the American Academy of Dermatology*, 21(6), 1263–1270. [https://doi.org/10.1016/S0190-9622\(89\)70277-1](https://doi.org/10.1016/S0190-9622(89)70277-1)
- Hornstein, O. P. (1973). Melkersson–Rosenthal syndrome: A neuromuco-cutaneous disease of complex origin. *Current Problems in Dermatology*, 5, 117–156.
- Jamil, R. T., Agrawal, M., Gharbi, A., et al. (2023). Cheilitis granulomatosa. In StatPearls [Internet]. StatPearls Publishing.
- Miest, R., Bruce, A. J., & Rogers, R. S. (2016). Orofacial granulomatosis. *Clinics in Dermatology*, 34(4), 505–513. <https://doi.org/10.1016/j.clindermatol.2016.02.017>

- Neville, B. W., Damm, D. D., Allen, C. M., & Chi, A. C. (2016). Granulomatous diseases. In *Oral and Maxillofacial Pathology* (4th ed., pp. 177–191). Elsevier.
- Plantier, F. (2016). Chéilite de Miescher. *Annales de Dermatologie et de Vénéréologie*, 143(6–7), 486–489. <https://doi.org/10.1016/j.annder.2016.03.005>
- Sciubba, J. J. (2005). Oral granulomatous diseases: Differential diagnosis and update. *Dental Clinics of North America*, 49(1), 203–221. <https://doi.org/10.1016/j.cden.2004.07.004>
- Tilakaratne, W. M., Freysdottir, J., & Fortune, F. (2008). Orofacial granulomatosis: Review on aetiology and pathogenesis. *Journal of Oral Pathology & Medicine*, 37(4), 191–195. <https://doi.org/10.1111/j.1600-0714.2007.00590.x>
- Worsaae, N., Christensen, K. C., Schiodt, M., & Reibel, J. (1982). Melkersson–Rosenthal syndrome and cheilitis granulomatosa: A clinicopathological study of thirty-three patients with special reference to their oral lesions. *Oral Surgery, Oral Medicine, Oral Pathology*, 54(4), 404–413. [https://doi.org/10.1016/0030-4220\(82\)90322-5](https://doi.org/10.1016/0030-4220(82)90322-5)



MIESCHERS CHEILITIS: A CASE REPORT AND LITERATURE REVIEW

ORIGINALITY REPORT

17%	12%	15%	0%
SIMILARITY INDEX	INTERNET SOURCES	PUBLICATIONS	STUDENT PAPERS

PRIMARY SOURCES

1	actasdermo.org Internet Source	2%
2	www.jle.com Internet Source	1%
3	rmdopen.bmj.com Internet Source	1%
4	"Posters", Journal of the European Academy of Dermatology and Venereology, 11/2003 Publication	1%
5	core-docs.s3.amazonaws.com Internet Source	1%
6	"Society of general internal medicine 23rd annual meeting Boston, Massachusetts May 4-6, 2000 abstracts", Journal of General Internal Medicine, 2000 Publication	1%
7	C Scully. "Marathon of eponyms: 13 Melkersson-Rosenthal syndrome : Marathon of eponyms", Oral Diseases, 10/2010 Publication	1%
8	pmc.ncbi.nlm.nih.gov Internet Source	1%
9	www.fou.nu Internet Source	1%

10	Lindsay Montague, Ashley Clark, Jerry Elmer Bouquot. "Lesions of the Oral Cavity", Elsevier BV, 2021 Publication	1 %
11	Mukaddes Kavala. "Granulomatous cheilitis resulting from a tuberculide", International Journal of Dermatology, 7/2004 Publication	1 %
12	RIF van der Waal. "Cheilitis granulomatosa", Journal of the European Academy of Dermatology and Venereology, 11/2001 Publication	1 %
13	scindeks.ceon.rs Internet Source	1 %
14	www.mdpi.com Internet Source	1 %
15	E Guttman-Yassky. "Resolution of orofacial granulomatosis with amalgam removal", Journal of the European Academy of Dermatology and Venereology, 5/2003 Publication	1 %
16	iris.unibs.it Internet Source	1 %
17	Alessandro Innocenti, Marco Innocenti, Cecilia Taverna, Dario Melita et al. "Miescher's cheilitis: Surgical management and long term outcome of an extremely severe case", International Journal of Surgery Case Reports, 2017 Publication	1 %
18	Richard M. Greene, Roy S. Rogers. "Melkersson-Rosenthal syndrome: A review of	1 %

36 patients", Journal of the American
Academy of Dermatology, 1989

Publication

- 19
- Katarzyna Błochowiak, Aya Kraiz, Monika Bowszyc-Dmochowska, Elżbieta Paszyńska, Dorota Jenerowicz. "Miescher's Cheilitis as a Diagnostic and Therapeutic Challenge—A Case Report", Medicina, 2025
- <1 %

Publication

- 20
- Ram Chandra Adhikari, Mahesh Shah. "Miescher's cheilitis: A case report with literature review", Journal of Pathology of Nepal, 2018
- <1 %

Publication

Exclude quotesOn

Exclude matchesOff

Exclude bibliographyOn