

# Mucocele with Allergic Fungal Rhinosinusitis – A Rare Presentation

*by* Jana Publication & Research

---

**Submission date:** 21-May-2025 11:47AM (UTC+0700)

**Submission ID:** 2664988079

**File name:** IJAR-51732.docx (3.35M)

**Word count:** 1128

**Character count:** 6381

## Mucocele with Allergic Fungal Rhinosinusitis – A Rare Presentation

### Abstract:

Allergic fungal rhinosinusitis (AFRS) is one of the most common clinical entities that we come across in routine otorhinolaryngology practice, yet, it surprises us with diverse clinical presentations. The occurrence of mucocele co-existing with AFRS is a rarely documented presentation. Here we are reporting a rare case of a 35-year-old female who presented with chronic rhinosinusitis with nasal polyps (CRSwNP). On further radiological evaluation, coexistence of mucocele with AFRS was noted. We also want to share our experience in managing the case.

**Keywords:** Allergic fungal rhinosinusitis, Mucocele

6

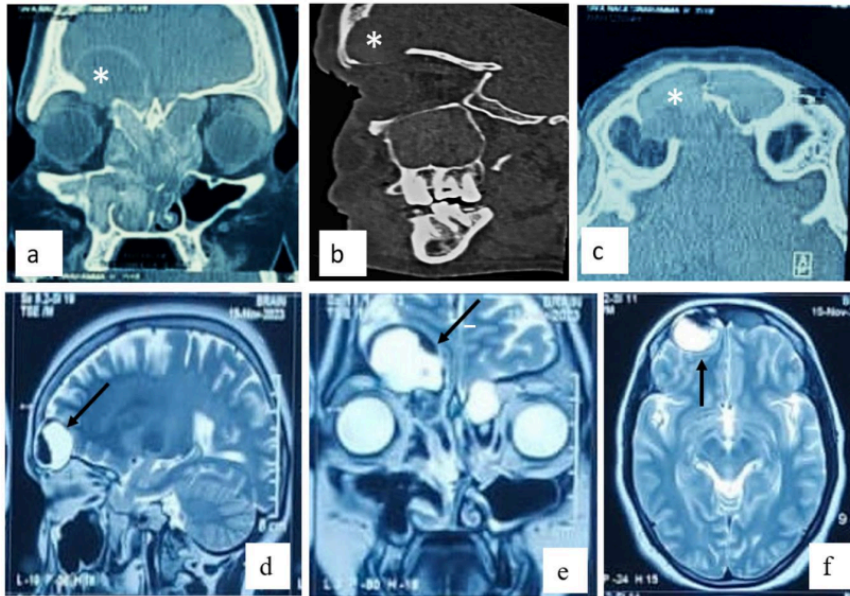
### Introduction:

Allergic fungal rhinosinusitis (AFRS) is a noninvasive fungal rhinosinusitis seen in immunocompetent atopic individuals<sup>[1]</sup>. It is characterized by nasal polyps, accumulating allergic mucin, proliferating fungal hyphae, and depositing metallic elements like manganese, iron, and magnesium, which with lead to an expanding mass in paranasal sinuses, causing remodeling of the bony walls<sup>[2]</sup>. In 6 - 56% of patients with AFRS, this expanding mass leads to disease extension into orbit and intracranium<sup>[3]</sup>. However, the accumulation of fungal debris blocking the sinus ostia, rather than causing expansion and remodelling, resulting in the formation of a mucocele is a rare occurrence. CT Paranasal sinuses typically suffice in diagnosing AFRS. MRI with contrast is required in cases where there is intracranial or orbital regions involvement.

1

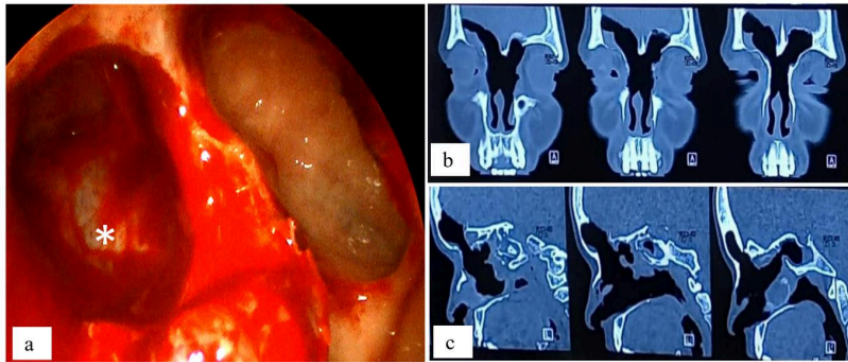
### Case Report:

A 35-year-old female presented to Dept of otorhinolaryngology with complaints nasal obstruction since 1 year and later she developed epiphora and mild proptosis of right eye since 3 months. After thorough clinical examination and diagnostic nasal endoscopy, she was diagnosed with chronic rhinosinusitis with nasal polyps. CT PNS (Fig 1 a,b,c) and MRI (Fig 1 d,e,f).



**Fig 1[a,b,c,d,e,f]** - CT PNS – coronal section showing double densities in sinuses classic sign of AFRS and an intracranial space occupying lesion (\*) in right frontal region (a), Sagittal section (b) and axial section (c) showing the same lesion along with eroded posterior table of right frontal sinus (\*). MRI PNS – Sagittal section showing fungal debris in anterior part of right frontal sinus and fluid collection in posterior part extending into anterior cranial fossa (black arrow) which was made out to be a mucocoele (a), coronal section (b) and axial section (c) showing presence of same lesion extradurally (black arrow).

**8**  
A final diagnosis of Allergic fungal rhinosinusitis with mucocoele in right anterior cranial fossa was made. The patient underwent endoscopic sinus surgery with Draf III procedure. Debrider-assisted polypectomy was performed, and all sinuses were cleared of fungal debris. Draf III procedure was carried out to access disease in the frontal sinuses. After the removal of the fungal debris in the right frontal sinus, drainage of a mucocoele was performed. A posterior table defect was observed, exposing the pulsating dura mater (Fig 2a). A postoperative check CT scan was performed (Fig 2b,2c). The patient is on regular follow-up.



**Fig 2 [a,b,c]** - Intra op pic of completed Draf III showing eroded posterior table of right frontal sinus exposing the dura mater (\*) as visualized with 30° endoscope (a). Post op CT coronal (b) and sagittal (c) cuts showing complete removal of disease from the frontal sinuses

### Discussion:

AFRS is a chronic inflammatory condition of paranasal sinuses occurring in immunocompetent atopic individuals <sup>[4]</sup>. It is characterized by host tissue reaction to extramucosal fungi in the sinuses causing gradual accumulation of allergic fungal mucin and proliferating fungal hyphae giving rise to fungal debris which has distinct clinical, endoscopic, and radiological features <sup>[5]</sup>. Over time the accumulating fungal debris leads to expansion and remodeling of bone to an extent causing pressure symptoms such as proptosis, visual disturbances, facial dysmorphism, and chronic headaches <sup>[6]</sup>.

Our patient was initially diagnosed with CRSwNP. CT scan showed signs of AFRS along with distinct enhancing lesion in the right frontal lobe (fig 1a) and it raised concerns about a possible frontal abscess secondary to AFRS converting into an invasive fungal infection. However, the patient did not have symptoms associated with abscess formations. MRI scan confirmed that to be a distinct locule of mucoid fluid adjacent to the dura mater (fig 1d). This finding effectively ruled out the presence of an abscess, leading to a diagnosis of a mucocele. The differentiation between a mucocele and an abscess is made out by lack of surrounding inflammation (fig 1e, f).

In AFRS cases, extensive fungal debris leads to significant expansion of the sinus walls and ostia. However, it is rare for this debris to obstruct an already widened frontal recess, subsequently causing the formation of a mucocele, as observed in this patient. The simultaneous occurrence of AFRS and a mucocele within the same sinus is an uncommon clinical phenomenon. In this case, the mucocele eroded the posterior table of the frontal sinus, with extension into the anterior cranial fossa.

Considering the complexity of the disease, we opted for a more comprehensive surgical approach. We performed an Endoscopic sinus surgery with a Draf III procedure which allowed for the complete removal of the fungal debris, effective drainage of the mucocele and mitigating the risk of recurrence. The patient currently under regular follow up and doing well.

**Conclusion:**

We are reporting this case due to the rare presentation of AFRS in coexistence with mucocoele which has seldom been documented in the existing literature. Surgeon should keep in mind the possibility of coexistent pathology like mucocoele in case of any intracranial space occupying lesions noted in association with AFRS.

**1****Funding:**

There was no source of funding for the study. Authors certify that they have no affiliations with or involvement in any organization or entity with any financial interest or non-financial interest in the subject matter or materials discussed in this manuscript.

**Declarations:**

**Ethical Approval:** The Ethics committee at PSIMS and RF has confirmed that no ethical approval is required.

**conflict of Interest:** The authors declare no conflict of interest.

**References:**

- 1.Luong AU, Chua A, Alim BM, Olsson P, Javier A. Allergic Fungal Rhinosinusitis: The Role and Expectations of Biologics. The Journal of Allergy and Clinical Immunology: In Practice. 2022 Dec;10(12):3156–62.
- 2.Handley GH, Visscher DW, Katzenstein ALA, Peters GE. Bone erosion in allergic fungal sinusitis. American Journal of Rhinology. 1990 Jul 1;4(4):149–53.
- 3.Meccariello G, Deganello A, Mannelli G, Bianco G, Ammannati F, Georgalas C, et al. Allergic fungal rhinosinusitis infiltrating anterior skull base and clivus. Auris Nasus Larynx. 2013 Aug;40(4):405–8.
- 4.Chua AJ, Jafar A, Luong AU. Update on allergic fungal rhinosinusitis. Annals of Allergy Asthma & Immunology. 2023 Feb 26;131(3):300–6.
- 5.Kameswaran M, Chopra H, Kanojia S, Janakiram T, Vaid N, Soni A, et al. Allergic Fungal Rhinosinusitis. An International Journal Clinical Rhinology. 2012 Aug 1;5(2):72–86.
- 6.Vashishth A. Extensive allergic fungal rhinosinusitis: ophthalmic and skull base complications. Indian Journal of Otolaryngology and Head & Neck Surgery [Internet]. 2014 Aug 25;67(3):227–33. Available from: <https://doi.org/10.1007/s12070-014-0771-x>

# Mucocele with Allergic Fungal Rhinosinusitis – A Rare Presentation

## ORIGINALITY REPORT

15%

SIMILARITY INDEX

9%

INTERNET SOURCES

14%

PUBLICATIONS

4%

STUDENT PAPERS

## PRIMARY SOURCES

- 1

Satish Chandra Tripuraneni, Sameera Gera, Nagu Akhileswar Reddy. "A Giant Encephalocele Mimicking Nasal Polyp – A Case Report", Indian Journal of Otolaryngology and Head & Neck Surgery, 2024  
Publication

8%
- 2

Meccariello, Giuseppe, Alberto Deganello, Giuditta Mannelli, Giacomo Bianco, Franco Ammannati, Christos Georgalas, and Oreste Gallo. "Allergic fungal rhinosinusitis infiltrating anterior skull base and clivus", Auris Nasus Larynx, 2012.  
Publication

1%
- 3

[repository.up.ac.za](https://repository.up.ac.za)  
Internet Source

1%
- 4

Sima Vazquez, John K. Houten, Zehavya T. Stadlan, Jacob D. Greisman et al. "Thecal sac ligation in the setting of thoracic spondyloptosis with complete cord transection", Surgical Neurology International, 2023  
Publication

1%

5 Stephen G. Harner, Jacquelynne P. Corey, Kathelyne G. Delsupehe, Berrylin J. Ferguson. "Allergic fungal sinusitis: Allergic, infectious, or both?", Otolaryngology-Head and Neck Surgery, 2016

Publication

1 %

6 [www.researchsquare.com](http://www.researchsquare.com)

Internet Source

1 %

7 [digital.library.adelaide.edu.au](http://digital.library.adelaide.edu.au)

Internet Source

1 %

8 Matthew W Ryan. "Allergic fungal rhinosinusitis: diagnosis and management", Current Opinion in Otolaryngology & Head and Neck Surgery, 02/2007

Publication

1 %

Exclude quotes On

Exclude matches Off

Exclude bibliography On