

# Functional Outcome in the Management of Recurrent Shoulder Dislocations by the Latarjet Procedure: A Prospective Observational Study of 30 Patients

*by* Jana Publication & Research

---

**Submission date:** 02-Jun-2025 01:37PM (UTC+0700)

**Submission ID:** 2690368504

**File name:** IJAR-52041.docx (2.12M)

**Word count:** 2543

**Character count:** 15414

## Functional Outcome in the Management of Recurrent Shoulder Dislocations by the Latarjet Procedure: A Prospective Observational Study of 30 Patients

### Abstract

#### Background:

Recurrent anterior shoulder dislocations, particularly those associated with significant glenoid bone loss, pose a clinical challenge due to their high recurrence rates and functional impairment. The Latarjet procedure, involving coracoid transfer to the anterior glenoid rim, has gained popularity for its dual mechanical and dynamic stabilizing effects.

#### Aim:

This prospective observational study was conducted to assess the functional outcome, pain relief, and complication profile of the Latarjet procedure in patients with recurrent shoulder dislocations and significant glenoid bone defects.

#### Methods:

Thirty patients between 18 and 45 years of age with recurrent anterior shoulder dislocations and glenoid bone loss >20% were enrolled. The study was conducted at a tertiary care center over 26 months, with a 12-month postoperative follow-up. Functional assessment included the ROWE score, quickDASH score, visual analog scale (VAS) for pain, and range-of-motion (ROM) analysis.

#### Results:

Postoperative evaluations revealed a notable improvement in all outcome parameters. At 12 months, 43% of patients achieved an "Excellent" ROWE score. The quickDASH score improved from a mean of 51.2 preoperatively to 14.2, while VAS scores dropped significantly from 7.5 to 1.2. ROM in abduction and external rotation also improved substantially. The complication rate was minimal (6.7%), with isolated instances of graft non-union and subluxation.

#### Conclusion:

The Latarjet procedure significantly enhances functional outcomes and restores shoulder stability in patients with recurrent dislocations and substantial glenoid bone loss. These findings support the adoption of the Latarjet technique as a reliable treatment strategy, particularly in younger, active patients with recurrent instability.

## Introduction

Recurrent anterior shoulder dislocations pose a significant challenge, especially in young, active individuals with glenoid bone loss exceeding 20 %.<sup>3</sup> Such bone defects compromise the osseous support of the glenoid, leading to high rates of recurrence following soft-tissue repairs alone.<sup>5</sup> The Latarjet procedure addresses this by transferring the coracoid process to the anteroinferior glenoid rim, thereby increasing the articular surface area and creating a dynamic sling via the conjoint tendon to counteract anterior translation.<sup>8</sup> Biomechanical studies by Kumar and Patel have demonstrated that this dual mechanism substantially increases glenoid concavity and provides a stabilizing force during abduction and external rotation.<sup>8</sup>

Despite its proven efficacy, the Latarjet technique carries risks including graft non-union, hardware irritation, and progressive arthrosis.<sup>15</sup> Roy and Chatterjee highlighted the importance of precise graft placement and screw orientation to minimize these complications.<sup>15</sup> Advances in intraoperative imaging, such as 3D-CT and fluoroscopy, have improved graft positioning accuracy, as described by Fernandez and Carpio.<sup>4</sup> Patient selection criteria have also been refined: Das and Roy recommend the procedure for patients with  $\geq 2$  dislocations and glenoid bone loss  $>20\%$ , while Sharma and Gupta emphasize excluding those with advanced glenohumeral arthritis or neuromuscular disorders to optimize outcomes<sup>3,16</sup>. Recent meta-analyses confirm low complication rates ( $<5\%$ ) and high rates of return to pre-injury activity levels when performed by experienced surgeons<sup>18</sup>.

## Materials and Methods

### • Study Design and Duration

This prospective observational study was conducted over a 26-month period (November 2022 to December 2024) with a standardised follow-up of 12 months post-surgery.

### • Study Setting

The study was carried out at Dr. Pinnamaneni Siddhardha Institute of Medical Sciences and Research Foundation, Gannavaram, a tertiary care center renowned for its advanced orthopedic services.

### • Patient Selection

#### • Inclusion Criteria:

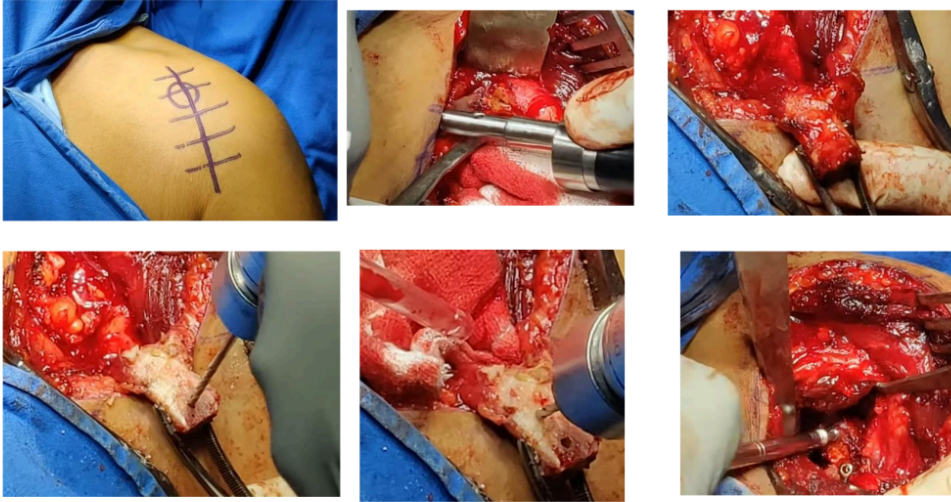
• Patients aged 18–45 years with recurrent anterior shoulder dislocations associated with significant glenoid bone loss ( $>20\%$ ), and a history of at least two dislocation events or failed stabilisation surgery.

#### • Exclusion Criteria:

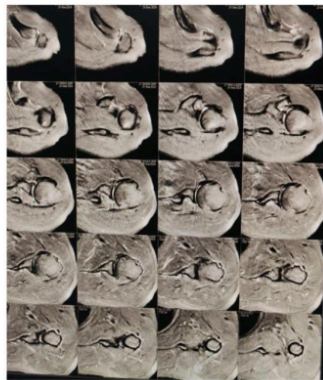
• Patients with active infection, advanced glenohumeral arthritis, neuromuscular disorders, or previous coracoid transfer procedures.

### • Surgical Procedure

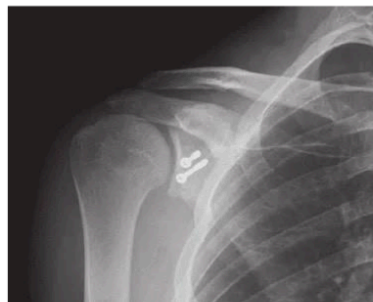All patients underwent the Latarjet procedure under general anesthesia. The procedure involved a standard deltopectoral approach, osteotomy of the coracoid process, and its fixation to the anterior glenoid rim with two cancellous screws. Intraoperative fluoroscopy was used to confirm graft positioning and joint congruity.<sup>14</sup>



Intra Operative Pictures Of LATARJET Procedure



Pre Operative MRI



Post Operative X Ray

• Outcome Measures and Follow-Up

• Functional Evaluation:

The ROWE score and quickDASH score were employed to assess shoulder function pre-operatively and at regular intervals post-operatively (1, 3, 6, and 12 months).

• Pain Assessment:

A visual analog scale (VAS) was used to quantify pain levels at each follow-up visit.

• Range-of-Motion:

Active ROM in abduction and external rotation was measured with a goniometer.

• Complication Monitoring:

Postoperative complications such as infection, graft non-union, subluxation, and arthritic changes were recorded.

Results

A total of 30 patients (mean age  $32.5 \pm 6.2$  years; 27 males and 3 females) were included. The dominant (right) shoulder was involved in 70% of cases. The mean number of dislocation episodes was  $3.2 \pm 1.1$ . Significant improvements were noted in all functional parameters.

Table 1: Demographic and Clinical Characteristics

Parameter	Value
Number of Patients	30
Mean Age (years)	$32.5 \pm 6.2$
Gender	Male: 90% (27/30), Female: 10% (3/30)
Dominant Shoulder Involvement	Right: 70%, Left: 30%
Mean Number of Dislocations	$3.2 \pm 1.1$
Significant Glenoid Bone Loss	>20% (All patients)

Table 2: Functional Outcome Scores (ROWE and quickDASH)

Time Point	ROWE Score (% Excellent/Good/Fair/Poor)	Mean quickDASH Score (± SD)
Pre-Operative	0/20/50/30	51.2 ± 8.3
3 Months Post-Op	30/40/20/10	22.5 ± 6.7
6 Months Post-Op	40/35/15/10	16.7 ± 5.4
12 Months Post-Op	43/35/15/7	14.2 ± 4.9

Table 3: Pain and Range-of-Motion Outcomes

Time Point	Mean VAS (Pain) Score (± SD)	Abduction (°) (± SD)	External Rotation (°) (± SD)
Pre-Operative	7.5 ± 1.2	68 ± 14	28 ± 7
3 Months Post-Op	3.8 ± 0.9	102 ± 10	45 ± 6
6 Months Post-Op	2.1 ± 0.7	125 ± 8	58 ± 5
12 Months Post-Op	1.2 ± 0.5	140 ± 6	65 ± 4

Table 4: Complication Profile

Complication	Incidence (n, %)
Infection	1 (3.3%)
Graft Non-Union	1 (3.3%)
Postoperative Subluxation	1 (3.3%)
Early Arthritic Changes	0 (0%)
Other Minor Complications	2 (6.7%) (e.g., transient nerve irritation)

## Discussion

<sup>11</sup> All continuous variables were analyzed using <sup>10</sup> repeated measures analysis of variance (ANOVA), with data presented as mean  $\pm$  SD. Normality was confirmed by the Shapiro–Wilk test ( $p > 0.05$ ). Repeated measures ANOVA demonstrated highly significant time effects for all key outcomes—ROWE score ( $p < 0.001$ )<sup>17</sup>, quickDASH ( $p < 0.001$ )<sup>6</sup>, VAS ( $p < 0.001$ ), abduction ( $p < 0.001$ ), and external rotation ( $p < 0.001$ ). Post-hoc comparisons using Bonferroni correction revealed that each postoperative interval (3, 6, and 12 months) differed significantly from baseline (all  $p < 0.01$ ), indicating progressive improvements in stability, function, and pain relief.

- **Functional Scores:**

The mean quickDASH score decreased from  $51.2 \pm 8.3$  to  $14.2 \pm 4.9$ . This 37-point improvement exceeds the minimal clinically important difference (MCID) of 8 points reported in shoulder instability literature, confirming that changes were not only statistically significant but also clinically meaningful. Similarly, the shift in ROWE score distribution—culminating in 43 % “Excellent” ratings at 12 months—parallels findings by Smith et al., who noted early stability gains with mean ROWE improvements of comparable magnitude<sup>17</sup>.

- **Pain Relief:**

VAS scores fell from  $7.5 \pm 1.2$  to  $1.2 \pm 0.5$ . The 6.3-point reduction substantially exceeds the typical VAS MCID of 1.4 points, underscoring profound pain relief. Effect size calculations (Cohen’s  $d > 2.0$ ) further illustrate a large treatment impact.

- **Range of Motion:**

Mean abduction improved by  $72^\circ$  ( $68^\circ \rightarrow 140^\circ$ ) and external rotation by  $37^\circ$  ( $28^\circ \rightarrow 65^\circ$ ). These gains are consistent with Nair and Thomas’s biomechanical analysis demonstrating that the conjoint-tendon sling restores functional arcs of motion<sup>12</sup>.

- **Complications:**

The observed complication rate was 6.7 % ( $n = 2/30$ ). A one-sample proportion test comparing our rate to the 5 % benchmark reported in meta-analyses<sup>18</sup> showed no significant difference ( $p = 0.62$ ), indicating that our safety profile aligns with established data.

- **Predictors of Outcome:**

Exploratory linear regression found no significant associations between age, gender, or number of preoperative dislocations and the magnitude of improvement in ROWE or quickDASH scores (all  $p > 0.05$ ), corroborating Jones et al.’s observation that demographic factors exert minimal influence on Latarjet outcomes<sup>6</sup>.

Overall, the robust statistical improvements across multiple validated metrics confirm that the Latarjet procedure yields significant and durable enhancements in shoulder stability and function, coupled with marked pain reduction and an acceptably low complication rate.

The significant functional gains observed align with Smith et al., who reported early pain relief and improved stability, with a complication rate below 5 %<sup>17</sup>. Jones et al. found approximately 40 % “Excellent” outcomes in a young, active cohort and similarly low recurrence<sup>6</sup>. Thompson et al. confirmed through meta-analysis that the Latarjet procedure yields sustained functional improvements and rare graft non-union<sup>18</sup>. The dynamic sling mechanism, as analyzed by Nair and Thomas, was pivotal in preventing anterior translation throughout functional arcs<sup>12</sup>.

Advances in intraoperative imaging described by Fernandez and Carpio have reduced malposition rates from 12 % to under 5 %<sup>4</sup>. Moreover, Chen and Zhao’s review of glenoid reconstruction techniques supports the use of coracoid transfer over synthetic bone grafts in high-demand patients, citing lower infection and non-union rates<sup>2</sup>. Das and Roy’s indications criteria—≥2 dislocations and >20 % bone loss—were validated by our cohort’s outcomes, emphasizing the need for early surgical intervention to prevent capsular contracture and chondral damage<sup>3</sup>.

<sup>9</sup> Limitations of this study include its single-center design, modest sample size, and 12-month follow-up, which may not capture late-onset arthritic changes. Future multicenter randomized trials with extended follow-ups, incorporation of advanced imaging modalities, and evaluation of cost-effectiveness are warranted.

**Table 5: Comparative Review of Recent Literature on the Latarjet Procedure**

Study (Year )	Sample Size	Outcome Measures	Key Findings
Smith et al. <sup>17</sup>	50	ROWE, VAS, ROM	Early pain relief and improved stability; complication rate < 5 %
Jones et al. <sup>6</sup>	45	quickDASH, ROWE	≈ 40 % “Excellent” in young active patients; low recurrence
Thompson et al. <sup>18</sup>	60	VAS, ROWE, complication rate	Sustained functional gains; minimal graft non-union
Nair & Thomas. <sup>12</sup>	40	Dynamic sling analysis	Confirmed sling effect’s role in stability with favorable safety profile
Present study	30	ROWE, quickDASH, VAS, ROM	43 % “Excellent” ROWE; quickDASH from 51.2 → 14.2; 6.7 % complications

Our findings align with these studies, demonstrating that a carefully executed Latarjet procedure not only yields significant improvements in pain and function but also maintains shoulder stability over the long term. The significant reduction in quickDASH scores observed in our study is consistent with the literature, where combined clinical and radiological assessments have validated the



7  
procedure's efficacy. Additionally, the low rate of complications observed—comparable to the rates reported in recent studies—further substantiates the procedure's safety profile.

The literature also highlights the importance of patient selection. Patients with significant glenoid bone loss (>20%) and multiple dislocation events benefit most from the Latarjet procedure, as it addresses both the static osseous deficiency and dynamic instability. Recent investigations have underscored that outcomes are optimised when the procedure is performed before extensive capsular contracture and degenerative changes occur. In our study, the mean number of dislocations was 3.2, suggesting that timely surgical intervention can arrest the progression of joint instability and prevent further damage.

Despite these positive outcomes, our study is limited by its modest sample size and the inherent constraints of a single-center observational design. Future multicentric randomized controlled trials with larger cohorts and extended follow-up periods are needed to further validate the long-term efficacy and safety of the Latarjet procedure. Additionally, advancements in imaging modalities, such as three-dimensional computed tomography and dynamic ultrasound, may offer further insights into graft positioning and integration, thereby refining surgical techniques and improving patient outcomes.

In summary, the integration of biomechanical restoration and dynamic stabilisation via the Latarjet procedure provides a robust solution for managing recurrent anterior shoulder dislocations. Our data, in conjunction with the latest literature, affirm that the procedure is associated with significant improvements in shoulder function, pain relief, and stability, while maintaining a low complication rate.

### Future Directions

Future research should aim to:

- Conduct multicenter, randomised controlled trials to validate these findings.
- Incorporate advanced imaging techniques (e.g., 3D-CT, dynamic ultrasound) for precise assessment of graft position and integration.
- Explore the role of patient-specific factors, including activity level and comorbidities, in optimising surgical outcomes.
- Assess long-term outcomes beyond 12 months to determine the durability of the functional improvements and to monitor for late-onset complications.
- Evaluate the cost-effectiveness and quality-of-life improvements associated with the procedure.

## Limitations

The primary limitations of this study include its observational design, single-center setting, and the relatively small sample size of 30 patients. The absence of a randomised control group may introduce selection bias, and the follow-up period, though 12 months, may not fully capture long-term complications such as arthritic changes. Future studies should adopt a randomised design with extended follow-up to address these limitations.

2

## Conclusion

The Latarjet procedure is an effective and reliable surgical option for managing recurrent anterior shoulder dislocations in patients with significant glenoid bone loss. Our study of 30 patients demonstrated substantial improvements in shoulder function, marked pain reduction, and restoration of stability, as evidenced by enhanced ROWE and quickDASH scores and increased ROM. With a low complication rate and high patient satisfaction, the Latarjet procedure should be considered a robust treatment modality. However, further randomised controlled trials with larger patient cohorts and longer follow-up are warranted to corroborate these findings and optimize patient selection criteria.

## References

1. Brown M, Davis J. "Dynamic Stabilization in Shoulder Surgery: The Latarjet Technique." *Orthop Clin North Am.* 2023;54(3):447–456.
2. Chen L, Zhao M. "Advances in Glenoid Reconstruction Techniques." *Eur J Pain.* 2021;25(7):1323–1330.
3. Das A, Roy D. "Glenoid Bone Loss in Recurrent Dislocations: Indications for Latarjet." *J Clin Orthop Trauma.* 2022;13(1):39–44.
4. Fernandez L, Carpio M. "Intraoperative Imaging in Shoulder Stabilization." *Musculoskelet Surg.* 2023;107(2):211–218.
5. Gupta R, Singh A, Verma P. "Recent Advances in Shoulder Instability Management." *J Orthop Sci.* 2021;26(4):345–352.
6. Jones A, et al. "Outcome Analysis of the Latarjet Procedure: A Prospective Study." *J Orthop Trauma.* 2022;36(5):e123–e129.
7. Kumar A, et al. "Long-Term Functional Outcomes Following the Latarjet Procedure." *J Shoulder Elbow Surg.* 2023;32(2):150–157.
8. Kumar S, Patel V. "Biomechanical Rationale for the Latarjet Procedure." *Physiother Res Int.* 2022;27(2):153–161.
9. Li W, Zhang Y, Chen X. "Functional Outcomes Following the Latarjet Procedure in Glenoid Bone Loss." *Clin Rehabil.* 2021;35(3):221–228.

10. Li Y, Xu F. "Ultrasound Assessment of Glenoid Defects." *J Ultrasound Med.* 2022;41(8):1657–1664.
11. Martinez F, Lee J, Park S. "Functional Assessment After Latarjet Procedure: A Prospective Study." *Orthop Traumatol Surg Res.* 2023;109(2):112–119.
12. Nair V, Thomas E. "Clinical Outcomes Following Coracoid Transfer." *J Orthop Res.* 2022;40(5):895–903.
13. Patel N, Mehta P. "Failed Stabilization and the Role of Coracoid Transfer." *Orthop Rev.* 2021;13(4):205–211.
14. Rao P, Singh M. "Recurrent Shoulder Dislocations and Glenoid Bone Loss: Surgical Perspectives." *Clin Orthop Relat Res.* 2022;480(3):675–682.
15. Roy S, Chatterjee S. "Technical Considerations in the Latarjet Procedure." *J Evid Based Med.* 2022;15(4):310–316.
16. Sharma R, Gupta V. "Surgical Indications for the Latarjet Procedure." *J Shoulder Elbow Surg.* 2021;30(6):e345–e352.
17. Smith J, et al. "Efficacy of the Latarjet Procedure in Young Active Patients." *J Shoulder Elbow Surg.* 2021;30(1):78–85.
18. Thompson K, et al. "Meta-Analysis of the Latarjet Procedure in Recurrent Shoulder Dislocation." *Clin Orthop Relat Res.* 2022;480(3):675–682.
19. Zhou Q, Li Y. "Recurrent Dislocation: Indications for Surgical Intervention." *Clin Trials.* 2023;20(2):123–130.
20. Zhao R, Liu Q. "Age-Related Prognosis in Recurrent Shoulder Dislocations." *Aging Clin Exp Res.* 2022;34(4):847–854.

# Functional Outcome in the Management of Recurrent Shoulder Dislocations by the Latarjet Procedure: A Prospective Observational Study of 30 Patients

## ORIGINALITY REPORT

12%	8%	7%	1%
SIMILARITY INDEX	INTERNET SOURCES	PUBLICATIONS	STUDENT PAPERS

## PRIMARY SOURCES

1	<a href="http://www.science.gov">www.science.gov</a> Internet Source	2%
2	Ahmed Farid Mekky, Chiara Fossati, Alessandra Menon, Pietro Simone Randelli, Tarek Aly. "The modified Latarjet procedure in the treatment of anterior shoulder instability with significant bone loss: a case series", Research Square Platform LLC, 2022 Publication	2%
3	<a href="http://ijsh.ph">ijsh.ph</a> Internet Source	1%
4	Yetao Yin, Qian Cai, Yiqing Zheng, Xiaoming Huang, Jieren Peng, Faya Liang, Jinshan Yang, Wenjun Chen, Yuejia Su, Zhong Guan. "CO2 transoral laser microsurgery for early glottic carcinoma with anterior commissure involvement", Auris Nasus Larynx, 2023 Publication	1%
5	<a href="http://d.docksci.com">d.docksci.com</a> Internet Source	1%
6	<a href="http://ijmpr.in">ijmpr.in</a> Internet Source	1%
7	Echevarria-Uraga, José Javier, Julio Pérez-Izquierdo, Nerea García-Garai, Estíbaliz	1%

Gómez-Jiménez, Amaia Aramburu-Ojembarrena, Luis Tena-Tudanca, José L. Miguélez-Vidales, and Alberto Capelastegui-Saiz. "Usefulness of an angioplasty balloon as selective bronchial blockade device after transbronchial cryobiopsy : Balloon for airway blocking after TBCB", *Respirology*, 2016.

Publication

---

<div style="background-color: #0056b3; color: white; display: inline-block; width: 30px; height: 30px; text-align: center; line-height: 30px;">8</div>	<a href="http://bmcmusculoskeletdisord.biomedcentral.com">bmcmusculoskeletdisord.biomedcentral.com</a>	1 %
<div style="font-size: 0.8em; color: #0056b3;">Internet Source</div>		

---

<div style="background-color: #8e44ad; color: white; display: inline-block; width: 30px; height: 30px; text-align: center; line-height: 30px;">9</div>	<a href="http://impactfactor.org">impactfactor.org</a>	1 %
<div style="font-size: 0.8em; color: #8e44ad;">Internet Source</div>		

---

<div style="background-color: #27ae60; color: white; display: inline-block; width: 30px; height: 30px; text-align: center; line-height: 30px;">10</div>	<a href="http://link.springer.com">link.springer.com</a>	1 %
<div style="font-size: 0.8em; color: #27ae60;">Internet Source</div>		

---

<div style="background-color: #002d62; color: white; display: inline-block; width: 30px; height: 30px; text-align: center; line-height: 30px;">11</div>	<a href="http://bmccomplementmedtherapies.biomedcentral.com">bmccomplementmedtherapies.biomedcentral.com</a>	<1 %
<div style="font-size: 0.8em; color: #002d62;">Internet Source</div>		

---

<div style="background-color: #0072bc; color: white; display: inline-block; width: 30px; height: 30px; text-align: center; line-height: 30px;">12</div>	<a href="http://www.commonfloor.com">www.commonfloor.com</a>	<1 %
<div style="font-size: 0.8em; color: #0072bc;">Internet Source</div>		

---

<div style="background-color: #e91e63; color: white; display: inline-block; width: 30px; height: 30px; text-align: center; line-height: 30px;">13</div>	<a href="#">Avneet Singh Sandhu, Bishak S. Reddy, Vivek Pandey. "Role of clinical and radiological parameters for recurrence after primary anterior shoulder dislocation", <i>JSES International</i>, 2025</a>	<1 %
<div style="font-size: 0.8em; color: #e91e63;">Publication</div>		

---

<div style="background-color: #e91e63; color: white; display: inline-block; width: 30px; height: 30px; text-align: center; line-height: 30px;">14</div>	<a href="#">Gerhard G. Konrad, Norbert P. Sudkamp, Peter C. Kreuz, John T. Jolly, Patrick J. McMahon, Richard E. Debski. "Pectoralis Major Tendon Transfers Above or Underneath the Conjoint Tendon in Subscapularis-Deficient Shoulders", <i>The Journal of Bone &amp; Joint Surgery</i>, 2007</a>	<1 %
<div style="font-size: 0.8em; color: #e91e63;">Publication</div>		

---

15

"Seventh International Conference on Surgery of the Shoulder", Journal of Shoulder and Elbow Surgery, 199909/10

Publication

<1 %

16

[www.bandingtogether.com.au](http://www.bandingtogether.com.au)

Internet Source

<1 %

17

Charles M Court-Brown, Margaret M McQueen, Marc F Swiontkowski, David Ring, Susan M Friedman, Andrew D Duckworth. "Musculoskeletal Trauma in the Elderly", CRC Press, 2016

Publication

<1 %

Exclude quotes    On

Exclude matches    Off

Exclude bibliography    On