

# "TREATMENT OF A SINGLE GINGIVAL RECESSION USING CORONALLY ADVANCED FLAP WITH CONNECTIVE TISSUE GRAFT IN A TOOTH WITH SEVERE INTERNAL ROOT RESORPTION: A CASE REPORT"

*by* Jana Publication & Research

---

**Submission date:** 14-Jun-2025 11:56AM (UTC+0700)

**Submission ID:** 2690335440

**File name:** IJAR-52218.docx (2.7M)

**Word count:** 1754

**Character count:** 10229

**“TREATMENT OF A SINGLE GINGIVAL RECESSION USING CORONALLY ADVANCED FLAP WITH CONNECTIVE TISSUE GRAFT IN A TOOTH WITH SEVERE INTERNAL ROOT RESORPTION: A CASE REPORT”**

**Manuscript Info**

**Manuscript History**

Received: xxxxxxxxxxxxxxxx

Final Accepted: xxxxxxxxxxxxxx

Published: xxxxxxxxxxxxxxxx

**Key words:-**

Gingival recession, Miller class II, Internal resorption, Root canal treatment, Mineral trioxide aggregate

**Abstract**

Gingival recession presents both esthetic and functional challenges, especially when compounded by underlying structural defects such as internal root resorption. This case report describes the successful treatment of a single gingival recession defect in the maxillary first molar region using a coronally advanced flap (CAF) combined with a subepithelial connective tissue graft (CTG) in a tooth diagnosed with severe internal resorption. Root canal therapy was completed prior to periodontal surgery. The CAF+CTG approach was selected to achieve root coverage, enhance tissue thickness, and provide long-term stability. At the 6-month follow-up, maximum root coverage, satisfactory esthetics, and significant clinical attachment gain were observed.

Copy Right, IJAR, 2025,. All rights reserved.

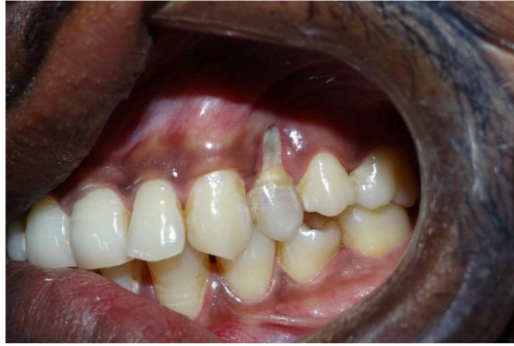**Introduction:-**

Gingival recession is defined as the apical migration of the gingival margin beyond the cemento-enamel junction. It can raise the risk of root caries, cause dentin hypersensitivity, and leads to esthetic problems. The management of single gingival recessions has evolved significantly with the advent of mucogingival surgical techniques aimed at root coverage. Combination of a coronally advanced flap (CAF) with a connective tissue graft (CTG) has shown excellent and consistent results in obtaining complete root coverage and improving tissue thickness and appearance. In this case, RCT (Root canal treatment) was performed to treat the periapical pathology and severe internal resorption prior to periodontal surgery, followed by a well-planned healing period. The purpose of this report is to present the successful management of a single recession defect using CAF and CTG in a tooth diagnosed with severe internal resorption, emphasizing both the surgical technique and the clinical decision-making process involved.

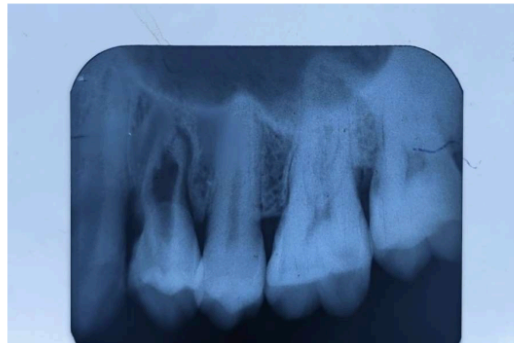**Case Report**

A 25-year-old male reported to our institute Dr. R. Ahmed dental college and hospital Kolkata in department of periodontics with the complaint of receding gum in a single tooth in upper left posterior region.

Intraoral findings presented with Miller's class II gingival recession of 7 mm on tooth #24. Clinical attachment loss (CAL) was 22 mm. The gingival biotype was thin, with minimal keratinized tissue width. IOPAR revealed a well-defined internal resorptive defect in the mid-root region. The tooth was asymptomatic and responded negatively to vitality testing. The diagnosis was made as non-vital tooth with internal root resorption and Miller Class II gingival recession. (Figures 1 and 2 and 3).



**Figure 1:-** Pre-operative view(I/O).



**Figure 2:-** Pre-operative IOPAR

The treatment plan was then finalized with:

1. Endodontic Therapy: Root canal treatment and the resorptive defect will be filled with bioceramic material like MTA.
2. Periodontal Surgery: After healing of the defect, root coverage will be done using a coronally advanced flap (CAF) in conjunction with a connective tissue graft (CTG) harvested from the palate.

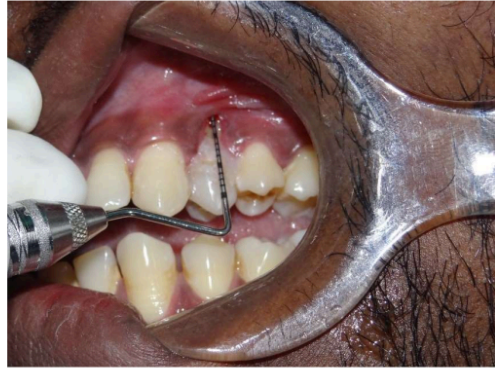

Figure 3:- Pre-operative recession.

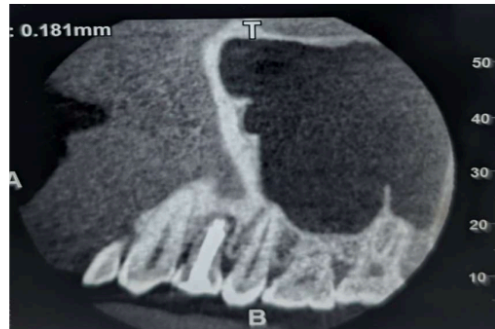


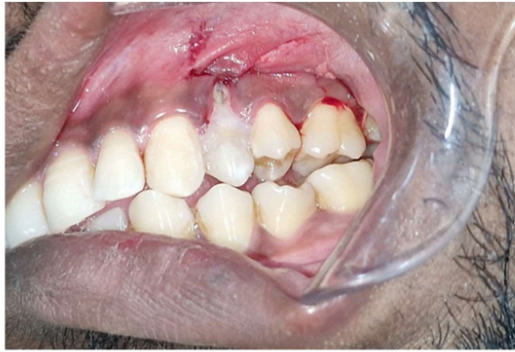Figure 4:- CBCT was done post RCT

<sup>1</sup> Informed consent was taken prior to treatment that explained the benefits, drawbacks, and complications associated with the treatment.

On next appointment root canal treatment was done. As the remaining dentin thickness was very less due to internal resorption, obturation was done using Mineral Trioxide Aggregate (MTA) only. (Figure 4). The patient was then recalled after 3 weeks to check periapical healing. After the healing was satisfactory periodontal flap surgery was done.

<sup>1</sup> The surgical technique for gingival recession coverage was the trapezoidal-type of CAF, fully covering a CTG obtained by means of de-epithelialization of a free gingival graft (FGG). (Figure 6 & 7)

<sup>1</sup> Under local anesthesia, a variable (split-full-split) thickness trapezoidal flap was used to prepare the recipient site with a #15C blade. The flap extended to the raised alveolar mucosa, exposing the roots. The labial submucosal tissue (LST) was isolated and removed using two incisions: one superficial to separate the LST from the inner surface of the alveolar mucosa and one deep to detach it from the periosteum. This gave the CAF a vertical dimension and close adaptation of the alveolar bone and root surfaces. (Figure 5)



**Figure 5:** Incisions given



**Figure 6:-** FGG harvested from palate.

**1** FGG was harvested from the canine to first molar area of the palate, de-epithelialized using a #15C blade extraorally, and trimmed to a thickness of approximately 2 mm. The size of the graft was adjusted to cover the involved teeth. After mechanical treatment of the exposed root surface with Mini-Five™ Gracey curette the CTG was positioned at the level of the CEJ and sutured with single stitches using 5-0 resorbable suture (Vicryl®) to the de-epithelialized papilla. The flap was then positioned at least 1 mm coronally to the CEJ and closed using the same 5-0 resorbable suture for single stitches on the lateral release incision and a coronal sling suture around the teeth. (Figure 8)

#### **19** Post-Operative Care

1. Antibiotics and analgesics were prescribed for 5 days.

2. Chlorhexidine mouth rinse (0.12%) was advised twice daily for 2 weeks.
3. Sutures were removed after 14 days.

The patient was followed up after 1 month. (Figure 9) Patient was satisfied with the overall result of the flap surgery and endodontic treatment after 3 months of follow-up. (Figure 10)

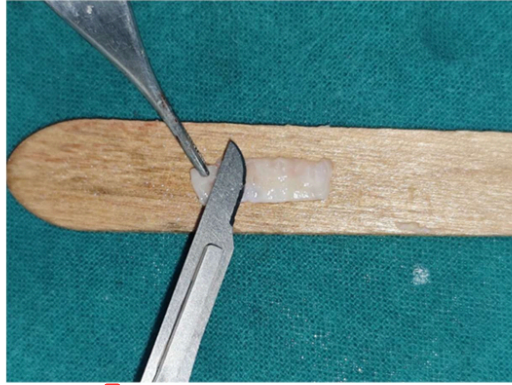


Figure 7:- CTG obtained by means of de-epithelialization of FGG.

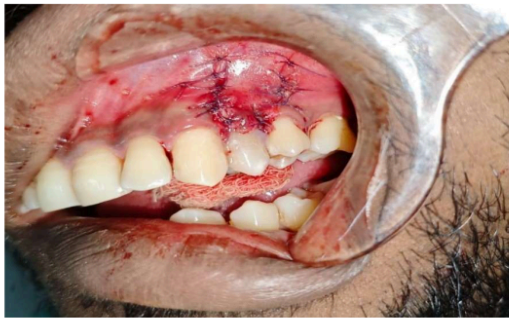

Figure 8:- Closure of CAF above the CEJ.

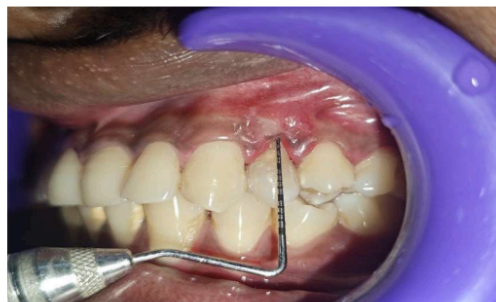

Figure 9:- 1 month follow-up

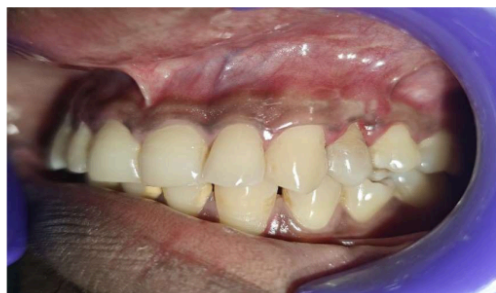

Figure 10:- 3 months follow-up

#### Discussion:-

With the advancement of mucogingival surgical procedures that strive for long-term cosmetic and functional stability in addition to root covering, the management of isolated gingival recession has grown more sophisticated. For Miller Class I and II recession defects, the most reliable and well-established method is still the combination of a coronally advanced flap (CAF) and a connective tissue graft (CTG) [1,2]. The combined advantages of increased vascularization from the graft and increased tissue thickness and durability at the surgical site are primarily responsible for the success of CAF + CTG. Research has repeatedly demonstrated that CTG outperforms CAF alone in terms of root coverage and aesthetic results [3,4]. Furthermore, by preventing future recessions, a thick tissue biotype produced by CTG enhances stability over the long run [5]. Severe internal root resorption, an uncommon and sometimes asymptomatic disorder involving the progressive destruction of the intraradicular dentin, typically brought on by trauma, infection, or chronic pulp inflammation, made this case much more difficult [6]. Internal resorption can weaken teeth and make treatment planning more difficult, especially when it comes to surgical procedures like root covering. These teeth can still be candidates for periodontal therapy, though, if they are appropriately identified and treated endodontically, as they were in this instance. After extensive root canal debridement, the resorptive defect was filled and sealed with bioceramic material i.e MTA. Prior to undergoing any periodontal surgery, the tooth must stay structurally sound and free from microbial leakage.



MTA has proven to have high biocompatibility, sealing ability, and regenerating potential [7]. A number of clinical principles came together in this case to allow for a satisfactory conclusion, such as the tooth being stabilized and the infection being eradicated by proper endodontic therapy. By encouraging revascularization and integration, CTG enhanced tissue biotype. Adequate flap mobilization and tension-free coronal advancement were made possible by CAF. The tooth showed little movement and sufficient periodontal support. The patient showed good color match, dense, healthy tissue, and full root coverage at six months. These results are consistent with those published by Zucchelli et al. and others, who support CAF + CTG as a dependable method even in areas that require aesthetics [1,8]. The significance of soft tissue phenotypic alteration [15] is emphasized in recent literature, particularly in instances that have been treated or are compromised. It has been demonstrated that maintaining sufficient [20] tissue thickness has a favorable impact on the periodontium's long-term stability and health in addition to root coverage [9]. The necessity of a multidisciplinary approach to treatment is further supported by this example, since endodontic and periodontal cooperation can increase the number of teeth that can be reliably preserved and aesthetically repaired, including those that were previously thought to be suspect because of resorptive flaws. Even in structurally impaired roots, prompt and deliberate intervention can enhance recovery, as was observed in the context of acute dental injuries and root fractures [10].

### Conclusion:-

This case demonstrates that successful root coverage with a coronally advanced flap and connective tissue graft is achievable even in the presence of severe internal root resorption, provided the tooth is structurally stabilized through appropriate endodontic intervention. A careful case selection, combined with a multidisciplinary approach and adherence to biologic principles, can lead to optimal clinical and esthetic outcomes. Such comprehensive strategies may broaden the scope of periodontal plastic surgery in managing complex dental cases.

**Source of Funding**  
None.

**Conflict of Interest**  
None.

### References:-

1. Zucchelli G, De Sanctis M. Long-term outcomes following treatment of multiple Miller Class I and II gingival recessions with a coronally advanced flap and connective tissue graft. J Clin Periodontol. 2005;32(5):497-503.
2. Aroca S, Kogevich T, Nikolidakis D, Gera I, Nagy K, Azzi R, et al. Treatment of class III multiple gingival recessions: a randomized clinical trial. J Clin Periodontol. 2010;37(1):88-97.
3. Cairo F, Nieri M, Cincinelli S, Mervelt J, Pini Prato G. The interrelationship between gingival thickness and root coverage outcomes: a systematic review. J Clin Periodontol. 2011;38(9):866-874.
4. Chambrone L, Tatakis DN. Periodontal soft tissue root coverage procedures: a systematic review from the AAP Regeneration Workshop. J Periodontol. 2015;86(2 Suppl):S8-S51.
5. Baldi C, Pini Prato G, Pagliaro U, Nieri M, Saletta D, Muzzi L, et al. Coronally advanced flap procedure for root coverage. Is flap thickness a relevant predictor to achieve root coverage? A 19-case series. J Periodontol. 1999;70(9):1077-1084.
6. Patel S, Ricucci D, Durak C, Tay F. Internal root resorption: a review. J Endod. 2010;36(7):1107-1121.
7. Parirokh M, Torabinejad M. Mineral trioxide aggregate: a comprehensive literature review-Part I: chemical, physical, and antibacterial properties. J Endod. 2010;36(1):16-27.
8. Zucchelli G, Mounssif I. Periodontal plastic surgery. Periodontol 2000. 2015;68(1):333-368.
9. Tavelli L, Barootchi S, Avila-Ortiz G, Urban IA, Giannobile WV, Wang HL. Peri-implant soft tissue phenotype modification and its impact on peri-implant health: A systematic review and network meta-analysis. J Periodontol. 2021;92(1):21-44.
10. Andreasen FM, Andreasen JO, Mejare I, Cvek M. Healing of 400 intra-alveolar root fractures: 1. Effect of pre-injury and injury factors such as sex, age, stage of root development, fracture type, location and severity of dislocation. Dent Traumatol. 2004;20(4):192-202.



# "TREATMENT OF A SINGLE GINGIVAL RECESSON USING CORONALLY ADVANCED FLAP WITH CONNECTIVE TISSUE GRAFT IN A TOOTH WITH SEVERE INTERNAL ROOT RESORPTION: A CASE REPORT"

## ORIGINALITY REPORT

35%

SIMILARITY INDEX

27%

INTERNET SOURCES

27%

PUBLICATIONS

9%

STUDENT PAPERS

## PRIMARY SOURCES

1

[www.ncbi.nlm.nih.gov](http://www.ncbi.nlm.nih.gov)

Internet Source

13%

2

Submitted to Universitas Jenderal Soedirman

Student Paper

5%

3

Antonis Chaniotis, Anastasia Chanioti. "Long-term Complications of Previously Successful Regenerative Endodontic Procedures after Orthodontic Movement: A Report of 3 Different Complications after 4, 8, and 11 Years", Journal of Endodontics, 2022

Publication

2%

4

Pravin Raipure, Ravindra Pawar, Vishwas Kharsan. "Rehabilitation of the patient with ceramic laminate veneers having midline diastema and rotated maxillary central incisors associated with highly attached maxillary labial frenum- A case report", International Journal of Oral Health Dentistry, 2023

Publication

1%

5

[bmcoralhealth.biomedcentral.com](http://bmcoralhealth.biomedcentral.com)

Internet Source

1%

6

Submitted to University of Sydney

Student Paper

1%

7

Khadija Amine, Wafa El Kholiti, Jamila Kissa. "Periodontal Root Coverage", Springer

1%

8	Submitted to Universidad Europea de Madrid Student Paper	1 %
9	<a href="http://www.nature.com">www.nature.com</a> Internet Source	1 %
10	"PC072: Coronally advanced flap and connective tissue graft combination in multiple recessions with thin tissue biotype: a case report", Journal of Clinical Periodontology, 2018 Publication	1 %
11	<a href="http://ijrpr.com">ijrpr.com</a> Internet Source	1 %
12	<a href="http://acikbilim.yok.gov.tr">acikbilim.yok.gov.tr</a> Internet Source	1 %
13	<a href="http://drsuhasis.blogspot.com">drsuhasis.blogspot.com</a> Internet Source	1 %
14	<a href="http://www.idakerala.com">www.idakerala.com</a> Internet Source	1 %
15	<a href="http://doktori.bibl.u-szeged.hu">doktori.bibl.u-szeged.hu</a> Internet Source	<1 %
16	<a href="http://go.digitalsmiledesign.com">go.digitalsmiledesign.com</a> Internet Source	<1 %
17	<a href="http://hi.tamu.edu">hi.tamu.edu</a> Internet Source	<1 %
18	<a href="http://ipindexing.com">ipindexing.com</a> Internet Source	<1 %
19	<a href="http://repository-tnmgrmu.ac.in">repository-tnmgrmu.ac.in</a> Internet Source	<1 %
20	<a href="http://www.researchgate.net">www.researchgate.net</a> Internet Source	<1 %

21	"Poster Abstracts", Journal Of Clinical Periodontology, 2012. Publication	<1 %
22	3D Imaging in Endodontics, 2016. Publication	<1 %
23	Ahmedbeyli, Cavid, Şebnem Dirikan İpçi, Gokser Cakar, Bahar E. Kuru, and Selçuk Yılmaz. "Clinical evaluation of coronally advanced flap with or without acellular dermal matrix graft on complete defect coverage for the treatment of multiple gingival recessions with thin tissue biotype", Journal Of Clinical Periodontology, 2014. Publication	<1 %
24	Evgeny Weinberg, Roni Kolerman, Lazar Kats, Omer Cohen, Daya Masri, Alon Sebaoun, Gil Slutzkey. "Coronally Advanced Flap with Connective Tissue Graft for Treating Orthodontic-Associated Miller Class III Gingival Recession of the Lower Incisors: A One-Year Retrospective Study", Journal of Clinical Medicine, 2022 Publication	<1 %
25	Lorenzo Tavelli, Shayan Barootchi, Riccardo Di Gianfilippo, Marmar Modarressi et al. "Acellular dermal matrix and coronally advanced flap or tunnel technique in the treatment of multiple adjacent gingival recessions. A 12-year follow-up from a randomized clinical trial", Journal of Clinical Periodontology, 2019 Publication	<1 %
26	Yu Wang, Panagiota G. Stathopoulou. "Tunneling Techniques for Root Coverage", Current Oral Health Reports, 2019 Publication	<1 %

27

Zucchelli, Giovanni, and Ilham Mounssif.  
"Periodontal plastic surgery", Periodontology  
2000, 2015.

Publication

<1 %

Exclude quotes On

Exclude matches Off

Exclude bibliography On