

Management of Membranous Glomerulonephritis-Efficacy of Mycophenolate Mofetil: A Case Report and Literature Review

by Jana Publication & Research

Submission date: 14-Jun-2025 04:27PM (UTC+0700)

Submission ID: 2690327030

File name: IJAR-52240.docx (378.5K)

Word count: 2202

Character count: 13973

Management of Membranous Glomerulonephritis-Efficacy of Mycophenolate Mofetil: A Case Report and Literature Review

Abstract

Idiopathic membranous glomerulonephritis (MGN) is a leading cause of nephrotic syndrome in adults and is associated with a significant risk of progression to end-stage renal disease. While immunosuppressive agents such as cyclophosphamide and rituximab are commonly used, their long-term use is limited by substantial side effects. Mycophenolate mofetil (MMF), a more tolerable immunosuppressant, has demonstrated promising efficacy in other glomerular diseases, though its role in idiopathic MGN remains underexplored. We report the case of a 55-year-old male with biopsy-proven stage II idiopathic MGN, who showed no improvement on angiotensin receptor blocker therapy. Due to deteriorating renal function, a second biopsy was performed, revealing lupus-like histologic features despite a negative immunologic workup. MMF combined with low-dose prednisone was initiated, leading to a sustained remission over an 8-year period, with stable renal function and marked reduction in proteinuria. Relapses occurred following discontinuation of MMF, underscoring its therapeutic importance. A third biopsy confirmed persistent idiopathic MGN, with no secondary cause identified. Although not currently recommended by KDIGO guidelines for idiopathic MGN, MMF may offer an effective and steroid-sparing alternative to conventional regimens. This case highlights the potential of MMF as a long-term treatment option with good efficacy and tolerability, particularly for patients with contraindications to standard immunosuppressive therapies.

keywords: Idiopathic membranous glomerulonephritis Mycophenolate mofetil, Immunosuppression, renal function, proteinuria ;alternative therapy, renal biopsy, relapse

Introduction

Membranous Glomerulonephritis (MGN) is a renal disease characterized by significant proteinuria and a high risk of renal failure. The primary challenge in its management lies in controlling proteinuria and preserving long-term renal function while minimizing the adverse effects of conventional immunosuppressive therapies. Mycophenolic acid (MMF), known for its efficacy and safety, has emerged as a promising alternative, particularly in other glomerular diseases such as systemic lupus erythematosus.

In this context, we report the case of a patient with idiopathic membranous glomerulonephritis (MGN) who was followed for eight years. The patient exhibited a significant clinical improvement under MMF therapy combined with low-dose corticosteroids, with a marked reduction in proteinuria and long-term preservation of renal function. This case highlights the efficacy and tolerability of this therapeutic approach, offering an alternative to traditional treatments while reducing the risk of adverse effects associated with cytotoxic immunosuppressants and high-dose corticosteroids.

Case Presentation

A 55-year-old patient, with no significant medical, surgical, or toxicological history, and without diabetes or hypertension, was admitted in 2015 for an incomplete nephrotic syndrome.

Medical History

The symptoms began two months prior to admission with the gradual onset of bilateral pitting edema of lower limbs, accompanied by weight gain. The patient initially consulted a private nephrologist, who initiated nephroprotective treatment with angiotensin II receptor blockers (ARBs). Due to the absence of clinical improvement, hospitalization was decided in our department.

Clinical Examination on Admission

On admission, the patient was conscious with a Glasgow Coma Scale score of 15/15. Hemodynamically, he was stable, with a blood pressure of 150/100 mmHg. Clinical examination revealed signs of fluid overload, including pitting edema of the lower limbs extending to the mid-legs. Respiratory assessment showed an oxygen saturation of 100% on room air, with pulmonary auscultation revealing no crackles.

Figure1: Biological Test Results

| Parameter | Result |
|---------------------------|---|
| Creatinine | 32 mg/L |
| Urea | 0.69 g/L |
| Total Proteins | 47 g/L |
| Albumin | 22 g/L |
| Hemoglobin | 10.8 g/dL |
| Reticulocyte Count | 50,500/mm ³ |
| Total Cholesterol | 3.02 g/L |
| LDL-Cholesterol | 2.21 g/L |
| Triglycerides | 1.84 g/L |
| Proteinuria/Creatininuria | 19 g/g (essentially albumin) |
| Urinalysis (ECBU) | RBC 10/mm ³ , WBC 5/mm ³ |
| Urinary Electrolytes | Sodium 16 mmol/L, Potassium 51 mmol/L, Chloride 48 mmol/L |
| CRP | Negative |
| Hemostasis | PT: 93%, Bleeding time: 3 min 37 s |

A renal biopsy was performed: The report describes a stage II membranous glomerulonephritis (MGN), characterized by diffuse thickening of capillary walls and the presence of spikes on silver and PAS staining, without cellular proliferation or interstitial inflammation. Immunofluorescence reveals extramembranous IgG deposits, along with more moderate deposits of IgM and C3, confirming the diagnosis of MGN. The absence of inflammatory infiltrates, interstitial edema, and tubular atrophy is reassuring, as it suggests the lack of advanced chronic lesions.

Figure 2: Etiological Workup of Stage 2 Membranous Glomerulonephritis (MGN)

| Category | Results |
|-------------------------|--|
| Immunological | - ANA, Anti-native DNA, ANCA (MPO and PR3), Anti-GBM: negative - C3 and C4: not consumed - Anti-PLA2R antibodies: negative |
| Tumoral | - CA-125, CA 19-9, Alpha-fetoprotein, LDH, PSA: negative |
| Thyroid | - TSH, Anti-TG, Anti-TPO: normal rate |
| Viral serologies | - Hepatitis, HIV, Syphilis: negative |
| Imaging | - Thoraco-abdominopelvic CT scan: no abnormalities |
| Protein electrophoresis | - Hypoproteinemia with marked hypoalbuminemia |

The initial management included the introduction of a nephroprotective treatment with an angiotensin II receptor antagonist (ARB), along with a statin for dyslipidemia and an antiplatelet agent for cardiovascular prevention.

One month later, the patient's condition worsened, with a decline in renal function reflected by an increase in creatinine levels from 26 to 32 mg/L, while proteinuria remained stable at 6 g/g. A renal Doppler ultrasound ruled out any renal artery stenosis or thrombosis, prompting the indication for a second renal biopsy.

Main histological findings:

Glomeruli: Diffuse basement membrane thickening with spikes, but no cellular proliferation or ischemic lesions.

Tubules: Tubular necrosis (10%), moderate tubular atrophy and interstitial fibrosis (20%), with mil

inflammatory infiltrates.
Vessels: Mild fibrous endarteritis.
Immunofluorescence: Granular, intense, and diffuse extramembranous IgG deposits, with no significant deposits of C3, C1q, IgA, or IgM.

This biopsy is suggestive of lupus membranous nephropathy (class V), characterized by predominant extramembranous IgG immune deposits. The presence of moderate tubulointerstitial lesions and mild fibrous endarteritis may indicate an associated chronic process.

Repeated immunological workup: Still negative.

Therapeutic Decision:

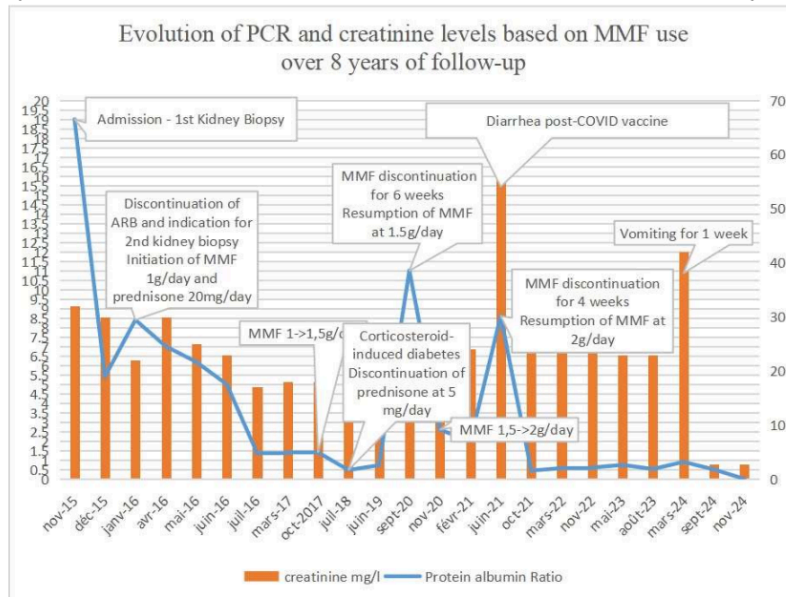
Given the membranous glomerulonephritis with lupus-like features, the patient was started on immunosuppressive therapy. Treatment included mycophenolate mofetil (MMF) at a dose of 1 g/day, along with low-dose corticosteroid therapy using prednisone at 20 mg/day.

Long-term follow-up over eight years showed stable renal function, with creatinine levels ranging between 17 and 25 mg/L. However, two episodes of acute kidney function deterioration were observed, both occurring in the context of vomiting and post-COVID vaccination diarrhea.

Regarding proteinuria, a significant reduction was noted following the introduction of MMF. However, episodes of increased proteinuria were observed during periods of patient-initiated discontinuation of treatment, highlighting the impact of medication adherence.

Throughout the follow-up, nephroprotective treatment was maintained. The stability of creatinine levels and effective proteinuria control under MMF reinforce the importance of long-term adherence to treatment in ensuring disease control and preventing progression.

Figure 3: Combined diagram showing the evolution of CRP and creatinine levels during the follow-up



The patient was last hospitalized in September 2024 due to worsening renal function following one week of vomiting. Management included rehydration, which led to an improvement in creatinine levels from 32 to 25 mg/L. A third kidney biopsy confirmed the diagnosis of stage 2 membranous glomerulonephritis (MGN). An updated etiological assessment, including immunological, infectious (viral serologies), and tumor screenings, was negative. There was no history of toxic drug intake, such as NSAIDs, penicillin, gold salts, or mercury salts, and a thoraco-abdominopelvic CT scan was unremarkable. Anti-PLA2R antibodies were also negative. In the absence of a secondary etiology and with negative immunological markers, the final diagnosis was idiopathic MGN. The patient continues treatment with MMF under close monitoring to prevent exacerbations and ensure adherence. MMF has demonstrated a beneficial effect in maintaining complete remission, with proteinuria remaining below 0.5 g/g and stable renal function over an eight-year follow-up.

Discussion :

Idiopathic membranous glomerulonephritis (MGN) is one of the most common causes of nephrotic syndrome in adults worldwide [1][2]. Studies on the natural history of idiopathic membranous glomerulonephritis (MGN) show that 5% to 30% of patients experience spontaneous complete remission of proteinuria within 5 years, while 40% achieve partial remission. However, 30% to 40% of patients will progress to end-stage renal failure within 5 to 15 years. [3][4].

The treatment of idiopathic membranous glomerulonephritis (MGN) primarily involves conservative management and immunosuppressive therapy. Supportive treatment includes angiotensin-converting enzyme (ACE) inhibitors, angiotensin receptor blockers, a low-salt and low-protein diet, and statins, which are initiated in all patients for 6 months [5].

Immunosuppressive therapy can induce disease remission and reduce the risk of progression to end-stage renal failure or death [6][7]. However, given the slow progression of the disease and the high rate of spontaneous remission, immunosuppressive agents are primarily recommended for patients with complications related to nephrotic syndrome or those at high risk of progression [8].

Mycophenolate mofetil (MMF) is an effective immunosuppressant that inhibits antibody formation and the proliferation of T and B lymphocytes, thereby reducing the expression of adhesion molecules on lymphocytes [9]. Small randomized studies have shown that MMF, in combination with corticosteroids, is as effective as traditional cytotoxic agents in treating idiopathic membranous glomerulonephritis (MGN) [10][11]. Although this combination is not recommended by the latest Kidney Disease Improving Global Outcomes (KDIGO) guidelines, it serves as an alternative to the mPR protocol (prednisone and cyclophosphamide) due to its better tolerance and steroid-sparing effect. [12].

A randomized controlled trial conducted in South Korea compared the efficacy of MMF versus cyclosporine (CsA), both combined with low-dose corticosteroids, in 39 patients with idiopathic MGN. The results showed that both MMF and CsA were effective in reducing proteinuria, with a favorable trend for MMF in terms of remission, without any negative impact on renal function. [13].

Similarly, a study compared the efficacy of 13 immunosuppressive agents—tacrolimus + *Tripterygium wilfordii* (TAC+TW), cyclosporine (CsA), mycophenolate mofetil (MMF), cyclophosphamide (CTX), rituximab (RIT), chlorambucil (CH), leflunomide (LEF), mizoribine (MZB), steroids (STE), azathioprine (AZA), and adrenocorticotrophic hormone (ACTH)—in 2,736 patients with idiopathic MGN. The results showed that tacrolimus and cyclophosphamide were the most effective in inducing complete remission, but MMF also demonstrated a notable effect, even surpassing rituximab and cyclosporine in efficacy [14]. In terms of reducing 24-hour urinary protein excretion (UTP), tacrolimus + *Tripterygium wilfordii* (TAC+TW) demonstrated the highest efficacy [15].

More recently, a study conducted in India compared the efficacy and safety of MMF + steroids (S) versus the mPR regimen in patients with idiopathic MGN. After six months, both groups showed similar improvements in serum albumin levels, glomerular filtration rate, and proteinuria reduction, with comparable remission rates. However, MMF + S had the advantage of reducing steroid exposure [16].

Conclusion :

All these findings support the benefit of MMF in the management of idiopathic MGN. Although this treatment is more commonly used in lupus nephritis, our case demonstrated a favorable outcome under MMF, despite an initial misdiagnosis of lupus-related MGN. This case suggests that MMF could be a therapeutic option to consider in certain idiopathic MGN cases, particularly when standard treatments are unavailable, contraindicated, or insufficiently effective. Additionally, regular

monitoring and long-term reassessment are essential to evaluate and confirm the durability of the response.

Bibliography

1. Haas M, Meehan SM, Karrison TG, Spargo BH. Changing etiologies of unexplained adult nephrotic syndrome: a comparison of renal biopsy findings from 1976–1979 and 1995–1997. *Am J Kidney Dis* 1997;30(5):621-31.
2. Naumovic R, Pavlovic S, Stojkovic D, Basta-Jovanovic G, Nasic V. Renal biopsy registry from a single centre in Serbia: 20 years of experience. *Nephrol Dial Transplant* 2009;24(3):877-85.
3. Schieppati A, Mosconi L, Perna A, Mecca G, Bertani T, Garattini S, et al. Prognosis of untreated patients with idiopathic membranous nephropathy. *N Engl J Med* 1993;329(2):85-9.
4. Honkanen E, Törnroth T, Grönhagen-Riska C. Natural history, clinical course and morphological evolution of membranous nephropathy. *Nephrol Dial Transplant* 1992;7 Suppl 1:35-41.
5. Larsen CP, Cossey LN, Beck LH. THSD7A staining of membranous glomerulopathy in clinical practice reveals cases with dual autoantibody positivity. *Mod Pathol* 2016;29:421–6.
6. Hofstra JM, Wetzels JFM. Management of patients with membranous nephropathy. *Nephrol Dial Transplant* 2012;27:6–9.
7. Debiec H, Ronco P. Immunopathogenesis of membranous nephropathy: an update. *Semin Immunopathol* 2014;36:381–97.
8. Cattran DC, Feehally J, Cook HT, et al. Kidney disease: improving global outcomes (KDIGO) glomerulonephritis work group. KDIGO clinical practice guideline for glomerulonephritis. *Kidney International Supplements* 2012;2:139–274.
9. Allison AC, Eugui EM. Preferential suppression of lymphocyte proliferation by mycophenolic acid and predicted long-term effects of mycophenolate mofetil in transplantation. *Transplant Proc* 1994;26(6):3205-10.
10. Chan TM, Lin AW, Tang SC, Qian JQ, Lam MF, Ho YW, et al. Prospective controlled study on mycophenolate mofetil and prednisolone in the treatment of membranous nephropathy with nephrotic syndrome. *Nephrology (Carlton)* 2007;12(6):576-81.
11. Senthil Nayagam L, Ganguli A, Rathi M, Kohli HS, Gupta KL, Joshi K, et al. Mycophenolate mofetil or standard therapy for membranous nephropathy and focal segmental glomerulosclerosis: a pilot study. *Nephrol Dial Transplant* 2008;23(6):1926-30.
12. Kidney Disease Improving Global Outcomes (KDIGO) Glomerulonephritis Work Group. KDIGO clinical practice guideline for glomerulonephritis. *Kidney Int Suppl* 2012;2:139–274.
13. The Effect of Mycophenolate Mofetil versus Cyclosporine as Combination Therapy with Low Dose Corticosteroids in High-risk Patients with Idiopathic Membranous Nephropathy: a Multicenter Randomized Trial. *J Korean Med Sci* 2018;33:e74.

14. Zheng Q, Yang H, Liu W, Sun W, Zhao Q, Zhang X, et al. Comparative efficacy of 13 immunosuppressive agents for idiopathic membranous nephropathy in adults with nephrotic syndrome: a systematic review and network meta analysis.

15. Qiyan Zheng, et al. Efficacy of tacrolimus and tacrolimus + tripterygium wilfordii (TAC+TW) in membranous nephropathy.

16. Sharma M, Roy A, Doley PK, Pegu G. Mycophenolate Mofetil with Steroid, a Reasonable Alternative to Current First-line Therapy, for Idiopathic Membranous Nephropathy in Resource-constrained Settings: A Randomized, Open-label Study.

vv

Management of Membranous Glomerulonephritis-Efficacy of Mycophenolate Mofetil: A Case Report and Literature Review

ORIGINALITY REPORT

20%

SIMILARITY INDEX

13%

INTERNET SOURCES

19%

PUBLICATIONS

2%

STUDENT PAPERS

PRIMARY SOURCES

| | | |
|---|--|----|
| 1 | bmjopen.bmj.com Internet Source | 3% |
| 2 | Textbook of Clinical Pediatrics, 2012. Publication | 3% |
| 3 | jkms.org Internet Source | 3% |
| 4 | Ugo Bertoldo. "Retrograde Venous Bullet Embolism: A Rare Occurrence???Case Report and Literature Review", The Journal of Trauma Injury Infection and Critical Care, 07/2004 Publication | 1% |
| 5 | Submitted to Post Graduate Institute of Medical Education and Research Student Paper | 1% |
| 6 | jim.bmj.com Internet Source | 1% |
| 7 | discovery.ucl.ac.uk Internet Source | 1% |
| 8 | Laurent Lagrost, Anne Athias, Nicole Lemort, Jean-Louis Richard et al. "Plasma lipoprotein distribution and lipid transfer activities in patients with type IIb hyperlipidemia treated with simvastatin", Atherosclerosis, 1999 Publication | 1% |
| 9 | medicaldialogues.in Internet Source | 1% |

| | | |
|----|---|------|
| 10 | DAVID HARRIS. "Prevention of Progression of Kidney Disease", Nephrology, 4/2006 Publication | <1 % |
| 11 | www.cureus.com Internet Source | <1 % |
| 12 | "Pediatric Kidney Disease", Springer Science and Business Media LLC, 2016 Publication | <1 % |
| 13 | M. Ladino. "Recurrent idiopathic membranous nephropathy in the renal allograft: successful treatment with the anti-CD20 monoclonal antibody rituximab", NDT Plus, 06/17/2009 Publication | <1 % |
| 14 | archive.org Internet Source | <1 % |
| 15 | journals.lww.com Internet Source | <1 % |
| 16 | www.frontiersin.org Internet Source | <1 % |
| 17 | www.medilib.ir Internet Source | <1 % |
| 18 | "Encyclopedia of Medical Immunology", Springer Science and Business Media LLC, 2014 Publication | <1 % |
| 19 | Chen, Yizhi, Arrigo Schieppati, Xiangmei Chen, Guangyan Cai, Javier Zamora, Giovanni A Giuliano, Norbert Braun, Annalisa Perna, and Annalisa Perna. "Immunosuppressive treatment for idiopathic membranous nephropathy in adults with nephrotic | <1 % |

syndrome", Cochrane Database of Systematic Reviews, 2014.

Publication

20

Core Concepts in Parenchymal Kidney Disease, 2014.

<1 %

Publication

21

Matthias Behrend. "Mycophenolate Mofetil", BioDrugs, 2001

<1 %

Publication

22

"Glomerulonephritis", Springer Science and Business Media LLC, 2019

<1 %

Publication

23

J. Bone. "'Progressive' versus 'indolent' idiopathic membranous glomerulonephritis", QJM, 11/01/1997

<1 %

Publication

24

MINGHUI ZHAO. "Clinical observations of mycophenolate mofetil therapy in refractory primary nephrotic syndrome", Nephrology, 6/2003

<1 %

Publication

Exclude quotes On

Exclude matches Off

Exclude bibliography On