

TREATMENT OF A SINGLE TOOTH WITH MILLER'S CLASS I GINGIVAL RECESSION DEFECT BY CORONALLY ADVANCED FLAP (CAF) IN CONJUNCTION WITH CONNECTIVE TISSUE GRAFT (CTG)- A CASE REPORT.

by Jana Publication & Research

Submission date: 05-Jul-2025 12:12PM (UTC+0700)

Submission ID: 2692519020

File name: IJAR-52635.docx (991.46K)

Word count: 1895

Character count: 11014

TREATMENT OF A SINGLE TOOTH WITH MILLER'S CLASS I GINGIVAL RECESSIION DEFECT BY CORONALLY ADVANCED FLAP (CAF) IN CONJUNCTION WITH CONNECTIVE TISSUE GRAFT (CTG)- A CASE REPORT.

Manuscript Info

Manuscript History

Received: xxxxxxxxxxxxxxxx

Final Accepted: xxxxxxxxxxxx

Published: xxxxxxxxxxxxxxxx

Key words:-

Connective tissue graft(s),
gingival recession, periodontal
plastic surgery, root coverage

Due to cosmetic concerns or
sensitivity of root, treating
buccal gingival recessions is
often necessary. Complete
coverage of the recession defect

Abstract

with a pleasant colour and tissue integration between the treated area
and neighbouring tissue should be the ultimate goal of root coverage
techniques, thereby attaining success in terms of both biology and
appearance. Patient with recession in upper left canine tooth had
undergone recession coverage surgery by Coronally Advanced Flap
(CAF) with Connective Tissue Graft (CTG) harvested from palate. The
patient was reviewed for a period of 8 months. The recession coverage
was complete and aesthetically pleasing. A diverse array of surgical
treatments has been presented over the decades for the treatment of
gingival recessions. The adjunctive use of CTG under CAF enhanced
the likelihood of attaining complete root coverage in Miller Class I
recession situation.

Copy Right, IJAR, 2025. All rights reserved.

Introduction:-

Gingival recession or soft tissue recession is defined as the displacement of the gingival margin apical to the
cemento-enamel junction (CEJ) of a tooth.(1) Untreated gingival recession tends to exhibit progressive apical
displacement over time.(2) (3) Gingival recession, which exposes the root surface, is commonly associated with
dentin hypersensitivity, root caries, non-caries cervical lesions (NCCLs), compromised plaque control, and
unaesthetic appearance.(4) The ultimate goal of a root coverage procedure is the complete coverage of the recession
defect with good appearance related to adjacent soft tissues and minimal probing depth (PD) (5)

Like in many other periodontal conditions, the aetiology of gingival recessions is multifactorial and complex, with
its exact mechanism not fully understood yet. It intertwines predisposing anatomic risk factors-such as bone
dehiscence, gingival width and thickness insufficiency, tooth malposition, aberrant attachment of the labial frenulum
with precipitating factors such as inflammation related to plaque, improper tooth brushing habit, smoking, chronic
trauma because of traumatic incisor relationship and iatrogenic factors related to improper restorative, prosthetic,
orthodontic and periodontal procedures.

One popular method for root covering is the coronally advanced flap (CAF) surgery. The coronal displacement of
the soft tissues on the exposed root surface serves as the basis for this process. This approach may be used alone or
in combination with subepithelial or connective tissue graft (6), Barrier Membrane(BM) (7), enamel matrix
derivative (EMD) (Rasperini et al.2000) acellular dermal matrix (ADM) (8), platelet-rich plasma (PRP) (Marx et al.
1998) and living tissue-engineered human fibroblast derived dermal substitute (HF-DDS) (9).

When choosing a treatment plan, physicians should take patient and tooth-related aspects into account.

The purpose of this case report is to present successful management of a single tooth with Miller's Class I gingival
recession by CAF with CTG.

CASE REPORT

A 27 year old male came to the OPD of Department of Periodontics, Dr. R. Ahmed Dental college and Hospital, Kolkata with chief complain of gingival displacement away from the tooth margin of upper left canine (#23) along with sensitivity on taking cold. He also complained about unaesthetic look due to mismatch of gingival position with adjacent tooth.

On intra oral examination it was seen as Miller's class I gingival recession of 3 mm on tooth #23. Clinical attachment loss (CAL) was 4 mm. Probing pocket depth (PPD) was found to be 1 mm. The gingival biotype was thin, with keratinized tissue width of 2 mm.

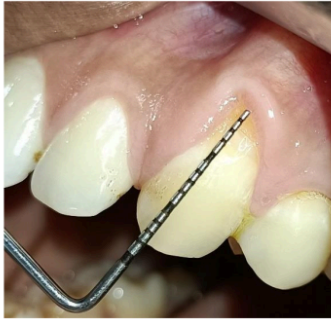

Figure 1: Pre Operative View

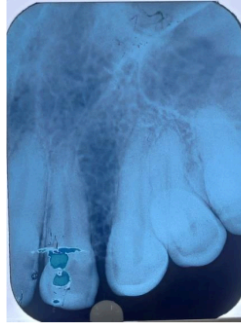


Figure 2(a) Pre operative IOPAR

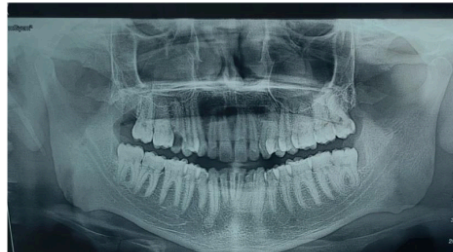

Figure 2(b) Pre operative OPG

Treatment plan: Root coverage utilizing a coronally advanced flap (CAF) alongside a connective tissue graft (CTG) harvested from the palate.

The patient was clinically healthy. Informed consent was obtained before the procedure, detailing the advantages, disadvantages, and any difficulties connected with the treatment.

The surgical method for addressing gingival recession involved a trapezoidal-type flap (Figure 3), which completely enveloped a connective tissue graft (CTG) derived from the de-epithelialization of a free gingival graft (FGG) (Figure 4)

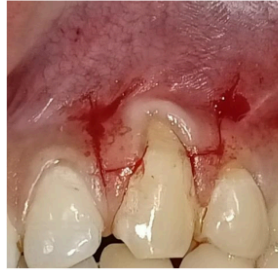

Figure 3: Primary incision



Figure 4: FGG harvested from palate and de-epithelialization done

A trapezoidal flap of varied thickness (split–full–split) ^a as prepared at the recipient site using a #15C blade under local anaesthesia. Both the horizontal incisions were 3 mm long made at a distance from anatomical papilla tip equals to recession depth plus 1 mm and two diverging vertical releasing incisions extended as far as the alveolar mucosa.

The anatomical papilla was de-epithelialized using a knife blade and microsurgical scissors.

Using a mini five Gracey curette, the exposed root surface was mechanically debrided.

The fully de-epithelialized connective tissue ²³ graft was 6 mm wider mesio distally than the recession's width at the prosthetic collar and 1 mm more in height than the depth of root exposure. Two interrupted ²⁴ stitches with 5-0 resorbable suture (Vicryl®) was placed at the base of the papillae attaching the grafted tissue to the facial keratinized tissue of the neighbouring teeth secure the graft 1 mm coronally to the prosthetic collar.

⁵ For the full coverage of the connective tissue graft, the flap ^{is} advanced coronally. ^{Then}, starting at the mesial releasing incision's most apical extension, it was fastened a sequence of simple interrupted sutures with 5-0 resorbable suture (Vicryl®) along the releasing incisions, moving apico coronally. To snugly fit the coronal flap border over the prosthetic crown convexity, the final sling suture had compressed the surgical papillae against the corresponding de-epithelialized anatomical papillae. (Figure 5)

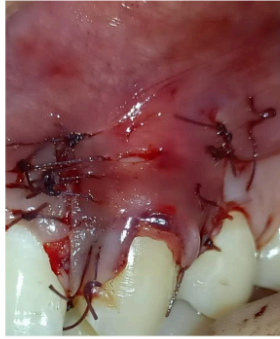

Figure 5: Immediate post surgical situation

Following Surgery,

1. For 5 days, analgesics and antibiotics were prescribed.
2. For 2 weeks, a mouthwash containing 0.2% chlorhexidine was advised to use twice a day.
3. After 14 days, the sutures were removed.

Patient was followed up after 14 days (figure 6), 1 month (figure 7), 4 months (figure 8) and 8 months (figure 9)

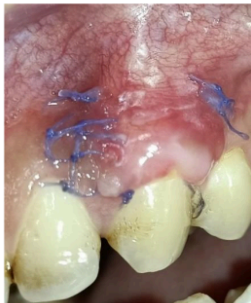

Figure 6: 14 days follow up

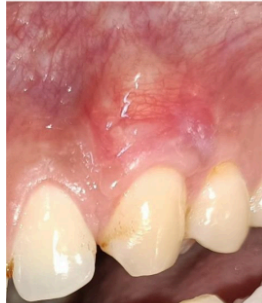

Figure 7: 1 month follow up

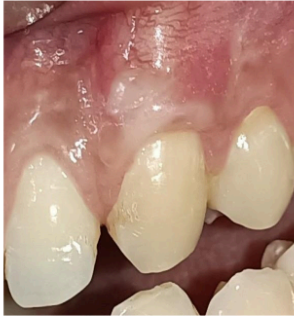

Figure 8: 4 month follow up

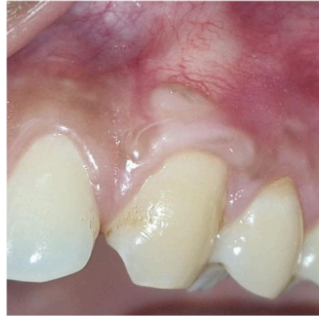

Figure 9: 8 month follow up

On 8 month follow up, ¹¹ pocket depth was found of 2 mm and a CAL gain of 4 mm. ¹⁸ Complete root coverage was achieved. The keratinized tissue width increased from 2 mm to 3 mm. The patient showed good colour match, dense, healthy tissue and full root coverage. The patient was pleased with the recession coverage surgery's overall outcome and appearance.

DISCUSSION:

Gingival recession is a prevalent clinical disease marked by the ³⁰ apical displacement of the gingival ³² e, potentially resulting in aesthetic issues, dentin hypersensitivity, and an elevated risk of root caries (10). Miller's Class I recession defects, with no loss of interdental bone or soft tissue and complete root coverage potential, present an ideal scenario for surgical root coverage procedures (11).

⁸ The main goal of treatment for gingival recession is complete root coverage. Furthermore, clinicians anticipate ¹⁹ improvements in the tissues' natural look, keratinized tissue width (KTW), clinical attachment level (CAL), and long-term stability of the results.

The treatment of isolated gingival recession has become more predictable with the development of mucogingival surgical techniques that aim for long-term aesthetic and functional stability in addition to root covering. CAF alone is beneficial for correcting Miller's Class I and II deficiencies; however, its combination with CTG specially where the gingival thickness is $\leq 0.8\text{mm}$. yields enhanced results regarding root coverage, augmentation of keratinized tissue width and long-term stability due to thick tissue biotype produced by CTG (12). The connective tissue graft acts as a biologic matrix that promotes revascularization and supports the overlying flap, leading to improved tissue thickness and better aesthetic integration (6). Recent research has also highlighted the importance of soft tissue phenotypic alteration, which can be achieved due to addition of CTG.

In this instance, whole root coverage was attained, and the patient indicated an enhancement in aesthetic satisfaction and a decrease in dentin hypersensitivity. Similar findings have been reported by Harris (1997) (8), who observed higher mean root coverage and increased thickness of keratinized tissue when CAF was combined with CTG, compared to CAF alone.

²⁷ Furthermore, the selection of connective tissue graft (CTG) obtained from the palate is considered the gold standard (13) owing to its enhanced integration and reduced likelihood of graft necrosis (14). The donor site healing was

uneventful in our case, and patient discomfort was minimal, highlighting the importance of meticulous surgical technique and post-operative care.

Long-term studies have ²⁶ demonstrated that the combination of CAF and CTG not only provides immediate root coverage but also maintains stability over time (15). Our case adds ³¹ this body of evidence, supporting the predictability and effectiveness of this approach for treating single tooth Miller's Class I defects.

CONCLUSION:

²⁴ This case shows that a coronally advanced flap and connective tissue graft can successfully cover roots. The best clinical and aesthetic results might result from a meticulous case selection process that follows biologic principles. This case study highlights the need of personalized treatment planning and the choice of approaches that enhance both practical and aesthetic results.

Source of Funding

None.

Conflict of Interest

None.

REFERENCES:

1. Mucogingival Deformities - Prato - 1999 - Annals of Periodontology - Wiley Online Library.
2. Periodontal Conditions of Sites Treated with Gingival-Augmentation Surgery Compared to Untreated Contralateral Homologous Sites: A 10- to 27-Year Long-Term Study - Agudio - 2009 - Journal of Periodontology - Wiley Online Library.
3. Long-Term Outcomes of Untreated Buccal Gingival Recessions: A Systematic Review and Meta-Analysis - Chambrone - 2016 - Journal of Periodontology - Wiley Online Library.
4. The Evolution of Buccal Gingival Recessions in a Student Population: A 5-Year Follow-Up - Dapirle - 2007 - Journal of Periodontology - Wiley Online Library.
5. Periodontal plastic surgery for treatment of localized gingival recessions: a systematic review - Rocuzzo - 2002 - Journal of Clinical Periodontology - Wiley Online Library .
6. Subepithelial Connective Tissue Graft Technique for Root Coverage - Langer - 1985 - Journal of Periodontology - Wiley Online Library.
7. Guided Tissue Regeneration Versus Mucogingival Surgery in the Treatment of Human Buccal Gingival Recession - Prato - 1992 - Journal of Periodontology - Wiley Online Library.
8. A Short-Term and Long-Term Comparison of Root Coverage With an Acellular Dermal Matrix and a Subepithelial Graft - Harris - 2004 - Journal of Periodontology - Wiley Online Library .
9. Evaluation of the Safety and Efficacy of Periodontal Applications of a Living Tissue-Engineered Human Fibroblast-Derived Dermal Substitute. II. Comparison to the Subepithelial Connective Tissue Graft: A Randomized Controlled Feasibility Study - Wilson - 2005 - Journal of Periodontology - Wiley Online Library
10. Löe H, Anerud A, Boysen H, Morrison E. Natural history of periodontal disease in man. *Journal of Clinical Periodontology*. 1986;13(5):431–40.
11. Miller J. A Classification of Marginal Tissue Recession. EBSCOhost.
12. Treatment of gingival recession with coronally advanced flap procedures: a systematic review - Cairo - 2008 - Journal of Clinical Periodontology - Wiley Online Library
13. Chambrone L., *et al.* "Root coverage procedures for treating single and multiple recession-type defects: An updated Cochrane systematic review". *Journal of Periodontology* 90.12 (2019): 1399-1422.
14. Clinical Evaluation of a Modified Coronally Advanced Flap Alone or in Combination With a Platelet-Rich Fibrin Membrane for the Treatment of Adjacent Multiple Gingival Recessions: A 6-Month Study - Aroca - 2009 - Journal of Periodontology - Wiley Online Library
15. Periodontal plastic surgery - Zucchelli - 2015 - Periodontology 2000 - Wiley Online Library .

TREATMENT OF A SINGLE TOOTH WITH MILLER'S CLASS I GINGIVAL RECESSON DEFECT BY CORONALLY ADVANCED FLAP (CAF) IN CONJUNCTION WITH CONNECTIVE TISSUE GRAFT (CTG)- A CASE REPORT.

ORIGINALITY REPORT

33%

SIMILARITY INDEX

25%

INTERNET SOURCES

26%

PUBLICATIONS

8%

STUDENT PAPERS

PRIMARY SOURCES

1

www.ncbi.nlm.nih.gov

Internet Source

5%

2

hdl.handle.net

Internet Source

4%

3

pmc.ncbi.nlm.nih.gov

Internet Source

3%

4

B. Yaneva. "Er:Yag Laser Root Modification for Single Root Recession Class III Coverage – Case Report", Acta Medica Bulgarica, 2021

Publication

2%

5

edoc.pub

Internet Source

1%

6

www.oraljournal.com

Internet Source

1%

7

Giulio Rasperini, Raffaele Acunzo, Enrico Limioli. "Decision Making in Gingival Recession Treatment: Scientific Evidence and Clinical Experience", Clinical Advances in Periodontics, 2011

Publication

1%

8

Khadija Amine, Wafa El Kholti, Jamila Kissa. "Periodontal Root Coverage", Springer Science and Business Media LLC, 2019

Publication

1%

9

eaed.org

Internet Source

		1 %
10	pubmed.ncbi.nlm.nih.gov Internet Source	1 %
11	"Poster", Journal Of Clinical Periodontology, 2015. Publication	1 %
12	Submitted to Queen Mary and Westfield College Student Paper	1 %
13	jisponline.com Internet Source	1 %
14	www.jmpr.info Internet Source	1 %
15	clinicaltrials.gov Internet Source	1 %
16	www.nepjol.info Internet Source	1 %
17	Armelia Sari Widyarman, Muhammad Ihsan Rizal, Moehammad Orliando Roeslan, Carolina Damayanti Marpaung. "Quality Improvement in Dental and Medical Knowledge, Research, Skills and Ethics Facing Global Challenges", CRC Press, 2024 Publication	1 %
18	acikbilim.yok.gov.tr Internet Source	1 %
19	www.researchgate.net Internet Source	1 %
20	docplayer.net Internet Source	1 %
21	kb.psu.ac.th Internet Source	1 %

22	www.sciencegate.app Internet Source	1 %
23	G. Zucchelli. "Bilaminar techniques for the treatment of recession-type defects. A comparative clinical study", Journal Of Clinical Periodontology, 10/2003 Publication	1 %
24	Ines Kapferer, Ulrike S. Beier. "Labial piercing complications", international journal of stomatology & occlusion medicine, 2013 Publication	1 %
25	K. J. Nisha, Suhail A. Choudhury, Sanjeela Guru. "Objective evaluation of healing and esthetic outcome of root coverage procedure using chorion membrane: a case series", Cell and Tissue Banking, 2019 Publication	1 %
26	Vignoletti, Fabio, Javier Nunez, and Mariano Sanz. "Soft tissue wound healing at teeth, dental implants and the edentulous ridge when using barrier membranes, growth and differentiation factors and soft tissue substitutes", Journal Of Clinical Periodontology, 2014. Publication	1 %
27	atheneumpub.com Internet Source	1 %
28	ciencia.ucp.pt Internet Source	1 %
29	www.science.gov Internet Source	1 %
30	"Gingival Recession Management", Springer Science and Business Media LLC, 2018 Publication	<1 %

31 "Poster Abstracts", Journal Of Clinical Periodontology, 2012. <1 %

Publication

32 M.P. Chaitra, Shrinidhi Maji Shankar, T.P. Shivakumar, Soumya B. Gururaj, Chethana K. Chidambar, Kala S. Bhushan. "Amniotic membrane versus platelet-rich fibrin in treatment of gingival recession- a randomized control trial", The Saudi Dental Journal, 2023 <1 %

Publication

33 Zucchelli, Giovanni, and Ilham Mounssif. "Periodontal plastic surgery", Periodontology 2000, 2015. <1 %

Publication

34 topics.libra.titech.ac.jp <1 %

Internet Source

Exclude quotes On Exclude matches Off
Exclude bibliography On