

# A challenging case of Hemorrhagic stroke in a patient with fusiform aneurysm with partial thrombosis: A Case Report

*by* Jana Publication & Research

---

**Submission date:** 26-Jul-2025 03:47PM (UTC+0700)

**Submission ID:** 2690323367

**File name:** IJAR-52994.docx (929.64K)

**Word count:** 2536

**Character count:** 14751

## **A challenging case of Hemorrhagic stroke in a patient with fusiform aneurysm with partial thrombosis: A Case Report**

### **Abstract**

#### **Background**

This is a unique case where two hypertension induced complication were seen in same patient but thrombosis in aortic aneurysm has opposite treatment to that of cerebellar hemorrhage which are to be managed simultaneously. Such cases can come in future clinical practice as prevalence of hypertension is on rise.

#### **Case presentation**

In this case the patient was known case of hypertension since 8 years under treatment. Due to hypertension there was bleeding in bilateral cerebellar hemorrhage with seepage into fourth ventricle. This lead to symptoms of headache, imbalance while walking, nausea, vomiting.

Mass effect was noted in form of mild compression over fourth ventricle. In this case CT Thorax showed fusiform dilatation of arch of aorta with non enhancing eccentric mural thrombi within, noted just <sup>3</sup>distal to origin of left subclavian artery extending upto thoracic aorta, but this was an accidental finding not the source of emboli.

The treatment became challenging as treating the Thrombus with anti-coagulants could lead to increase in the risk of bleeding from the hemorrhage and leaving it could lead to increase in

chances of an Cardio embolic Ischemic stroke. Hence a fine line of balance had to be found in the treatment of this two Opposite conditions uniquely found in one patient.

## Conclusion

Conclusion is that this is a case of cerebellar hemorrhage due to hypertension associated with fusiform aortic arch aneurysm with partial thrombosis. The treatment of both of this complications is opposite, hence the treatment needs to be done very carefully. This case report provides insight on management of such cases.

## Keywords:

Hemorrhagic stroke, aortic aneurysm, partial thrombosis.

## <sup>13</sup> Introduction.

Cerebellar hemorrhage accounts for 9% to 10% of all intracranial hemorrhage. Cerebellar hemorrhage due to <sup>1</sup>hypertension most commonly occurs in the middle-aged or older population. The most common cause for cerebellar hemorrhage is hypertensive vasculopathy.<sup>1</sup> The pathophysiology <sup>1</sup>is that patients with long-standing hypertension have degenerative changes in the penetrating small blood vessel walls leading to the subsequent formation of microaneurysms. These micro aneurysm rupture when blood pressure is increased leading to intracerebellar hemorrhage.<sup>4</sup> <sup>5</sup>Embolism is implicated in about 50% of cerebellar infarcts. The source of the embolus is most frequently the heart.

In this case the patient was known case of hypertension since 8 years under treatment. Due to hypertension there was bleeding in bilateral cerebellar hemorrhage with seepage into fourth ventricle. This lead to symptoms of headache, imbalance while walking, nausea, vomiting. CT Scan of Brain dated 31/05/2023, shown intra-parenchymal hemorrhage of size 29 x 32 x 23 mm

involving bilateral cerebellar hemisphere, more on the left than right with surrounding edema. Mass effect noted in form of mild compression over fourth ventricle. In this case CT Thorax showed fusiform dilatation of arch of aorta with non enhancing eccentric mural thrombi within, noted just <sup>3</sup>distal to origin of left subclavian artery extending upto <sup>3</sup>thoracic aorta, but this was an accidental finding not the source of emboli. Hypertension accelerates the process of cystic medial degeneration of aorta. The patient developed aortic arch aneurysm due to long standing hypertension followed by partial thrombosis but it was not the cause of cerebellar hemorrhage. But it has to be monitored for future impending complication by serial assays.

Surveillance of aortic arch aneurysm is planned and explained to the patient that he should come for follow up after 6 months for CT thorax. If the aneurysm is unchanged in size, imaging study will be done on annual basis. <sup>7</sup> This case has two hypertension induced life threatening complication which need follow up. Patient and relatives were explained probable symptoms of complication and need of proper treatment & follow up.

#### <sup>10</sup>**Case Presentation:**

A 48 year old male presented to emergency department of Dhiraj hospital, Gujarat, India in May 2023 with history of sudden onset headache, palpitation, imbalance while walking, nausea, vomiting on 31/05/2023 at 5 pm. Patient was known case of Hypertension since 8 years and was on antihypertensive <sup>18</sup>Tab. Amlodipine 5 mg plus atenolol 50 mg once in morning. <sup>8</sup>On physical examination, patient was conscious, oriented to time, place and person. Temperature normal, <sup>16</sup>pulse rate 76 per minute, <sup>16</sup>respiratory rate 18 per minute, Blood pressure 160/110 mmHg, <sup>9</sup>Spo2 99% on room air. There was no pallor, icterus, cyanosis, clubbing, edema, and lymphadenopathy. On systemic examination of CNS (E4 V5 M6), pupils were bilaterally reacting to light, with spasticity in both lower limbs. Cardiovascular, respiratory, abdominal system were normal on examination.

## Diagnostic assessment / Investigation

On admission, Haemogram revealed haemoglobin 14.6 g/dl, total leukocyte counts 15000 /dl, thrombocytes 2,30,000 cells/mm<sup>3</sup>. Non-specific inflammatory biomarker like C-reactive protein was increased 114.67 mg/L. Renal function test results showed creatinine 1.9 mg%. Liver enzymes SGPT 25 U/l. Urine test results were normal. HBV, HIV were negative<sup>[table 1]</sup>. The lipid profile of the patient was also checked<sup>[table 2]</sup>. CT Scan of Brain<sup>[figure 1]</sup> dated 31/05/2023, shown Intra-parenchymal Hemorrhage of size 29 x 32 x 23 mm involving bilateral cerebellar hemisphere, left > Right with surrounding edema. Mass effect noted in form of mild compression over fourth ventricle. Old lacunar infarct/ gliosis in left gangliocapsular region. 2D Echo dated 01/06/2023, revealed severe concentric left ventricular Hypertrophy, there was No RWMA<sup>17</sup> (Regional Wall Motion Abnormality). Left Ventricular Ejection Fraction (LVEF) was 65%, All Valves were normal, Inferior Vena Cava (IVC) was Collapsible. Color Doppler was normal.

On CT Thorax (Plain & Contrast)<sup>[figure 2]</sup> dated 02/06/2023, there was fusiform dilatation of arch of aorta with non enhancing eccentric mural thrombi within, noted just<sup>3</sup> distal to origin of left subclavian artery extending upto thoracic aorta. Subpleural reticular bands in bilateral lower lobes were seen and few fibrotic strands in bilateral apical zones were seen. VDRL Test dated 04/06/2023 was negative, sickling test was negative.

## Differential Diagnosis

The differential diagnosis for sudden onset headache, palpitation, imbalance while walking, nausea, vomiting includes central causes such as<sup>1</sup> Acute demyelinating disorder such as multiple sclerosis (MS) or encephalitis, Alcohol use disorder, Cerebellar hemorrhage, Cerebellar infarction, Cerebellar neoplasm, Cerebellitis, Illicit drug use, Medication toxicity (phenytoin or

carbamazepine) and Peripheral causes, Benign paroxysmal positional vertigo (BPPV), Labyrinthitis, Meniere disease, Vestibular neuritis.

Differential diagnosis were ruled out as there was no history of coagulopathy, head injury, no known history of an intracranial aneurysm, or arteriovenous malformation (AVM), no history of malignancy, and no history of use of sympathomimetic drugs (cocaine and amphetamines), no history of alcohol addiction, no history of phenytoin or carbamazepine use.

### Therapeutic Intervention/ Treatment

Treatment started immediately after confirming the diagnosis. Inj. Mannitol was given intravenously every eight hourly, Inj. Levira 500mg was given intravenously every 12 hourly, Tab. Rosuvas 20 mg was given 1 at bed time and Tab. Temisartan - Amlodipine (40/5) was given 1 twice in a day. This therapy led to significant clinical improvement and gradual decline in symptoms.

Blood pressure was maintained below 160/90 mm Hg or a mean arterial pressure (MAP) was maintained below 110 mm Hg as per the 2010 American Heart Association guidelines on the management of blood pressure in intracerebral hemorrhage.<sup>8</sup>

Body temperature was maintained within the normal range, and pharmacotherapy or cooling measures were planned if the patient does develop an elevated body temperature, to maintain a core body temperature of lower than 37.5 C as the fever has been shown to worsen outcomes in the injured brain.<sup>9</sup>

Blood glucose was maintained in a range of 100 to 180 mg/dL. There are studies showing correlations between hyperglycemia and poorer outcomes in patients with cerebellar hemorrhage.<sup>10,11</sup>

Fluid and electrolyte balance was maintained with isotonic fluids with appropriate correction of serum electrolytes such as sodium, potassium, and magnesium. Serum potassium level was maintained above 4.0 mmol/L and magnesium above 2.0 mg/dL so as prevent cardiac

arrhythmia.

Constant watch on possible complications (hydrocephalus, brainstem compression, and/or cerebellar herniation) was kept and neurosurgical opinion was taken and plan for surgical evacuation was ready if signs and symptoms of neurological deterioration, brainstem compression, obstructive hydrocephalus appear and cerebellar ICH volume >15 mL as per guidelines.<sup>12</sup>

Table 1: Blood Investigation during hospital stay

Investigation	On Admission	During Hospital Stay	Discharge
Hemoglobin (gm%)	14.6 gm%	13.7 gm%	12.3 gm%
Total Leukocyte count	15000 cells/mm <sup>3</sup>	10100 cells/mm <sup>3</sup>	8200 cells/mm <sup>3</sup>
Platelet count	2,30,000 cells/mm <sup>3</sup>	2,58,000 cells/mm <sup>3</sup>	2,70,000 cells/mm <sup>3</sup>
Creatinine (mg%)	1.9 mg%	1.5 mg%	1.2 mg%
SGPT	25	40	
Serum Electrolyte	131/4.5 mmol/L	135/3.8 mmol/L	140/4 mmol/L
Na+/ K +			
CRP mg/L	114.67 mg/L	85.68 mg/L	63.77 mg/L

Table 2: Lipid Profile

Lipid Profile ( Dated 01/06/2023)	Patients values
Cholesterol	135 mg%
Triglyceride	73 mg%
HDL ( High Density Lipoprotein)	28 mg%
LDL (Low Density Lipoprotein)	92.4 mg%

VLDL (Very Low Density Lipoprotein)	14.6 mg%
-------------------------------------	----------

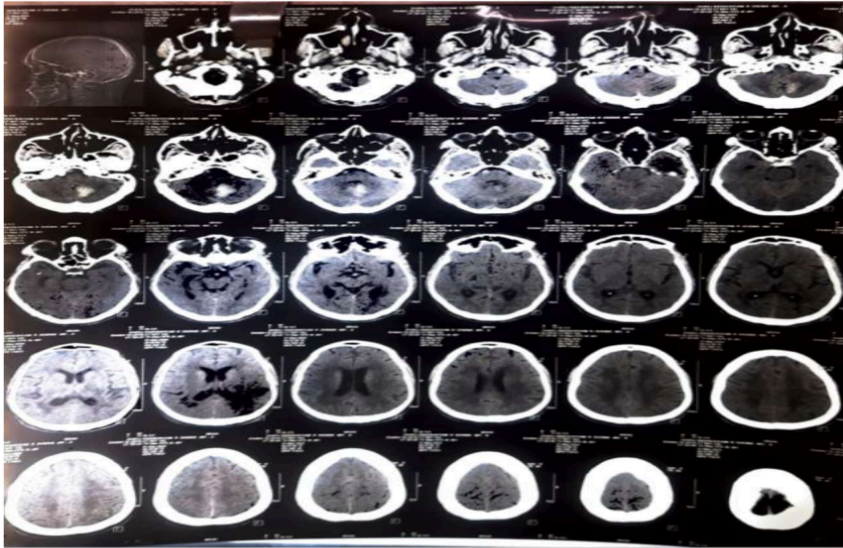
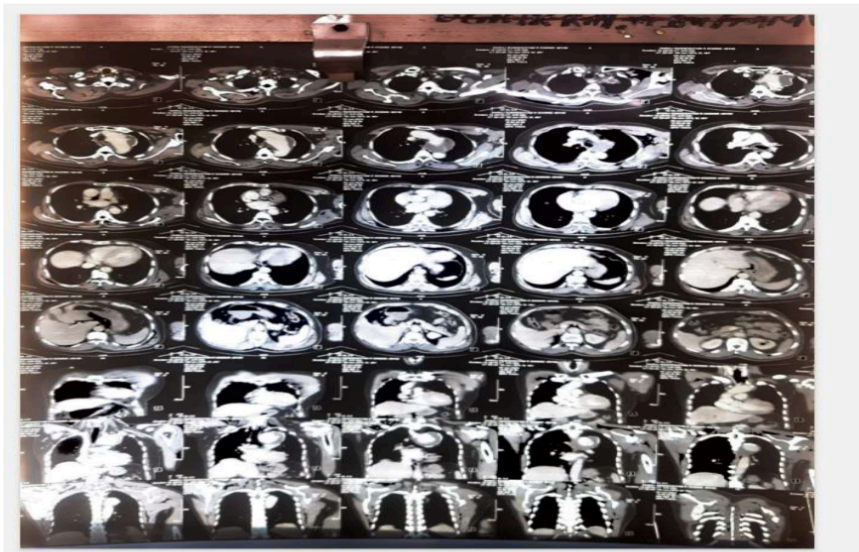

Figure 1: CT Scan Head (Note Hyper density in bilateral cerebellar hemorrhage)





**Figure 2: CT Scan Thorax showing fusiform dilatation of arch of aorta**

## Discussion

In a case report by Tatsuoka Y et al, in which a <sup>4</sup> 42-year-old woman with primary Antiphospholipid antibody syndrome (APS) and APS nephropathy on warfarin and aspirin therapy presented with coma due to cerebellar hemorrhage. Patient developed dissection of the aortic wall on second day of admission due to hypertension in previously weakened aortic wall by APS and vasa vasorum thrombosis.<sup>16</sup>

Management of the mass effect due to cerebellar hemorrhage can be done conservatively or surgically by either (1) <sup>1</sup> hyperosmolar agents or (2) decompressive surgery respectively.

As the hemorrhages was <sup>1</sup> less than 3 cm in diameter without evidence of brainstem compression or hydrocephalus, he was treated with close observation in an intensive care setting without surgery.<sup>13</sup> Hyperosmolar agent increase serum osmolality, create osmotic gradient which

moves water into the circulation with resultant reactive vasoconstriction and thereby decrease<sup>1</sup> the space-occupying effects of hemorrhage and edema. As per<sup>7</sup> Videen TO et al, Mannitol bolus preferentially shrinks non-infarcted brain in patients with ischemic stroke, with overall reduction in intracranial pressure.<sup>14</sup> As per Diringer MN et al, there are similar results with hypertonic saline<sup>19</sup> or mannitol in the treatment of intracranial hemorrhage. Mannitol<sup>1</sup> acts as a diuretic and is usually administered as a 1 to 2 g/kg bolus (20% concentration) with additional doses of 0.5 g/kg every 4 to 6 hours.<sup>15</sup> According to Lee JH et al, when hemorrhages is<sup>1</sup> less than 3 cm in diameter without evidence of brainstem compression or hydrocephalus can be treated with close observation in an intensive care setting without surgery, also stereotactic burr-hole aspiration can be performed in patients with smaller hemorrhages.<sup>13</sup>

Lynch DR et al,<sup>2</sup> reviewed the incidence of neurologic complications in 200 consecutive patients with aortic aneurysm or aortic dissection over a 2-year period, neurologic impairment was seen in 18.5% of these 200 patients.<sup>15</sup> Neurologic complications are more common in patients with thoracic or thoracoabdominal aneurysms<sup>2</sup> than those with abdominal aneurysms. The most common complications found were focal CNS ischemia, altered consciousness and peripheral nerve complications.<sup>17</sup>

## Conclusion

Conclusion is that this is a case of cerebellar hemorrhage due to hypertension associated with fusiform aortic arch aneurysm with partial thrombosis. The cause of cerebellar hemorrhage was hypertension, so associated eccentric thrombosis in aortic arch aneurysm was not managed by thrombolytic drugs which would have further increased the risk of hemorrhage. The diagnosis is established by CT scan and treated as medical emergency conservatively. The management was aimed at managing cerebellar hemorrhage and its mass effects. The aortic arch aneurysm will be kept under surveillance by serial assay using CT Thorax. This is a unique case where two hypertension induced complication were seen in same patient but thrombosis in aortic aneurysm

has opposite treatment to that of cerebellar hemorrhage which are to be managed simultaneously.

Such cases can be seen in future clinical practice as prevalence of hypertension is on rise.

**Consent for <sup>11</sup>participation**

“Not applicable”

**Consent for publication**

“Not applicable”

**Availability of data and materials**

“Not applicable”

**Competing interests**

"The authors declare that they have no competing interests"

**Funding/support**

“This study received no specific grant from any funding agency in the public, commercial, or not-for-profit sectors.”

**<sup>20</sup>Conflicts of interest**

“All authors have disclosed no conflicts of interest.”

**Ethical approval and Consent to participate**

“Not Applicable”

**Acknowledgements**

“Not Applicable”

## References

- 1) Fischer MA, M Das J. Cerebellar Hematoma. 2023 Apr 3. In: StatPearls [Internet]. Treasure Island (FL): StatPearls Publishing; 2023 Jan-. PMID: 31082120.
- 2) Sybert GW, Alvord EC Jr: Cerebellar infarction: A clinicopathological study. Arch Neurol (Chicago) 32: 357-363, 1975
- 3) Heros RC: Cerebellar infarction resulting from traumatic occlusion of a vertebral artery: Case report. J Neurosurg 51: 111-113, 1979
- 4) Garcia JH, Ho KL. Pathology of hypertensive arteriopathy. Neurosurg Clin N Am. 1992 Jul;3(3):497-507.
- 5) Guo D, Hasham S, Kuang S-Q, Vaughan CJ, Boerwinkle E, Chen H, Abuelo D, Dietz HC, Basson CT, Shete SS, Milewicz DM. Familial thoracic aortic aneurysms and dissections. **Circulation**. 2001; 103: 2461–2468.
- 6) Davies RR, Goldstein LJ, Coady MA, Tittle SL, Rizzo JA, Kopf GS, Elefteriades JA. Yearly rupture or dissection rates for thoracic aortic aneurysms: simple prediction based on size. **Ann**

**Thorac Surg.** 2002; 73: 17–28.

7) Cayne NS, Veith FJ, Lipsitz EC, Ohki T, Mehta M, Gargiulo N, Suggs WD, Rozenblit A, Ricci Z, Timaran CH. Variability of maximal aortic aneurysm diameter measurements on CT scan: significance and methods to minimize. **J Vasc Surg.** 2004; 39: 811–815.

8) Morgenstern LB, Hemphill JC, Anderson C, Becker K, Broderick JP, Connolly ES, Greenberg SM, Huang JN, MacDonald RL, Messé SR, Mitchell PH, Selim M, Tamargo RJ., American Heart Association Stroke Council and Council on Cardiovascular Nursing. Guidelines for the management of spontaneous intracerebral hemorrhage: a guideline for healthcare professionals from the American Heart Association/American Stroke Association. *Stroke.* 2010 Sep;41(9):2108-29.

9) Schwarz S, Häfner K, Aschoff A, Schwab S. Incidence and prognostic significance of fever following intracerebral hemorrhage. *Neurology.* 2000 Jan 25;54(2):354-61.

10) Wu YT, Li TY, Lu SC, Chen LC, Chu HY, Chiang SL, Chang ST. Hyperglycemia as a predictor of poor outcome at discharge in patients with acute spontaneous cerebellar hemorrhage. *Cerebellum.* 2012 Jun;11(2):543-8.

11) Kimura K, Iguchi Y, Inoue T, Shibasaki K, Matsumoto N, Kobayashi K, Yamashita S. Hyperglycemia independently increases the risk of early death in acute spontaneous intracerebral hemorrhage. *J Neurol Sci.* 2007 Apr 15;255(1-2):90-4.

12) Greenberg S, Ziai W, Cordonnier C et al. 2022 Guideline for the Management of Patients With Spontaneous Intracerebral Hemorrhage: A Guideline From the American Heart Association / American Stroke Association. *Stroke.* 2022;53(7). doi:10.1161/str.0000000000000407

13) Lee JH, Kim DW, Kang SD. Stereotactic burr hole aspiration surgery for spontaneous hypertensive cerebellar hemorrhage. *J Cerebrovasc Endovasc Neurosurg.* 2012 Sep;14(3):170-4.

14) Videen TO, Zazulia AR, Manno EM, Derdeyn CP, Adams RE, Diringner MN, Powers WJ. Mannitol bolus preferentially shrinks non-infarcted brain in patients with ischemic stroke. *Neurology.* 2001 Dec 11;57(11):2120-2.

15) Diringer MN, Scalfani MT, Zazulia AR, Videen TO, Dhar R. Cerebral hemodynamic and metabolic effects of equi-osmolar doses mannitol and 23.4% saline in patients with edema following large ischemic stroke. *Neurocrit Care*. 2011 Feb;14(1):11-7.

16) Tatsuoka Y, Mano Y, Ishikawa S, Shinozaki S. Primary Antiphospholipid Antibody Syndrome Complicated with Cerebellar Hemorrhage and Aortic Dissection: A Case Report. *Am J Case Rep*. 2019 Dec 11;20:1852-1856. doi: 10.12659/AJCR.919649. PMID: 31822651; PMCID: PMC6916662.

17) Lynch DR, Dawson TM, Raps EC, Galetta SL. Risk factors for the neurologic complications associated with aortic aneurysms. *Arch Neurol*. 1992 Mar;49(3):284-8. doi: 10.1001/archneur.1992.00530270098025. PMID: 1311168.

# A challenging case of Hemorrhagic stroke in a patient with fusiform aneurysm with partial thrombosis: A Case Report

## ORIGINALITY REPORT

28%

SIMILARITY INDEX

27%

INTERNET SOURCES

13%

PUBLICATIONS

4%

STUDENT PAPERS

## PRIMARY SOURCES

1	<a href="http://www.ncbi.nlm.nih.gov">www.ncbi.nlm.nih.gov</a> Internet Source	15%
2	<a href="http://pubmed.ncbi.nlm.nih.gov">pubmed.ncbi.nlm.nih.gov</a> Internet Source	2%
3	"Cardiovascular Interventions in Clinical Practice", Wiley, 2010 Publication	1%
4	<a href="http://discovery.researcher.life">discovery.researcher.life</a> Internet Source	1%
5	<a href="http://docshare.tips">docshare.tips</a> Internet Source	1%
6	<a href="http://radiopaedia.org">radiopaedia.org</a> Internet Source	1%
7	Michael N. Diringier, Michael T. Scalfani, Allyson R. Zazulia, Tom O. Videen, Raj Dhar. "Cerebral Hemodynamic and Metabolic Effects of Equi-Osmolar Doses Mannitol and 23.4% Saline in Patients with Edema Following Large Ischemic Stroke", Neurocritical Care, 2010 Publication	1%
8	<a href="http://journalarrb.com">journalarrb.com</a> Internet Source	1%
9	<a href="http://www.iosrjournals.org">www.iosrjournals.org</a> Internet Source	1%

10	Internet Source	1 %
11	<a href="http://www.researchsquare.com">www.researchsquare.com</a> Internet Source	1 %
12	<a href="http://www.hkmj.org">www.hkmj.org</a> Internet Source	1 %
13	<a href="http://d.docksci.com">d.docksci.com</a> Internet Source	<1 %
14	<a href="http://www.rochester.edu">www.rochester.edu</a> Internet Source	<1 %
15	Lynch, D. R., T. M. Dawson, E. C. Raps, and S. L. Galetta. "Risk Factors for the Neurologic Complications Associated With Aortic Aneurysms", Archives of Neurology, 1992. Publication	<1 %
16	<a href="http://www.science.gov">www.science.gov</a> Internet Source	<1 %
17	<a href="http://www.scirp.org">www.scirp.org</a> Internet Source	<1 %
18	<a href="http://www.tenderdetail.com">www.tenderdetail.com</a> Internet Source	<1 %
19	"Neurocritical Care for the Advanced Practice Clinician", Springer Science and Business Media LLC, 2018 Publication	<1 %
20	<a href="http://www.springermedizin.de">www.springermedizin.de</a> Internet Source	<1 %

Exclude quotes On

Exclude matches Off

Exclude bibliography On