

Title: Pneumothorax: How to optimize favorable outcome

Key words: Broncho-pleural fistula (BPF), Flail chest, Intercostal tube drainage (ICD), Pleurodesis, primary & Secondary spontaneous pneumothorax (PSP & SSP), Open thoracotomy decortication (OTD) and video-assisted thoracoscopic decortication (VATD).

Abstract:

Introduction: The Pneumothorax (PTX) is the presence or accumulation of air in the pleural space and that leads to variable clinical presentation and to life-threatening hypoxia and even cardiogenic shock. A quick diagnosis and management is the key to success with precise and minimally invasive procedures. However recurrent PTX and partial or unexpanded lung remained a challenge.

Results: A male predominance (87%) with age above 40 years (80%) and secondary spontaneous PTX (SSP) > primary spontaneous PTX (PSP) > traumatic (i.e. 64%, 24% and 12% respectively) were observed among the total 55 cases. TB (36%) followed by COPD (24%) remained the highest underlying cause of SSP in the Indian context. A complete recovery in 69% with partial resolution in 29% and death of one case (2%) was observed. Management with ICD in 82% of case and Pleurodesis was done in 69% cases after full expansion of lung. The 9% of cases were referred to a Cardio thoracic vascular surgeon (CTVS) for open thoracic decortication.

Discussion: A sudden onset of shortness of breath and chest pain were the most common presenting symptom. A quick clinical diagnosis and management, even in absence of CXR, is crucial to prevent mortality, specially in context of cases of accidental chest injury and or tension PTX. A timely recognition of common complications like hemo- or pyo-pneumothorax, BP fistula, persistent air leak, mediastinal emphysema, pleural peel, fibrothorax and the presence of underlying lung diseases with associated comorbidities affect the favorable prognosis and outcomes.

Conclusion: Pneumothorax is one of the frequently encountered emergency of respiration department. A quick recognition of problem with the placement of intercostal drainage (ICD) system with an under water seal is life saving. The pneumothorax needs to be included as a part of CME on respiratory emergencies

30

31

32

33

34

35

36

37

38 **Introduction:** Pneumothorax (PTX) occurs when air enters the pleural space due to a
39 breach in the integrity of the visceral or parietal pleural membranes. Normally, the
40 negative intra pleural pressures prevent air from entering this space during the
41 respiratory cycle ⁽¹⁾. The PTX is one of the life threatening respiratory emergence and
42 the clinical presentation varies depending on the degree of lung collapse on the affected
43 side, ranging from mild chest discomfort to severe dyspnea ^(2,3). Clinically it can easily
44 be diagnosed however imaging modalities are required to explore the underlying status
45 of lung ⁽⁴⁾. The lung air leaks from the injured visceral pleura and continue to collect in
46 the pleural space during each inspiratory phase of respiration and that leads to collapse
47 of ipsilateral lung. Somehow a tension PTX with progressive collection of air may
48 develop due to a check wall mechanism and a further accumulation of air pushes the
49 mediastinum that compress the contralateral lung and the increased intra thoracic
50 pressure leads to life threatening haemodynamic instability ⁽⁵⁾. PTX may also be
51 associate with a collection of liquid material e.g. hydro/ pyo/ or haemo pneumothorax.
52 The PTX can be classified as primary or secondary spontaneous pneumothorax
53 (PSP/SSP) and traumatic origin ^(6,7). The incidence of nontraumatic PTX varies around
54 7-12/ Lakh of population, however the PSP is more frequently observed in tall, thin
55 male while the secondary PTX is more commonly associated with COPD (in near 70%)
56 however pulmonary TB may also considerably contribute in high prevalence country
57 like India. Subcutaneous/surgical emphysema may accompany PTX due to envisage of
58 air in loose subcutaneous tissue and or as a more serious form of mediastinal
59 emphysema. The BTS guide line suggested that a size of PTX should be assessed as a
60 visible air between chest wall and lung edge on a chest radiograph PA view to
61 categorize it into a small PTX with 2 cm rim and larger one with >2 cm ⁽⁶⁾. A small PTX
62 may resolve spontaneously ^(3,8), whilst most of the cases may required interventions
63 like aspiration or intercostal tube drainage with under water seal (ICD) till the injured
64 visceral pleura healed ^(2,9,10). A continued air leak may persist and is referred to as
65 bronchopleural fistula (BPF). The amount of air leak may be proportionate to the size of
66 fistula but it becomes difficult to locate and even to close it. A task to identify and

understand the underneath problem the thoracoscopy/ Pleuroscopy, VATS, pleurodesis, decortication of pleura and infection control are some of the options and challenges needed to be precisely used to optimize the out come. Thus this study is undertaken to understand the different aspects of pneumothorax at a rural based medical college.

Result: The patient profile, clinical data with interpretation, and possible inference is summarized in a tabulation form.

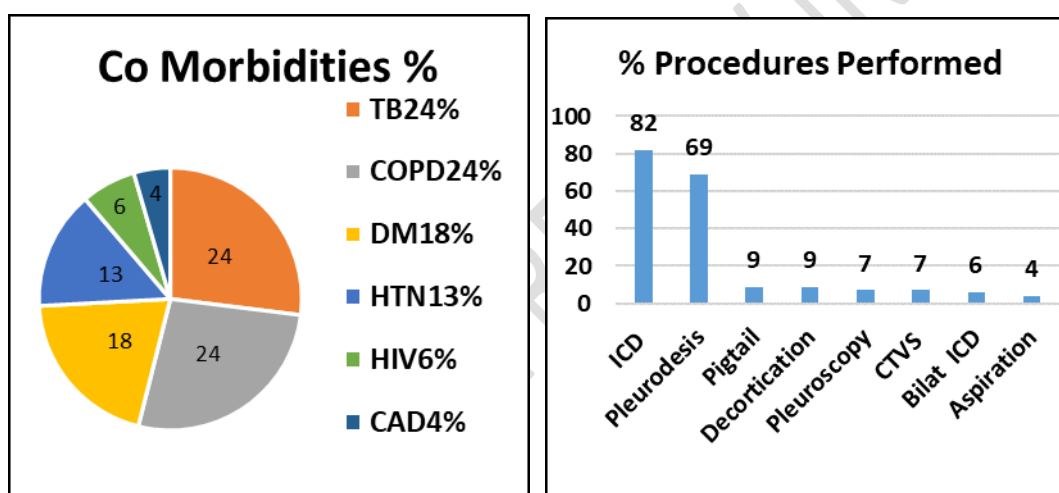
SN	Profile	DATA	Interpretation/ Inference
1	M : F	87: 13	Male predominance of 6-7 Time
2	AGE distribution < 40 Yr 40- 60 > 60	No. / percent 11 (20%) 31 (56%) 13 (24%)	Maximum cases in 40-60 Yrs (elder age) are more vulnerable for COPD, TB, CA, and are in productive age with stress, strain and addictive habits (>64%)
3	Rural : Urban	71% : 29 %	Not Specific
4	Addiction Smoker Alcoholic Tobacco Chewing	No. / percent 35 (64%) 21 (38%) 19 (35%)	Smoking in 64% is a known cause for the COPD & Ca lung however the low immunity in alcoholic may make them vulnerable to Tuberculosis.
5	Symptom Breathlessness Chest pain Cough Fever Expectoration Vomiting Swelling	No. /Percent 50 (91%) 44 (80%) 14 (26%) 08 (15%) 13 (24%) 04 (07%) 02 (04%)	Sudden onset SOB is most usual presentation and observed in 91% of cases and these cases use to be considered for differential diagnosis of PTX. Chest pain to be excluded with cardiac, neuromuscular or GIT etiology. Other symptoms could be due to sudden shock, Hypoxia, and circulatory failure.

6	Co morbidities	No. / Percent	In Indian context Pulmonary Tuberculosis is the most common cause of PTX, however COPD with rupture of pleural bleb specially those with smoking abuse remained the commonest cause of PTX. Associated co-morbidities could further worsen the general condition of individuals.
	TB	20 (36 %)	
	COPD	13 (24%)	
	DM	10 (18%)	
	HTN	7 (13%)	
	HIV	3 (06%)	
	CAD	2 (04%)	
7	General Examination	No. / Percent	Raised JVP and Pedal edema are serious effect of PTX with high intra thoracic pressure, Rt sided cardiac failure and low cardiac output, with low BP and SpO ₂ . The clubbing is a sign of long standing hypoxia e.g. ILD or suppurative lung disease like underlying lung abscess, bronchiectasis or empyema thoracic etc.
	Pallor	08 (15%)	
	JVP raised	08 (15%)	
	Pedal edema	07 (13%)	
	Tachypnea	06 (11%)	
	Clubbing	06 (11%)	
	Icterus	04 (07%)	
8	SpO₂ and or ABG	No. / Percent	ABG were performed at admission.
	Normal	03 (05%)	Hypoxia and tachypnea with CO ₂ washout in 71%
	Type 1 RF	39 (71%)	Type 2 Respiratory Failure (RF) in 24% due to low alveolar ventilation/ fatigue or exhausted patient.
	Type 2 RF	13 (24%)	
9	Site of PTx	No. / Percent	Right lung is bigger than left and therefore nearly double the cases of right sided PTX reported means more loss; however the degree of collapse lung is more valuable, while bilateral PTX is more serious condition.
	RIGHT	34 (62%)	
	LEFT	18 (33%)	
	Bilateral	03 (05%)	
10	Type of PTX	No. / Percent	The PSP is usually easiest to manage but the SSP is a complication of underlying diseases hence dual management has to be done, while the extent of trauma is indefinite. The pleurodesis should also be plan to prevent recurrence.
	PSP	13 (24%)	
	SSP	35 (64%)	
	Traumatic PTX	04 (07%)	
	Iatrogenic PTX	03 (05%)	

11	ABG (on admission) Normal Type 1 RF Type 2 RF	No. / Percent 03 (05%) 39 (71%) 13 (24%)	Interpretation of ABG at the time of admission showed hypoxemia with low or normal PCO ₂ e.g. type-1 Respiratory failure (RF) due to tachypnea in 71% and more serious type-2 RF in 24% cases.
12	Procedure Aspiration Pigtail catheter Drain ICD Bilateral ICD Thoracoscopy CTVS (Post Op) Pleurodesis Decortication	No. / Percent 02 (04%) 05 (09%) 45 (82%) 03 (06%) 04 (07%) 04 (07%) 38 (69%) 05 (09%)	Three cases (5%) were managed conservatively and noninvasively with high flow intermittent oxygen. Rest of the cases managed considering the general condition, routine investigation, clinical, radiologic and underlying disease and a least invasive intervention was preferred.
13	Complication Surgical & mediastinal emphysema Secondary Infection Non expansion Persistent air leak Fibrothorax	No. / Percent 05 (09%) 	Infection due to underlying disease or from the connectivity to atmospheric air, lung re-expansion edema, BP fistula, Surgical and Or mediastinal emphysema, Persistent air leak, unexpanded lung, fibrothorax, trapped lung, pleural peel formation etc are some of the examples apart from a life-threatening Tension PTX and respiratory failure
14	Out comes of PTX Complete Resolution Partial Resolution Died	No. / Percent 38 (69%) 16 (29%) 01 (02%)	The role of incentive spirometry, physiotherapy, Yogic exercise like Pranayama should be given due consideration. Surgical intervention includes e.g. Pleurectomy, OTD, VATD etc

15	Classification	No. / Percent	1. A total of 13 (24%) cases of PSP
	1. PSP	13 (24%)	
	2. SSP	35 (64%)	2. A total of 35 (64%) cases of SSP: PTB & COPD
	2.1 PTB	13 (24%)	were most frequent
	2.2 COPD	13 (24%)	
	2.3 Pneumonia	03 (05%)	3. Acquired PTX 07 cases (12%)
	2.4 Bronchiectasis	03 (05%)	1 case of Flail chest
	2.5 Ca lung	03 (05%)	3 Rib fracture/ Haemothorax/ Lung contusion
	3. Traumatic PTX	07 (12%)	3 Central line, shoulder block, Pyothorax

74



75

Discussion: The present study observed that the Pneumothorex (PTX) was more prevailed above the 40 year of age with male predominance and that could be due to underlying ailments like TB in 24%, COPD 24%, and addictive habits of smoking found in >64% with stress and strain of a productive life. A similar data were also reported by other authors ^(2,9,10). The PSP (24%) remained less common than secondary spontaneous PTX (64%) and the traumatic origin of 12% were observed in our study which were matching as 26%, 64%, and 10% respectively with Josh P et al ⁽²⁾. The present study revealed that the breathlessness remained the most common symptom (90.9%) followed by chest pain (80.0%) whilst rest of the symptoms were nonspecific may relevant to other underlying and co existing ailments/ co-morbidities. A sudden increase of pre existing SOB, tearing chest pain and typical pleuritic pain that may referred to shoulder or arm are other usual presentations. A stab wound or chest injury with underlying fractured rib, contusion and inflammation with internal bleeding are not uncommon in road traffic accident. We came across 4 cases of chest trauma and each one was managed differently; one had a single site only with one rib fractured with

a minimal < 2cm pneumothorax which was managed conservatively. Another two cases had haemo-pneumothorax with multiple rib fracture and one of them also had lung contusion; and both were managed with ICD, while the fourth one had a flail chest was managed with ICD and fixation of the hemithorax was done by the orthopedic surgeon. Carl A Beyer et al stated that a PTX of more than 35mm and or haemothorax of >300 ml should be managed with insertion of ICD in combination with warm saline irrigation of pleural space to clear retained blood and an intrapleural instillation of thrombolytics ⁽¹¹⁾.

Bilateral PTx: Our study reported 3 cases but not a buffalo chest, is common proceeding a post thoracic surgery, lung cryo biopsy and post esophagotomy ⁽⁷⁾. These cases in the present study were successfully managed with ICD. All the cases of pneumothorax may not require the ICD with under water seal, however we preferred and used 24-26 gauge fr ICD in 32 (58%) cases while a less invasive procedures like needle aspiration of air ⁽⁸⁾ with three way adopter attached to a 50cc syringe was used in 4% and a pig tail catheter was also used in 9% of cases with added advantage of repeated saline irrigation and intra pleural thrombolytic therapy with successful resolution of PTX. The cases having a bigger air leak, or e.g. pyo or haemothorax may require 32-34 fr a bigger bore catheter to minimize the plugging ⁽⁷⁾.

The tension PTX; is a medical emergency that should be diagnosed quickly with a characteristic history of severe sudden onset of progressive dyspnea. A clinical examination could revealed fullness of chest, decreased movement, hyperresonant chest, and absent breath sound on the affected side and tracheal shift to opposite side with poor GC or vitals. In such a life-threatening situation a plastic venflon can be placed in the 2nd intercostal space at mid clavicular line even without waiting for chest x-ray this may save the life. There were two such cases during the study period.

A persistent air leak in cases of PTX is due to non healing of alveolar-pleural or the bronchopleural fistula (BOF) and usually remained for a longer period with infection or new growth and continued drain formation/ collection. There could be various presentation of partial or incomplete expansion of lung e.g. empyema (Infection), BP Fistula (persistence air leak) and fibrothorax (with trapped lung) with or without BPF. The surgical repair is gold standard but it is not always feasible to close and even to precisely locate the site of leak. Karen C et al ⁽¹²⁾ mentioned variable out comes with using fibrin sealants and endoscopically placed “one-way” valves and metal coils etc and pleurodesis, Our study showed partial lung expansion in 29 % and full lung expansion was achieved in only 69 % of cases with one unfortunate mortality 2%. cases. There had referred 5 (9%) cases to Thoracovascular surgeon to consider decortication. However a comparative data from Joshi P et. al., Hassan et al. and Gupta et. al. ^(2, 9, 10) had reported a better success rate of > 90%. There were 5 cases of recurrent PTX and among them 2 developed on the contralateral hemithorax (due underlying COPD) and all were successfully managed with ICD followed by pleurodesis. The chemical

pleurodesis with doxycycline is included in our protocol as a routine for all the cases of PTX after achieving full lung expansion to prevent recurrence. Prabhat B et al mentioned an encouraging result of open thoracotomy and decortication (OTD) specially in cases of chronic empyema with fibrothorax (13) and with the similar procedure 5 (9%) cases were managed by the Thoracic cardiovascular surgeon. Pan H et. al. meta had analysed six studies to compare **video-assisted thoracoscopic decortication** (VATD) with OTP and concluded that the VATD is better as it is less invasive, shorter hospital stay and reduced ICD and air leak duration ⁽¹⁴⁾. Although medical thoracoscopy is becoming popular among respiratory intensivists to perform various tasks yet it requires availability and skill development. The loculation/septations in the pleural space were removed with a favorable result in 4 (7%) cases with semi rigid Video thoracoscope.

Conclusion: The under graduates should be well aware of the management of Pneumothorax as a most common respiratory emergency. The management of underlying disease, unexpanded or trapped lung are the challenges that require timely and meticulous selection of diagnostic and therapeutic modalities which is a key to success.

References:

1. Gilday C, Odunayo A, Hespel AM. Spontaneous Pneumothorax: Pathophysiology, Clinical Presentation and Diagnosis. *Top Companion Anim Med.* 2021 Nov;45:100563. doi: 10.1016/j.tcam.2021.100563. Epub 2021 Jul 22. PMID: 34303864.
2. Joshi, Priyanka¹; Sahu, Gaurav²; Pawar, Kamendra Singh³; Gupta, Vikas⁴. Aetiology, clinical profile and management outcome of pneumothorax patients: A prospective study from Central India. *Journal of Family Medicine and Primary Care* 12(9):p 2134-2139, September 2023. | DOI: 10.4103/jfmmpc.jfmmpc_341_23
3. Dhua A, Chaudhuri A, Kundu S, Tapadar S, Bhuniya S, Ghosh B, et al. Assessment of spontaneous pneumothorax in adults in a tertiary care hospital. *Lung India.* 2015;32(2):132–6.
4. Kaya Ş, Çevik AA, Acar N, Döner E, Sivriköz C, Özkan R. A study on the evaluation of pneumothorax by imaging methods in patients presenting to the emergency department for blunt thoracic trauma. *Ulus Travma Acil Cerrahi Derg.* 2015 Sep;21(5):366-72. doi: 10.5505/tjtes.2015.91650. PMID: 26388273.
5. Roberts DJ, Leigh-Smith S, Faris PD, Blackmore C, Ball CG, Robertson HL, Dixon E, James MT, Kirkpatrick AW, Kortbeek JB, Stelfox HT. Clinical

Presentation of Patients With Tension Pneumothorax: A Systematic Review. Ann Surg. 2015 Jun;261(6):1068-78. doi: 10.1097/SLA.0000000000001073. PMID: 25563887.,

6. Currie GP, Alluri R, Christie GL, Legge JS. Pneumothorax: an update. Postgrad Med J. 2007 Jul;83(981):461-5. doi: 10.1136/pgmj.2007.056978. Erratum in: Postgrad Med J. 2007 Nov;83(985):722. PMID: 17621614; PMCID: PMC2600088. <https://pmc.ncbi.nlm.nih.gov/articles/PMC2600088/>

7. Abdulghani Sankari; Nagendra Gupta; Acute Pneumothorax Evaluation and Treatment. <https://www.ncbi.nlm.nih.gov/books/NBK538316/>

8. Chew R, Gerhardy B, Simpson G. Conservative versus invasive treatment of primary spontaneous pneumothorax: a retrospective cohort study. Acute Med Surg. 2014 May 19;1(4):195-199. doi: 10.1002/ams2.33. PMID: 29930848; PMCID: PMC5997214.

9. Hassan DMI, Ghosh DS, Agarwalla DA, Mandal DA. Clinico-radiological profile and outcome of patients undergoing intercostal tube drainage in a tertiary care hospital in West Bengal, India. Int J Med Res Rev. 2019;7(6):504–10.

10. Gupta D, Mishra S, Faruqi S AA. Aetiology and clinical profile of spontaneous pneumothorax in adults. Indian J Chest Dis Allied Sci. 2006;48:261-4.

11. C.A. Beyer, A.C. Ruf and A.B. Alshawi et al. / Current Problems in Surgery 63 (2025) 101707
https://www.sciencedirect.com/science/article/pii/S0011384024002685?ref=pdf_download&fr=RR-2&rr=954a99a00a0d0694

12. Dugan KC, Laxmanan B, Murgu S, Hogarth DK. Management of Persistent Air Leaks. Chest. 2017 Aug;152(2):417-423. doi: 10.1016/j.chest.2017.02.020. Epub 2017 Mar 4. PMID: 28267436; PMCID: PMC6026238.
<https://pmc.ncbi.nlm.nih.gov/articles/PMC6026238/pdf/main.pdf>

13. Prabhat B. Nichkaode, Rajendra Agrawal, Sachin Kumar Patel, “Thoracotomy and decortication in chronic empyema (fibrothorax), in the era of video assisted thoracic surgery” Int Surg J. 2017 Aug;4(8):2741-2745

14. Pan H, He J, Shen J, Jiang L, Liang W, He J. A meta-analysis of video-assisted thoracoscopic decortication versus open thoracotomy decortication for patients with empyema. J Thorac Dis. 2017 Jul;9(7):2006-2014. doi: 10.21037/jtd.2017.06.109. PMID: 28840000; PMCID: PMC5542928.

203

204

205

UNDER PEER REVIEW IN IJAR