

Carcinosarcoma of the uterine cervix: A case report with immunohistochemical analysis.

by Jana Publication & Research

Submission date: 29-Jul-2025 12:59PM (UTC+0700)

Submission ID: 2690326558

File name: IJAR-53033.docx (13.44M)

Word count: 1079

Character count: 6443

⁸ Carcinosarcoma of the uterine cervix: A case report with immunohistochemical analysis.

ABSTRACT:

Carcinosarcoma ¹³ of uterine cervix is a rare neoplasm. ¹² This report describes the histopathological and immunohistochemical profiles of a malignant cervical tumor with a mixed morphology of mesonephric carcinosarcoma and HPV dependent squamous cell carcinoma. A 51 year old female presented with the complain of bleeding per vagina since 2 weeks. MRI revealed a 36 x 50 x 45mm lesion involving cervix, lower uterine segment and vaginal fornices. The final histomorphology revealed a poorly differentiated tumor with mixed features of squamous cell carcinoma and mesonephric carcinosarcoma. Immunohistochemical analysis revealed expression of p40, p63, p16 and AR in squamous component and expression of GATA3, CD10 and Calretinin in mesonephric component. P16 positivity in squamous cell component indicated HPV associated carcinoma. The immunological findings support the metaplastic theory that carcinosarcoma may stem from the carcinomatous elements

and then differentiate into sarcoma components. The coexistence of carcinosarcoma and cervical squamous cell carcinoma in our patient support this theory. Immunohistochemistry plays an important role for diagnosis of such unusual mixed type of tumors.

KEY WORDS: mesonephric carcinosarcoma, HPV dependent squamous cell carcinoma, immunohistochemistry.

INTRODUCTION:

³ Carcinosarcoma is a biphasic malignant neoplasm composed of epithelial and mesenchymal components. ³ Primary cervical carcinosarcomas are much less frequent than tumors arising in the uterine corpus or ovary. Some tumors ³ are associated with high-risk HPV infection (types 16 and 18).⁽¹⁾⁹

CASE REPORT:

A 51 years old woman presented with the complain of bleeding per vagina since 2 weeks. She was on medical treatment for hypertension. MRI pelvis revealed a 36 x 51 x 45 mm lesion involving the cervix, lower uterine segment and upper vaginal fornices. The cervical biopsy report indicated a poorly differentiated malignant epithelioid to spindle cell tumor. The immunohistochemical profile on cervical biopsy indicated mesonephric carcinosarcoma. Both epithelioid and spindle cells express GATA-3 and CD 10 (Figure 3). The epithelioid cells express EMA, CK7, Calretinin and SF 1. ¹¹ The tumor cells were negative for ER, PR, WT1, Cyclin D1 and Inhibin. After this, the patient received 2 cycles of neoadjuvant systemic therapy (Paclitaxel and carboplatin). MRI revealed a significant reduction in size of the cervical lesion.

Radical hysterectomy with bilateral salpingo-oophorectomy and and bilateral pelvic lymphadenectomy was performed. The received specimen

consisted of uterus with bilateral adnexa and vaginal cuff. An irregular infiltrative tumor was identified involving all four quadrants of the cervix and extending upto lower uterine segment measuring 30 x 25 x 8 mm. Uterine corpus was normal on gross examination. Histopathological analysis of the infiltrating tumor revealed a mixed type of tumor consisting of Mesonephric carcinosarcoma and HPV- dependent Squamous cell carcinoma (Figure 1 & 2) associated with a high-grade squamous intraepithelial lesion.

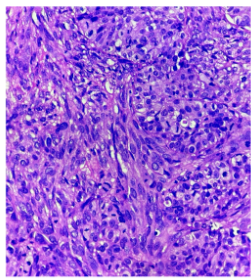


Figure 1- Malignant mesenchymal component in mesonephric carcinosarcoma, H & E (Figure 5) and AR (30%, moderate). The mesonephric component was

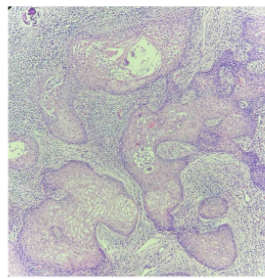


Figure 2- Squamous cell component in mesonephric carcinosarcoma, H & E (40x)

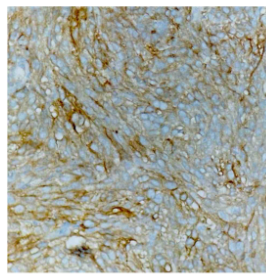


Figure 3- Tumor cells express CD 10 in mesenchymal

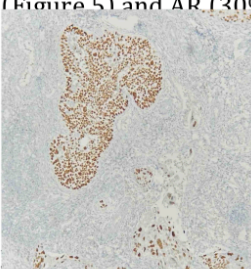


Figure 4- Tumor cells express p63 in squamous cell

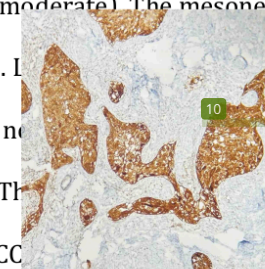


Figure 5- Tumor cells express p16 in squamous cell

The squamous cell component expresses p40, p63 (Figure 4), p16 (Figure 5) and AR (30%, moderate). The mesonephric component was 63. L... sion was present, as ne... al lymph nodes were s. Th... age classification was AJCC... ent was advised adjuvant chemotherapy and radiotherapy.

¹**DISCUSSION:**

Cervical carcinosarcoma is an extremely rare tumor, with only 128 documented cases in the literature.⁽²⁾ ¹Cervical carcinosarcoma mainly occurs in postmenopausal women, with a mean age at diagnosis of 64 years and a range of 25 to 93 years.⁽²⁾ Patients usually ¹present with vaginal bleeding as the initial symptom, which leads to a diagnosis of a cervical mass.⁽³⁾ Our ¹patient was 51-years-old and presented with complain of vaginal bleeding. Most cervical carcinosarcomas ¹are detected in Stage IB, and at the time of diagnosis the disease is confined to the cervix in most women, including our ¹patient.^(2,4,5) The histological features of carcinosarcoma are mixed comprising of epithelial and mesenchymal component. Depending on the degree of differentiation based on homologous and heterologous component further classified as homologous or heterologous.⁵ ²Both adenocarcinoma and squamous cell carcinoma ²have been observed as epithelial component of cervical carcinosarcomas.⁽⁶⁾ There is increasing evidence that carcinosarcoma represents a mesenchymal metaplasia of epithelial tumors.^(6,8) The coexistence of carcinosarcoma and squamous cell carcinoma in our patient appears in agreement with this hypothesis.

² Several etiologic factors related to the incidence of carcinosarcomas have been reported, as radiation exposure to the pelvic area, previous chemotherapy and infection with HPV, in particular type 16.^(6,7) ¹ Human papilloma virus (HPV) infection can be an important cofactor in the carcinogenesis of cervical carcinosarcoma.^(4,7,8) In this patient, squamous cell component is p16 positive suggesting ⁵ association with Human papilloma virus (HPV) infection. ⁶ Grayson et al. reported that HPV DNA was detected in all eight cases of the cervical carcinosarcomas they reviewed.⁽⁸⁾

² CONCLUSION

Carcinosarcoma of the uterine cervix is an extremely rare neoplasm, mostly occurring in older age group. The coexistence of mesenchymal component with p16 positive squamous cell component in our case supports the evidence of metaplastic theory of histogenesis.

REFERENCES

(1) Yemelyanova A, Kong CS, Srinivasan R, Carcinosarcoma of the uterine cervix, WHO classification of tumours, Female genital tumours, 5th edition, vol 4:p.391.

(2) Bansal S., Lewin S.N., Burke W.M., Deutsch I., Sun X., Herzog T.J., Wright J.D.: "Sarcoma of the cervix: natural history and outcomes". *Gynecol. Oncol.*, 2010, 118, 134. doi: 10.1016/j.ygyno.2010.04.021. Epub 2010 Jun 11.

(3) Sharma N., Sorosky J., Bender D., Fletcher M.S., Sood A.K.: "Malignant mixed mullerian tumor (MMMT) of the cervix". *Gynecol. Oncol.*, 2005, 97, 442.

(4) Clement P.B., Zubovits J.T., Young R.H. Scully R.E.: "Malignant mullerian mixed tumors of the uterine cervix: a report of nine cases of a neoplasm with morphology often different from its counterpart in the corpus". *Int. J. Gynecol. Pathol.*, 1998, 17, 211.

(5) Laterza R., Seveso A., Zefiro F., Formenti G., Mellana L., Donadello N. et al.: "Carcinosarcoma of the uterine cervix: case report and discussion".

Gynecol. Oncol., 2007, 107, S98. Epub 2007 Aug 28.[4] Bansal S., Lewin S.N., Burke W.M., Deutsch I., Sun X., Herzog T.J., Wright J.D.: "Sarcoma of the cervix: natural history and outcomes". *Gynecol. Oncol.*, 2010, 118, 134. doi: 10.1016/j.ygyno.2010.04.021. Epub 2010 Jun 11.

(6) Iida T, Yasuda M, Kajiwarra H, Minematsu T, Osamura RY, Itoh J, et al. Case of uterine cervical carcinosarcoma. *J Obstet Gynaecol Res* 2005;31:404–8.

(7) Takeshima Y, Amatya VJ, Nakayori F, Nakano T, Iwaoki Y, Daitoku K, et al. Co-existent carcinosarcoma and adenoid basal carcinoma of the uterine cervix and correlation with human papilloma virus infection. *Int J Gynecol Pathol* 2002;21:186–90.

(8) Grayson W, Taylor L, Cooper K. Carcinosarcoma of the uterine cervix: a report of eight cases with immunohistochemical analysis and evaluation of human papillomavirus status. *Am J Surg Pathol* 2001;25:338–47.

Carcinosarcoma of the uterine cervix: A case report with immunohistochemical analysis.

ORIGINALITY REPORT

40%

SIMILARITY INDEX

25%

INTERNET SOURCES

32%

PUBLICATIONS

0%

STUDENT PAPERS

PRIMARY SOURCES

1	www.irog.net Internet Source	12%
2	Laterza, R.. "Carcinosarcoma of the uterine cervix: Case report and discussion", Gynecologic Oncology, 200710 Publication	9%
3	djvu.online Internet Source	4%
4	Xinyao Shu, Yuwen Zhou, Guixia Wei, Xiaorong Chen, Meng Qiu. "Cervical Carcinosarcoma: Current Understanding on Pathogenesis, Diagnosis, Management and Future Perspectives", Clinical Medicine Insights: Oncology, 2021 Publication	3%
5	"Oncological Surgical Pathology", Springer Science and Business Media LLC, 2020 Publication	2%
6	obgyn.pericles-prod.literatumonline.com Internet Source	1%
7	spandidos-publications.com Internet Source	1%
8	www.pacificejournals.com Internet Source	1%

9 D. Maruthini. "Endometrioid adenocarcinoma of the ovary arising from endometriosis and presenting as an acute abdomen", Journal of Obstetrics and Gynaecology, 2007 1%

Publication

10 synapse.koreamed.org 1%

Internet Source

11 Ayman Elnemr, Yutaka Yonemura, Masaya Shinbo, Eisei Nishino. "Primary retroperitoneal mullerian adenocarcinoma", Rare Tumors, 2017 1%

Publication

12 Wayne Grayson. "Carcinosarcoma of the Uterine Cervix", The American Journal of Surgical Pathology, 03/2001 1%

Publication

13 Yu-Chieh Lin, Cherng-Lih Perng, Yi-Ming Chang, Yao-Feng Li, Yuan-Ming Tsai, Gwo-Jang Wu, Chih-Kung Lin. "Coexistent squamous cell carcinoma and adenoid basal carcinoma in the uterine cervix and infection with human papillomavirus (HPV 31)", Taiwanese Journal of Obstetrics and Gynecology, 2013 1%

Publication

Exclude quotes On

Exclude matches Off

Exclude bibliography On