

# THE FUSTIS OF MIDDLE EAR

## **Abstract:**

**Background:** The fustis is the largest bony trabecula of the middle ear, traversing from the basal turn of the cochlea to the styloid complex within the fundus of the round window chamber and subtympenic sinus. Its anatomical variability, structural features, and clinical-surgical importance are underappreciated in otologic literature.

**Objective:** To review the structural and functional anatomy of the fustis, highlight its variability, typology, and delineate its critical surgical significance in otological procedures.

**Methods:** A synthesis of available anatomical and clinical literature, combined with detailed morphologic characterization, was undertaken to describe the role of the fustis in normal and pathological middle ear states.

**Results:** The fustis, variably present and developed, is a smooth, oblique bony bar marking the boundary between the round window chamber and the sub cochlear tunnel. It provides structural support, anatomical guidance, and contributes to the resonance and ventilation mechanisms of the round window niche. Surgically, it serves as a key landmark for safe navigation and approach to the round window, and its preservation is crucial given its resistance to cholesteatoma and neo-osteogenesis risk upon drilling.

**Conclusion:** The fustis is a reliable anatomical marker and functional buttress in the middle ear, aiding surgical orientation and improving operative outcomes. Its respect in otologic surgery is paramount due to its unique anatomical and physiological properties [1][3][5][7].

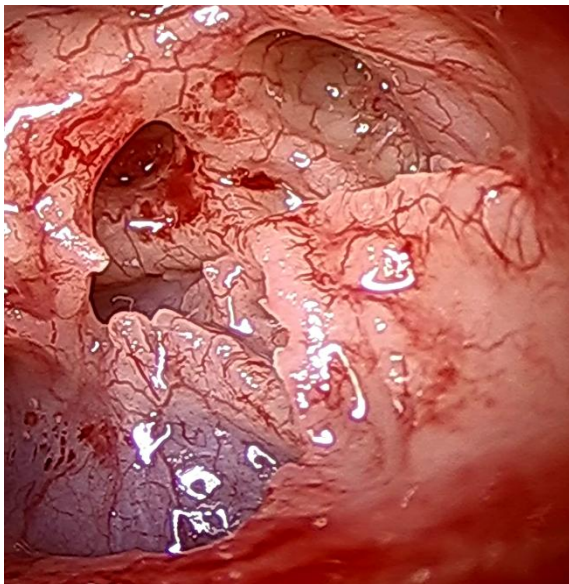
**Keywords:** Fustis, Endoscopic Anatomy, Round window chamber

## 1. Introduction:

- The **fustis** is the largest trabecular bony structure in the middle ear, named for its club-like appearance.

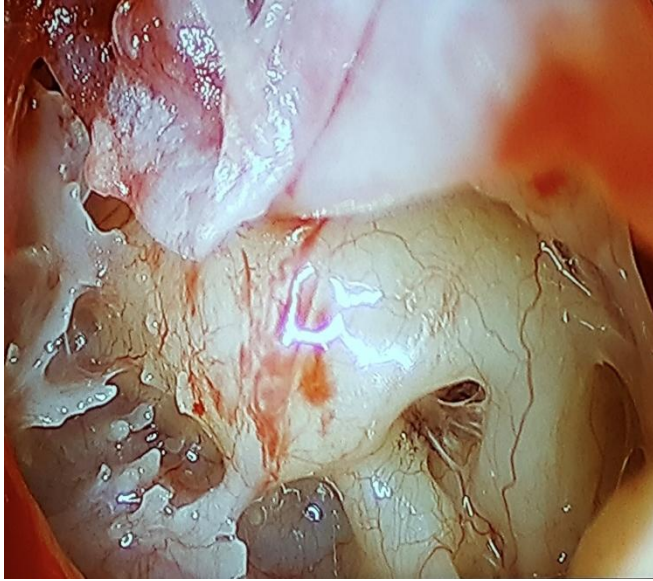
- Spanning obliquely from the styloid eminence to the basal turn of the cochlea, it crosses the fundus of the round window chamber and the subtympenic sinus [1][5][7].

- Its significance lies in its anatomical variability and critical landmarks for surgical orientation.



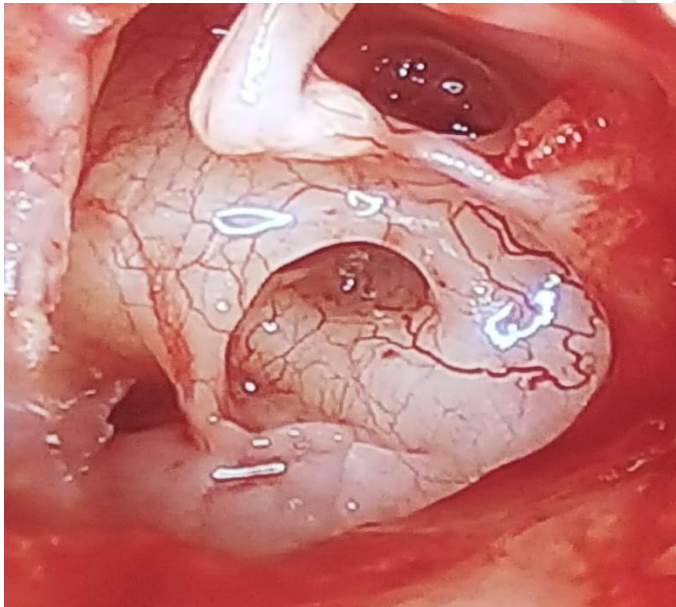
## 2. Anatomy of the Fustis:

- **Location:** Extends from the styloid eminence to the basal turn of the cochlea, forming an acute angle with the chamber entrance.



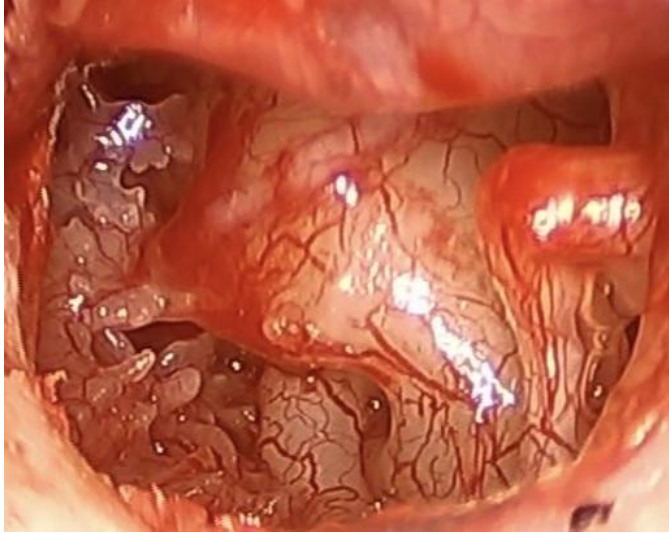33

34 - **Structure:** Smooth inside the round window chamber; dentate or lamellar/cellular toward the  
 35 styloid process.



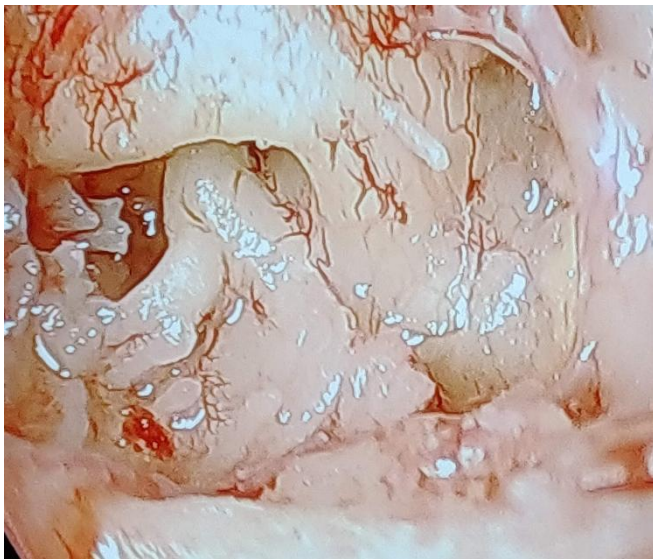36

37 - **Attachments:** Highly variable, can range from the styloid eminence to the finiculus within the  
 38 posterior tympanic cavity.



39

40 - **Variability:** May be rudimentary, well-developed, bifid, or even fused; often forms the  
 41 inferior border of the sinus tympani if the subiculum is missing.

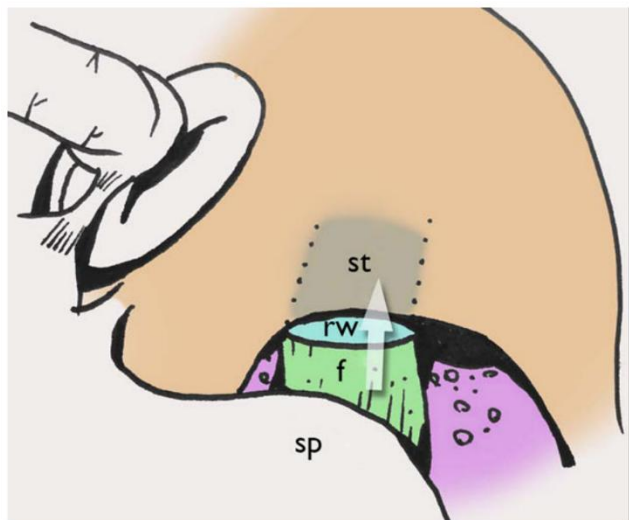


42

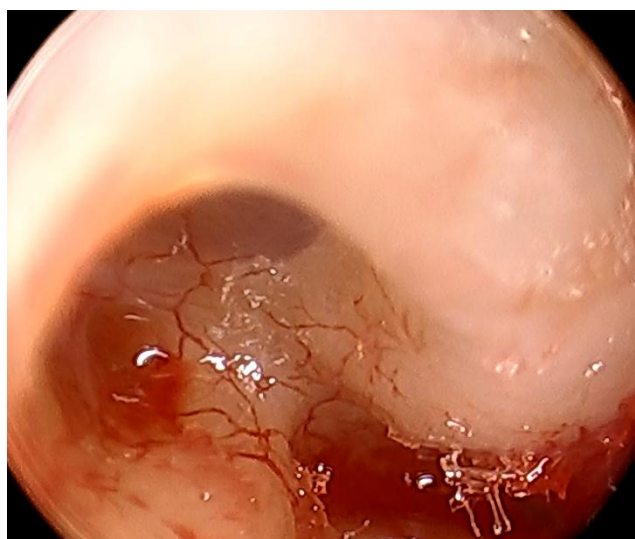
43

### 44 3. Typology of the Fustis

45 **Type A:** the direction of the fustis leads to the Scala tympani.

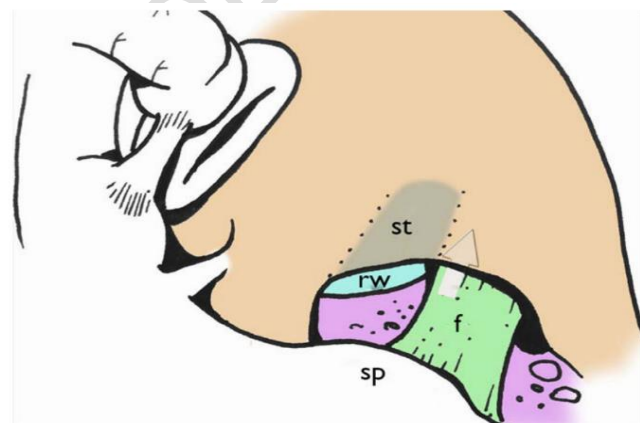


46



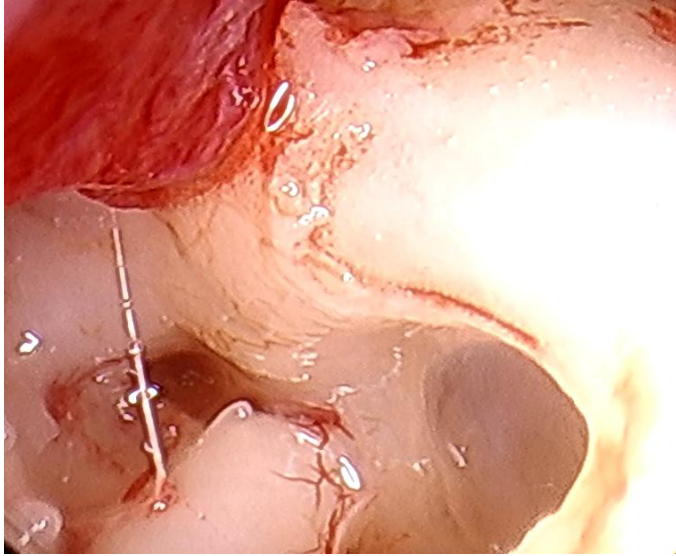
47

48 **Type B:** the anterosuperior limit of the fustis Lies just under the scala tympani.



49

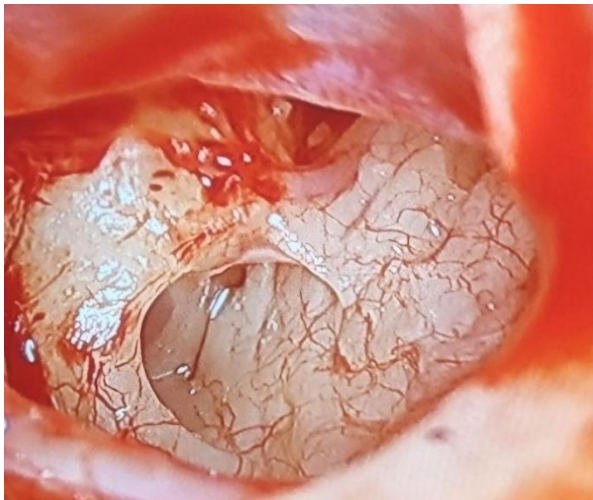




50

51

52 **Type C:** Absent or fused within the Subtympanic sinus.

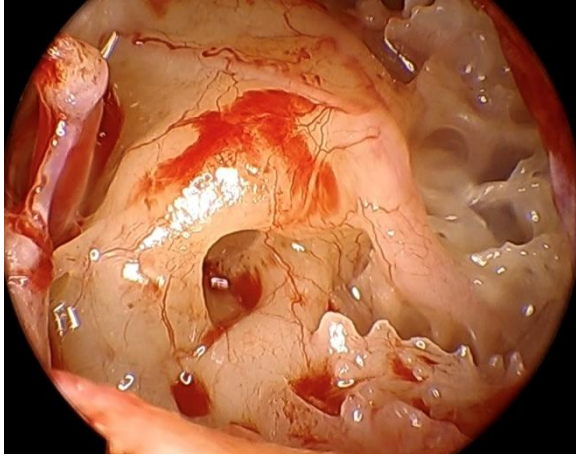


53

#### 54 **4. Surgical and Functional Significance**

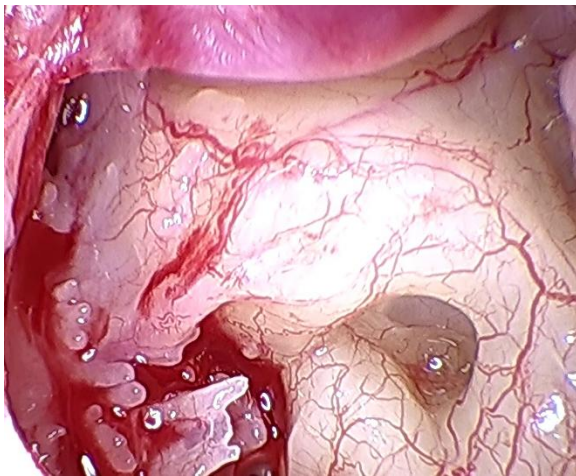
55

56 - **Support:** Provides a buttress for the otic capsule and supports the round window chamber,  
57 especially if the anterior or posterior pillar is absent [5][7].



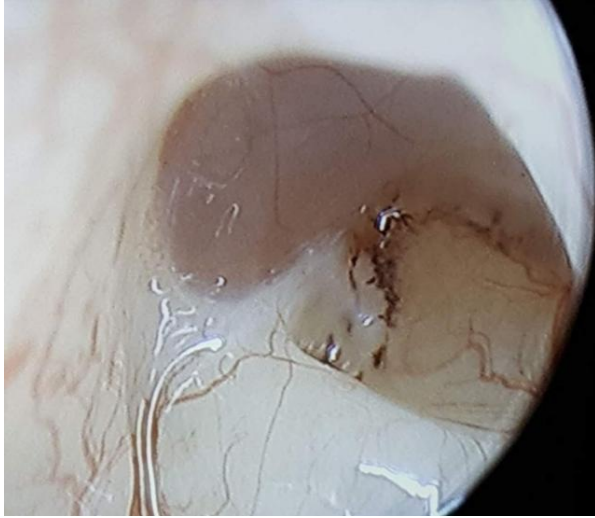
58

59 - **Surgical Landmark:** Acts as a constant, visible reference, even amid pathology (e.g.,  
60 cholesteatoma, CHARGE syndrome), guiding the surgeon to the round window.



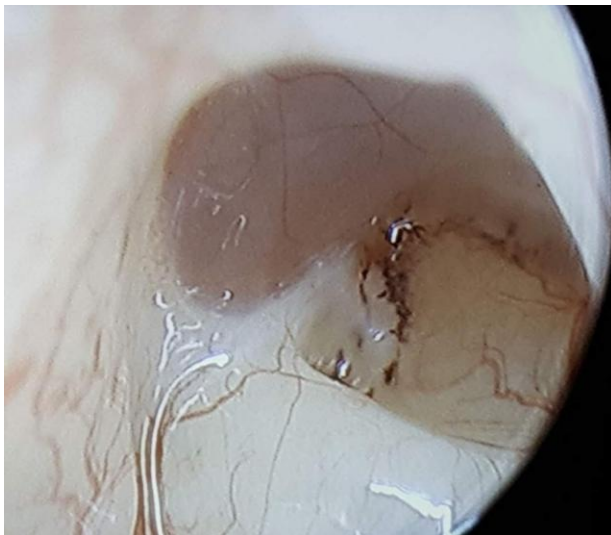61

62 - **Protective Role:** Its structure resists cholesteatoma invasion, likely due to its origin and dense  
63 bony enzymes.



64

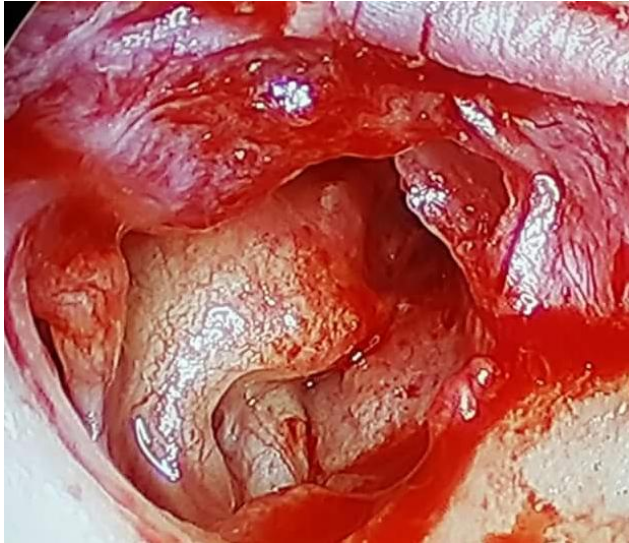65 - **Sound Resonance and Ventilation:** Defines airspaces and resonance chambers that contribute  
66 to optimal sound wave transmission and slow drug absorption through the round window [3][5].



67

68 - **Risks in Drilling:** The bone is hard and triggers excessive neoosteogenesis when drilled.  
69 Drilling avoidance is advised to preserve anatomical and functional integrity.

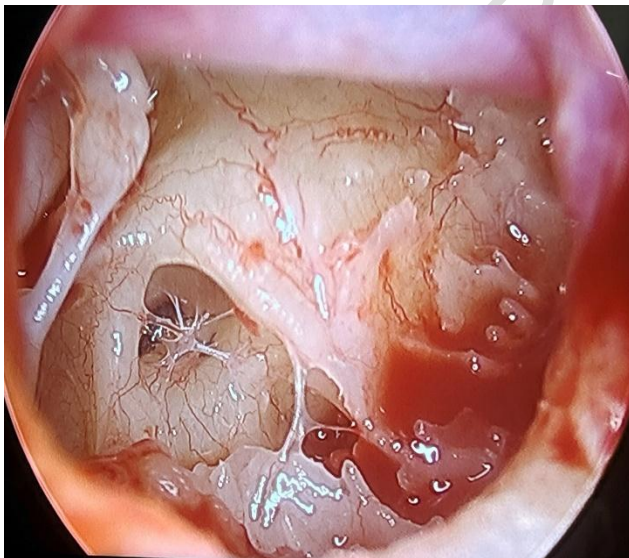




70

71 - **Functional Baffle:** Modulates outgoing sound waves, preventing distortion (baffle effect), a  
 72 key function for hearing acuity.

73 - **Barrier Formation:** With mucosal folds or pseudomembranes, restricts extension of  
 74 cholesteatoma into the round window chamber.



75

76 - **Anatomical Indicator:** The presence of melanocytes at its junction with the round window  
 77 suggests an additional biological protective mechanism.

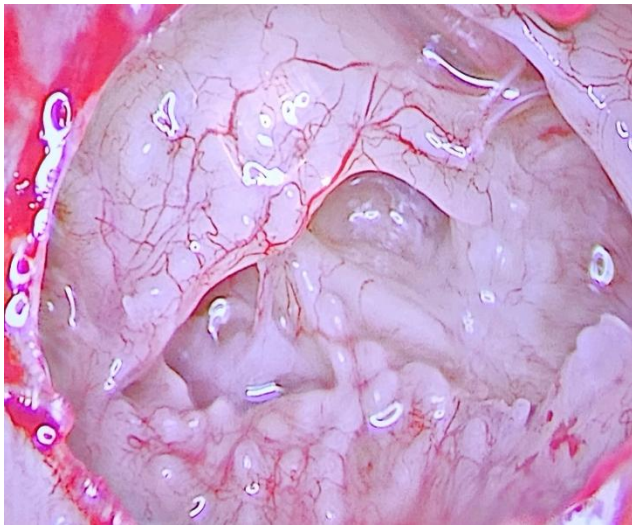
78

79 **5. Clinical Implications:**

80 - **Ventilation:** Ensures air pocket formation and ventilation in type 4 tympanoplasty.

81 - **Surgical Pathways:** Guides safe extra-cochlear routes toward the cerebellopontine angle.

82 **Adjunct Anatomy:** In cases with absent supporting structures (anterior or posterior pillars), the  
83 fustis alone may maintain chamber integrity.



84

85

86 **6. Conclusion:**

87 The fustis is a variable but vital structure in the middle ear, with substantial impact on surgical  
88 practice and auditory physiology. Detailed anatomical knowledge and cautious surgical  
89 technique regarding the fustis are central for optimal middle ear surgery and patient outcomes  
90 [1][3][5][7].

91

## 93 REFERENCES:

94 [1] Endoscopic Anatomy – Dr Nirmal Patel – ENT Surgeon ...  
95 <https://drnirmalpatel.com/articles/endoscopic-anatomy/>

96 [2] Auditory ossicles <https://www.kenhub.com/en/library/anatomy/auditory-ossicles>

97 [3] Round window chamber and fustis: endoscopic anatomy and ...  
98 [https://drnirmalpatel.com/wp-content/uploads/2016/09/endoscopic-anatomy-and-surgical-](https://drnirmalpatel.com/wp-content/uploads/2016/09/endoscopic-anatomy-and-surgical-implications.pdf)  
99 [implications.pdf](https://drnirmalpatel.com/wp-content/uploads/2016/09/endoscopic-anatomy-and-surgical-implications.pdf)

100 [4] The Radiology Assistant <https://radiologyassistant.nl/head-neck/temporal-bone/anatomy-2-0>

101 [5] Round window chamber and fustis: endoscopic anatomy ...  
102 <https://pubmed.ncbi.nlm.nih.gov/26975869/>

103 [6] Middle ear ossicles | Radiology Reference Article | Radiopaedia.org  
104 <https://radiopaedia.org/articles/middle-ear-ossicles?lang=us>

105 [7] The endoscopic anatomy of the cochlear hook region and ...  
106 <https://pmc.ncbi.nlm.nih.gov/articles/PMC6843579/>

107 [8] Structure of the Inner Ear  
108 <https://pdfs.semanticscholar.org/4fee/f8fa78c256708df284cfc398cfd6cbf42f7c.pdf>

109 [9] The Endoscopic Anatomy of the External Acoustic Meatus ... [https://www.thieme-](https://www.thieme-connect.com/products/ejournals/pdf/10.1055/s-0041-1731813.pdf)  
110 [connect.com/products/ejournals/pdf/10.1055/s-0041-1731813.pdf](https://www.thieme-connect.com/products/ejournals/pdf/10.1055/s-0041-1731813.pdf)

- 111 [10] Cochlea cadaver dissection – part 1 <https://www.slideshare.net/slideshow/cochlea-cadaver->  
112 [dissection-part-1/75137206](https://www.slideshare.net/slideshow/cochlea-cadaver-dissection-part-1/75137206)
- 113 [11] Marchioni D, Soloperto D, Colleselli E, Tatti MF, Patel N, Jufas N. Round window  
114 chamber and fustis: endoscopic anatomy and surgical implications. *Surg Radiol Anat.* 2016  
115 Nov;38(9):1013-1019. doi: 10.1007/s00276-016-1662-5. Epub 2016 Mar 14. PMID: 26975869.
- 116 [12] Proctor B, Bollobas B, Niparko JK (1986) Anatomy of the round window niche. *Ann Otol*  
117 *Rhinol Laryngol* 95:444–446
- 118 [13] Marchioni D, Alicandri-Ciufelli M, Pothier DD, Rubini A, Presutti L (2015) The round  
119 window region and contiguous areas: endoscopic anatomy and surgical implications. *Eur Arch*  
120 *Otorhinolaryngol* 272:1103–1112
- 121 [14] Proctor B (1969) Surgical anatomy of the posterior tympanum. *Ann Otol Rhinol Laryngol*  
122 78:1026–1040
- 123
- 124