

THE FUSTIS OF MIDDLE EAR

by Jana Publication & Research

Submission date: 06-Aug-2025 12:06PM (UTC+0700)

Submission ID: 2690325673

File name: IJAR-53125.docx (11.52M)

Word count: 868

Character count: 5679

THE FUSTIS OF MIDDLE EAR

Abstract:

Background: The fustis ⁴ is the largest bony trabecula ¹ of the middle ear, traversing from the basal turn of the cochlea to the styloid complex within the fundus of the round window chamber and subtymppanic sinus. Its anatomical variability, structural features, and clinical-surgical importance are underappreciated in otologic literature.

Objective: To review the structural and functional anatomy of the fustis, highlight its variability, typology, and delineate its critical surgical significance in otological procedures.

Methods: A synthesis of available anatomical and clinical literature, combined with detailed morphologic characterization, was undertaken to describe the role of the fustis in normal and pathological middle ear states.

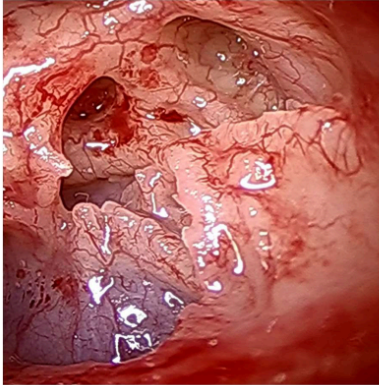
Results: The fustis, variably present and developed, is a smooth, oblique bony bar marking the boundary between the round window chamber and the sub cochlear tunnel. It provides structural support, anatomical guidance, and contributes to the resonance and ventilation mechanisms ³ of the round window niche. Surgically, it serves as a key landmark for safe navigation and approach to the round window, and its preservation is crucial given its resistance to cholesteatoma and neo-osteogenesis risk upon drilling.

Conclusion: The fustis is a reliable anatomical marker and functional buttress in the middle ear, aiding surgical orientation and improving operative outcomes. Its respect in otologic surgery is paramount due to its unique anatomical and physiological properties [1][3][5][7].

Keywords: Fustis, Endoscopic Anatomy, Round window chamber

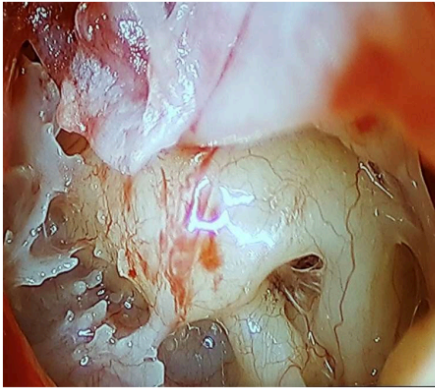
1. Introduction:

- The **fustis** is the largest trabecular bony structure in the middle ear, named for its club-like appearance.
- Spanning obliquely from the styloid eminence to the basal turn of the cochlea, it crosses the fundus of the round window chamber and the subtympenic sinus [1][5][7].
- Its significance lies in its anatomical variability and critical landmarks for surgical orientation.

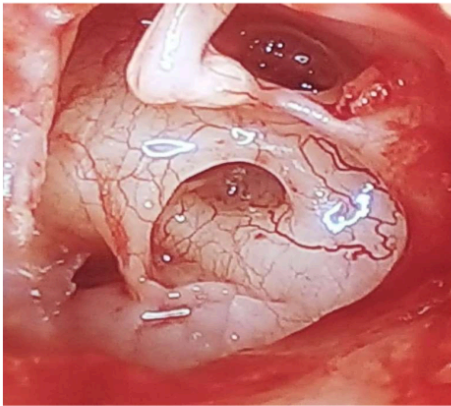


2. Anatomy of the Fustis:

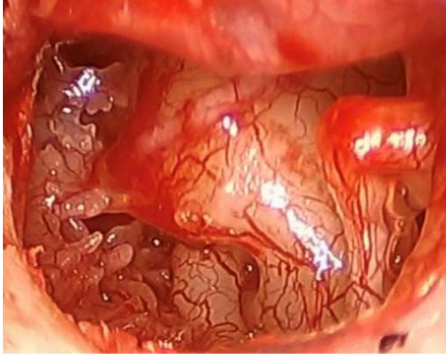
- **Location:** Extends from the styloid eminence to the basal turn of the cochlea, forming an acute angle with the chamber entrance.



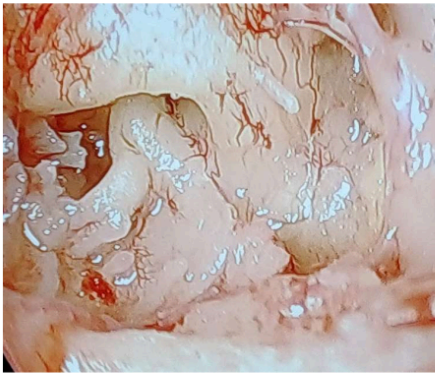
- **Structure:** Smooth inside the round window chamber; dentate or lamellar/cellular toward the styloid process.



- **Attachments:** Highly variable, can range from the styloid eminence to the finiculus within the posterior tympanic cavity.

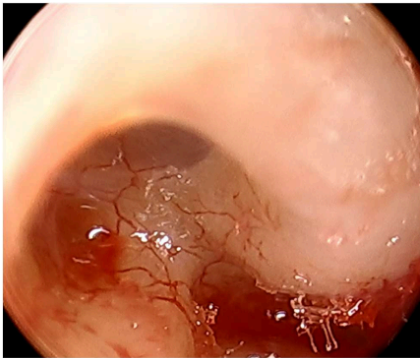
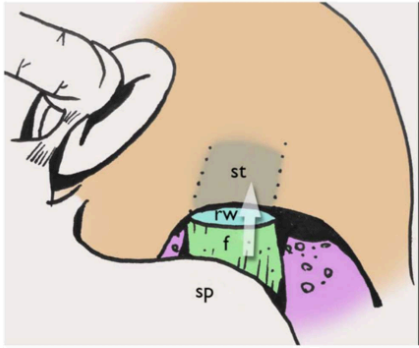


- **Variability:** May be rudimentary, well-developed, bifid, or even fused; often forms the inferior border of the sinus tympani if the subiculum is missing.

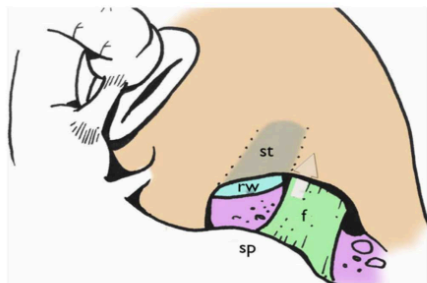


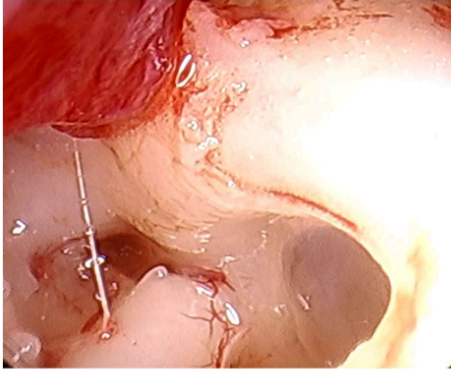
3. Typology of the Fustis

Type A: the direction of the fustis leads to the Scala tympani.

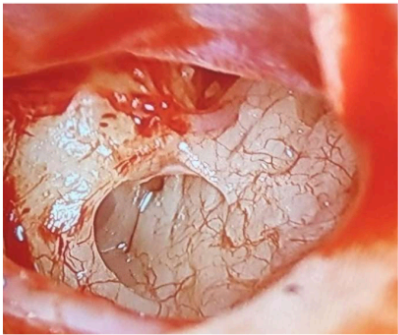


Type B: the anterosuperior limit of the fustis Lies just under the scala tympani.



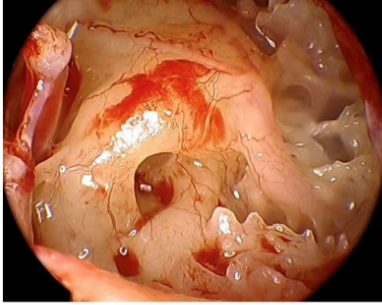


Type C: Absent or fused within the Subtymppanic sinus.

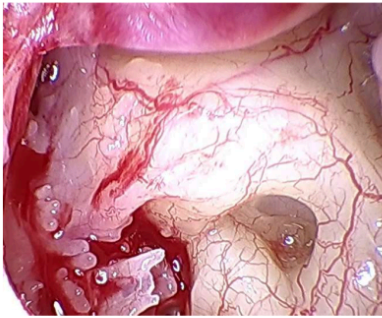


4. Surgical and Functional Significance

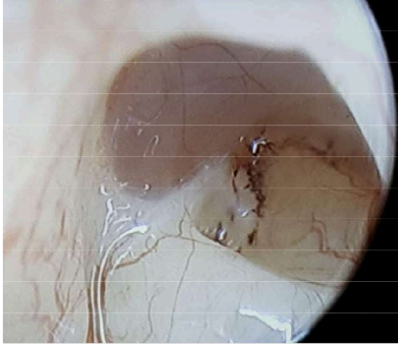
- **Support:** Provides a buttress for the otic capsule and supports the round window chamber, especially if the anterior or posterior pillar is absent [5][7].



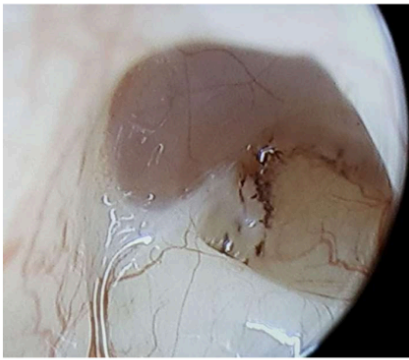
- **Surgical Landmark:** Acts as a constant, visible reference, even amid pathology (e.g., cholesteatoma, CHARGE syndrome), guiding the surgeon to the round window.



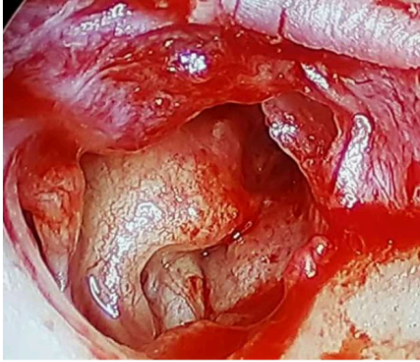- **Protective Role:** Its structure resists cholesteatoma invasion, likely due to its origin and dense bony enzymes.



- **Sound Resonance and Ventilation:** Defines airspaces and resonance chambers that contribute to optimal sound wave transmission and slow drug absorption through the round window [3][5].

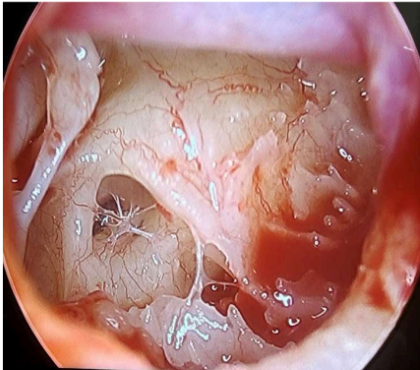


- **Risks in Drilling:** The bone is hard and triggers excessive neoosteogenesis when drilled. Drilling avoidance is advised to preserve anatomical and functional integrity.



- **Functional Baffle:** Modulates outgoing sound waves, preventing distortion (baffle effect), a key function for hearing acuity.

- **Barrier Formation:** With mucosal folds or pseudomembranes, restricts extension of cholesteatoma into the round window chamber.

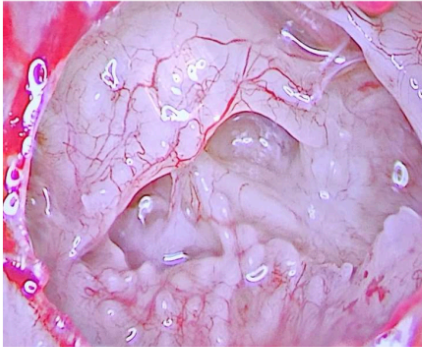


- **Anatomical Indicator:** The presence of melanocytes at its junction with the round window suggests an additional biological protective mechanism.

5. Clinical Implications:

- **Ventilation:** Ensures air pocket formation and ventilation in type 4 tympanoplasty.
- **Surgical Pathways:** Guides safe extra-cochlear routes toward the cerebellopontine angle.

Adjunct Anatomy: In cases with absent supporting structures (anterior or posterior pillars), the fustis alone may maintain chamber integrity.



6. Conclusion:

The fustis is a variable but vital structure in the middle ear, with substantial impact on surgical practice and auditory physiology. Detailed anatomical knowledge and cautious surgical technique regarding the fustis are central for optimal middle ear surgery and patient outcomes [1][3][5][7].

REFERENCES:

- [1] Endoscopic Anatomy – Dr Nirmal Patel – ENT Surgeon ...
<https://dnirmalpatel.com/articles/endoscopic-anatomy/>
- [2] Auditory ossicles <https://www.kenhub.com/en/library/anatomy/auditory-ossicles>
- [3] Round window chamber and fustis: endoscopic anatomy and ...
<https://dnirmalpatel.com/wp-content/uploads/2016/09/endoscopic-anatomy-and-surgical-implications.pdf>
- [4] The Radiology Assistant <https://radiologyassistant.nl/head-neck/temporal-bone/anatomy-2-0>
- [5] Round window chamber and fustis: endoscopic anatomy ...
<https://pubmed.ncbi.nlm.nih.gov/26975869/>
- [6] Middle ear ossicles | Radiology Reference Article | Radiopaedia.org
<https://radiopaedia.org/articles/middle-ear-ossicles?lang=us>
- [7] The endoscopic anatomy of the cochlear hook region and ...
<https://pmc.ncbi.nlm.nih.gov/articles/PMC6843579/>
- [8] Structure of the Inner Ear
<https://pdfs.semanticscholar.org/4fee/f8fa78c256708df284cfc398cfd6cbf42f7c.pdf>
- [9] The Endoscopic Anatomy of the External Acoustic Meatus ... <https://www.thieme-connect.com/products/ejournals/pdf/10.1055/s-0041-1731813.pdf>

[10] Cochlea cadaver dissection – part 1 <https://www.slideshare.net/slideshow/cochlea-cadaver-dissection-part-1/75137206>

[11] Marchioni D, Soloperto D, Colleselli E, Tatti MF, Patel N, Jufas N. Round window chamber and fustis: endoscopic anatomy and surgical implications. *Surg Radiol Anat.* 2016 Nov;38(9):1013-1019. doi: 10.1007/s00276-016-1662-5. Epub 2016 Mar 14. PMID: 26975869.

[12] Proctor B, Bollobas B, Niparko JK (1986) Anatomy of the round window niche. *Ann Otol Rhinol Laryngol* 95:444–446

[13] Marchioni D, Alicandri-Ciufelli M, Pothier DD, Rubini A, Presutti L (2015) The round window region and contiguous areas: endoscopic anatomy and surgical implications. *Eur Arch Otorhinolaryngol* 272:1103–1112

[14] Proctor B (1969) Surgical anatomy of the posterior tympanum. *Ann Otol Rhinol Laryngol* 78:1026–1040

THE FUSTIS OF MIDDLE EAR

ORIGINALITY REPORT

12%

SIMILARITY INDEX

9%

INTERNET SOURCES

12%

PUBLICATIONS

0%

STUDENT PAPERS

PRIMARY SOURCES

1

link.springer.com

Internet Source

6%

2

"12 Endoscopic Assisted and Transcanal Procedures in Cochlear Implant Endoscopic Assisted and Transcanal Procedures in Cochlear Implant", Georg Thieme Verlag KG, 2023

Publication

3%

3

Ignacio Javier Fernandez, Marco Caversaccio, Michael Ghirelli, Matteo Fermi, Luca Bianconi, Abraam Yacoub, Lukas Anschuetz. "Chapter 9 Round Window Dissection and Cochlear Implantation", Springer Science and Business Media LLC, 2021

Publication

1%

4

Salah Mansour, Jacques Magnan, Hassan Haidar Ahmad, Karen Nicolas, Stéphane Louryan. "Comprehensive and Clinical Anatomy of the Middle Ear", Springer Science and Business Media LLC, 2019

Publication

1%

5

Daniele Marchioni, Matteo Alicandri-Ciufelli, David D. Pothier, Alessia Rubini, Livio Presutti. "The round window region and contiguous areas: endoscopic anatomy and surgical implications", European Archives of Oto-Rhino-Laryngology, 2014

Publication

1%

Exclude quotes	On	Exclude matches	Off
Exclude bibliography	On		