

MANDIBULAR MOLAR WITH RADIX ENTOMOLARIS AND MIDDLE MESIAL CANAL : A RARE CLINICAL ENCOUNTER

Manuscript Info

Manuscript History

Received: xxxxxxxxxxxxxxxx
Final Accepted: xxxxxxxxxxxx
Published: xxxxxxxxxxxxxxxx

Key words:-

Anatomical variations,
Endodontic treatment,
Mandibular first molars, Radix
entomolaris, Middle mesial
canal.

Abstract

middle mesial canal (MMC) in a mandibular first molar is exceptionally uncommon. This rare anatomical combination demands meticulous diagnostic evaluation and careful endodontic management to ensure all canal variations are properly identified and treated. Effective management requires accurate diagnosis, thorough exploration of all canals, precise chemomechanical preparation and three dimensional obturation that preserves the root canal's natural anatomy. The appropriate utilization of the advanced aids of magnification and technology, such as the microscopes, loupes, and cone-beam computed tomography (CBCT) enhances the success while dealing with such rare entities. This article presents a case report of an radix entomolaris with middle mesial canal which is definitely rare in occurrence and requires cautious management.

The simultaneous occurrence of
radix entomolaris (RE) and a

Copy Right, IJAR, 2025,. All rights reserved.

Introduction:-

Success in endodontics requires a solid grasp of dental anatomy as well as an awareness of the possibility of deviations from the norm. When root canal treatment fails to eliminate infection, endodontic failure occurs, often resulting in ongoing symptoms. The primary causes of endodontic treatment failure are incomplete instrumentation, improper cleaning and faulty obturation of root canal space. Frequently, root canals go untreated because the operator is unaware of their existence, particularly in teeth with auxiliary or aberrant root canals or anatomical abnormalities¹.

The mandibular permanent molars are known to exhibit anatomic variations. Radix entomolaris (RE) is the occurrence of an additional distolingual (DL) root in the mandibular molars, first mentioned in the literature by Carabelli (1844). The extra mesiobuccal (MB) root in mandibular molars was termed as radix paramolaris. The presence of middle mesial canal (MMC) was reported by Vertucci and Williams (1974)². This article deals with the management of a rare occurrence of radix entomolaris with middle mesial canal in the mandibular first molar.

Case report:-

A 35 year old female patient reported to the department of Conservative Dentistry and Endodontics with the chief complaint of pain in the lower left back teeth region since 2 days. The medical history was non contributory. On clinical examination, the left mandibular first molar (36) had tooth colored restoration and was tender on percussion. On vitality testing, the tooth showed delayed response to electric pulp testing. Preoperative radiograph (Fig : 1) showed radiolucency beneath the radiopacity approaching pulp with slight widening of periodontal space around the apical portion of mesial root. An additional distal root was also noticed. Based on these findings, the tooth was identified as radix entomolaris and the final diagnosis was symptomatic irreversible pulpitis with apical

periodontitis. Non surgical endodontic treatment was planned followed by crown placement. Adhering to the principles of ALARA, cone- beam computed tomography (CBCT) was advocated only if the case could not be clinically managed using magnification aids and digital radiography.

After receiving consent from the patient, the tooth was anesthetized by inferior alveolar nerve block using 2% lignocaine with 1: 80000 adrenaline. Under rubber dam isolation, the endodontic access was performed with a no: 2 endoaccess bur (Dentsply) and the access cavity margins were refined using the endo-Z bur (Dentsply). Clinical examination was done using the dental loupe (3.5x magnification) and the DG -16 (Dentsply) explorer revealed the MB,ML,DB and DL orifices initially. Further examination revealed MMC canal orifice along the line joining MB and ML orifice. All the canals were negotiated using K- files ISO 10 and the working length was determined by electronic apex locator (J Morita Root ZX) and confirmed by periapical radiographs. Orifices were enlarged using Protaper gold SX (Dentsply). Cleaning and shaping of all the 5 canals were done with Protaper gold files upto size F1 (Dentsply) using the crown down technique. The MMC was seen joining with the MB canal at its middle third. During instrumentation the root canals were irrigated using 3% sodium hypochlorite and 17 % EDTA was used as a final irrigant. Calcium hydroxide intracanal medicament was placed followed by temporary restoration and the patient was recalled after 1 week. At the second appointment the patient was asymptomatic. The canals were irrigated with 17% EDTA, saline and 2% chlorhexidine used as final irrigant. After drying the canals with paper points (Dentsply), master cone of Protaper size F1 (Dentsply) was selected for all 5 canals and confirmed using radiograph. Single cone obturation was done using AH plus sealer. Post endodontic restoration was done using composite (Fig : 1). The patient was asymptomatic when reported for review after 1 week.

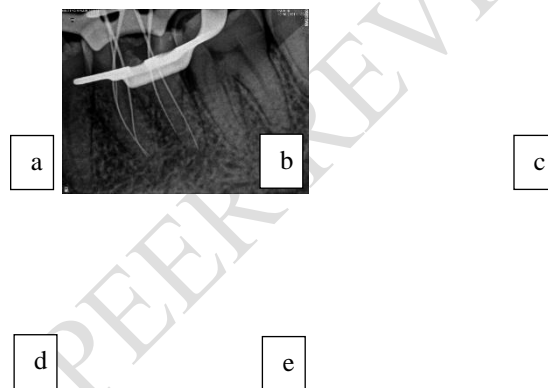
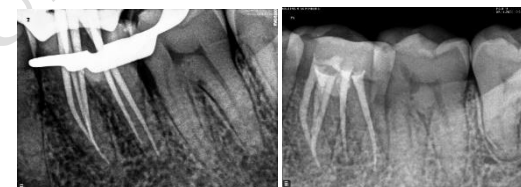

Figure 1:- (a) Pre-operative radiograph (b) Working length radiograph (c) clinical photograph showing middle mesial canal (d) Mastercone Post obturation radiograph (e) showing middle radiograph

Discussion:-

The
to the
and



occurrence of an additional lingual root was first brought notice of the world in the literature by Carabelli (1844) was labelled by Bolk (1915). The extra DL root was first mentioned by De Moor et al. and was termed as RE. Chandra et al. studied the mandibular first molars in the

South Indian population and found the prevalence of RE to be 13.3%. An RE can be found on the first, second and third mandibular molar, occurring least frequently on the second molar. Some studies report a bilateral occurrence of the RE from 50 to 67%³. Carlsen and Alexandersen (1990) classified RE into four different types based on the

location of its cervical part: Type A: The RE is located lingually to the distal root complex which has two cone-shaped macrostructures Type B: The RE is located lingually to the distal root complex which has one cone-shaped macrostructure Type C: The RE is located lingually to the mesial root complex Type AC: The RE is located lingually between the mesial and distal root complexes⁴. De Moor et al. (2004) classified RE based on the curvature of the root or root canal: Type 1: A straight root or root canal Type 2: A curved coronal third which becomes straighter in the middle and apical third Type 3: An initial curve in the coronal third with a second buccally oriented curve which begins in the middle or apical third⁵. Song et al. (2010) further added two more newly defined variants of RE: Small type: Length shorter than half of the length of the distobuccal root, Conical type: Smaller than the small type and having no root canal within it

The presence of middle mesial canal (MMC) was reported by Vertucci and Williams (1974). The incidence of MMCs accounts for 2.6–10% of the mandibular first molars⁶. Pomeranz et al. classified MMC into the following three morphologic categories: fin, confluent, and independent. In fin, there is free communication between all three canals; and in confluent, MMC joins one of the main canals.

In the present case report, the location and identification of the canal orifices were done by conventional methods using the DG-16 endodontic explorer, knowledge of the roots, and root canal anatomy along with that of the conventional periapical radiographs to determine the canal configuration. The RE in the case was found to be with straight root and root canal classified to be De Moors Classification Type I and MMC found to confluent joining with mesiobuccal canal.

Conclusion:-

Finding and negotiating additional canals requires a great deal of operator experience and careful understanding of the anatomic variations of the tooth. An endodontic treatment outcome may be considerably impacted if extra root canals are not detected and treated. The correct diagnosis and effective treatment of such complex morphologies will be aided by 3D imaging tools like CBCT and magnifying tools like loupes and a microscope.

References:-

- 1] Agarwal M, Trivedi HP, Mathur M, Goel D, Mittal S. The radix entomolaris and radix paramolaris: An endodontic challenge. The journal of contemporary dental practice. 2015 Jan 1;15(4):496-9.
- 2] Sathyan M, James B, Devadathan A, Johny MK, Nair M. Radix entomolaris with middle mesial canal: a rare case. Conservative Dentistry and Endodontic Journal. 2019;4(2):44-8.
- 3] Batista A, Lucato-Budziak MC, da Costa Michelotto AL, da Silva Neto UX. Mandibular First Molar with Six Canals: Case Report of Radix Entomolaris and Middle Mesial Canal. Iranian Endodontic Journal. 2021;16(1):65.
- 4] Khedkar SS. Endodontic Management of Radix Entomolaris: A Case Report. Journal of Medical and Dental Science Research. 2021;8(9):14-7.
- 5] De Moor RJG, Deroose CAJG, Calberson FLG. The radix entomolaris in mandibular first molars: an endodontic challenge. Int Endod J 2004;37(11):789–799. DOI: 10.1111/j.1365-2591.2004.00870.x.
- 6] Teixeira FB, Sano CL, Gomes BP, et al. A preliminary in vitro study of the incidence and position of the root canal isthmus in maxillary and mandibular first molars. Int Endod J 2003;36(4):276–280. DOI: 10.1046/j.1365-2591.2003.00638.x.

99

100

103

104

105

UNDER PEER REVIEW IN IJAR