

CLINICAL, RADIOLOGICAL AND SPIROMETRIC PROFILE OF PATIENTS WITH DIFFUSE PARENCHYMAL LUNG DISEASE (DPLD): A CROSS-SECTIONAL STUDY

by Jana Publication & Research

Submission date: 09-Aug-2025 04:09PM (UTC+0700)

Submission ID: 2690333011

File name: IJAR-53215.docx (866.13K)

Word count: 782

Character count: 5149

CLINICAL, RADIOLOGICAL AND SPIROMETRIC PROFILE OF PATIENTS WITH DIFFUSE PARENCHYMAL LUNG DISEASE (DPLD): A CROSS-SECTIONAL STUDY

INTRODUCTION:

Abstract

Background: Diffuse parenchymal lung diseases (DPLDs), also known as interstitial lung diseases (ILDs), encompass a diverse group of pulmonary disorders affecting the lung interstitium. Early diagnosis is critical but challenging due to overlapping clinical and radiological features.

Objective: To evaluate the clinical presentation, radiological patterns and functional impairment in patients diagnosed with DPLD at a tertiary care center.

Methods: A cross-sectional observational study was conducted on patients diagnosed with DPLD at Santhiram medical college and general hospital for the period March 2023-December 2024. Clinical symptoms, radiological features (HRCT thorax) and functional parameters (spirometry) were analyzed.

Results: The study included 60 patients with a mean age of 54.3 ± 11.2 years; 65% were male. The most common presenting symptom was exertional dyspnea (95%), followed by dry cough (85%). High-resolution CT (HRCT) showed usual interstitial pneumonia (UIP) pattern in 45%, nonspecific interstitial pneumonia (NSIP) in 30%, and hypersensitivity pneumonitis (HP) pattern in 15%. Functionally, 70% had a restrictive defect.

Conclusion: Most DPLD patients presented with exertional breathlessness and cough. UIP was the most common radiological pattern. Functional testing confirmed predominant restrictive defects, highlighting the importance of an integrated clinical-radiological-functional approach.

Introduction

Diffuse parenchymal lung diseases (DPLDs) are a heterogeneous group of disorders characterized by inflammation and/or fibrosis of the lung parenchyma. These include idiopathic interstitial pneumonias (IIP), hypersensitivity pneumonitis (HP), connective tissue disease-associated ILDs (CTD-ILD) and sarcoidosis among others.

Due to their chronic, progressive nature and varied etiologies, timely diagnosis and classification of DPLD are essential for optimal management. Clinicians rely on a combination of clinical assessment, high-resolution computed tomography (HRCT), and pulmonary function testing (PFT) to evaluate the disease.

This study aims to describe the clinical symptoms, radiological patterns, and functional impairments observed in patients diagnosed with DPLD.

2

Materials and Methods

Study Design:

- Cross-sectional observational study
- Conducted in the Department of Pulmonary Medicine, Santhiram Medical College and General Hospital, over a period of 19 months.

Inclusion Criteria:

- Age >18 years
- Confirmed diagnosis of DPLD (based on ATS/ERS guidelines)
- HRCT done within the last 3 months
- Baseline spirometry available

Exclusion Criteria:

- Active pulmonary tuberculosis or malignancy
- Acute infections
- Patients unwilling to participate

Data Collection:

- **Clinical:** Demographics, symptoms, duration, comorbidities
- **Radiological:** HRCT findings reviewed by expert radiologist
- **Spirometry:** (FVC, FEV1)

10

Statistical Analysis:

- Descriptive statistics used
- Categorical variables in %
- Continuous variables as mean \pm SD

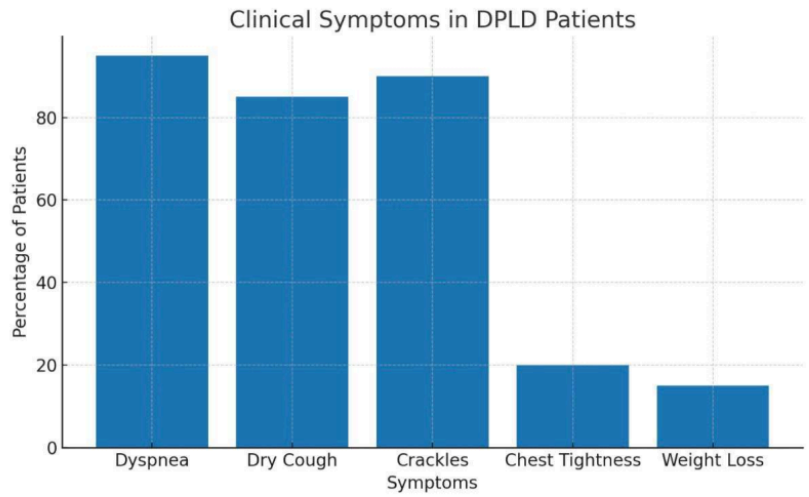
Results

Demographics:

- Total patients: 60
- Mean age: 54.3 ± 11.2 years
- Male: 39 (65%), Female: 21 (35%)
- Smoking history: 40%
- Known exposure to allergens (bird, mold, etc.): 20%

Clinical Profile:

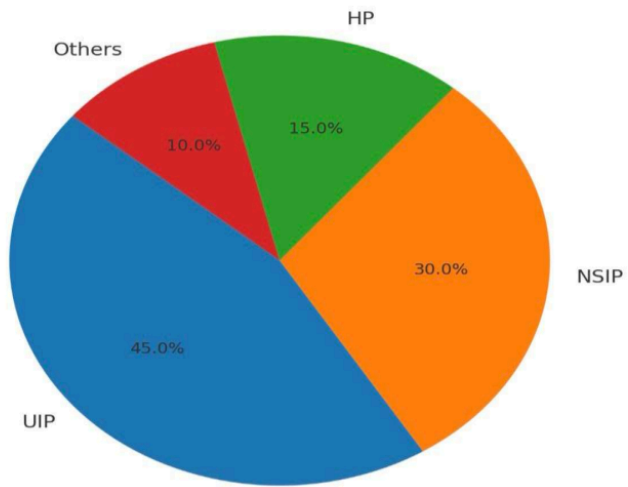
Symptom	Frequency (%)
Dyspnea	95%
Cough (dry)	85%
Chest tightness	20%
Weight loss	15%
Crackles (on auscultation)	90%



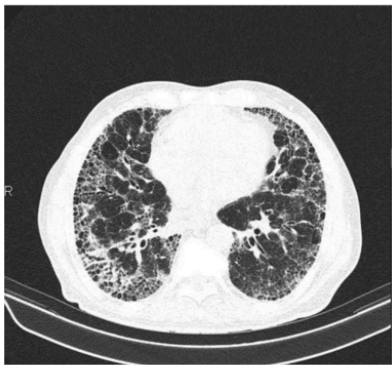Radiological Patterns (HRCT):

HRCT Pattern	% of Patients
9 UIP (Usual Interstitial Pneumonia)	45%
NSIP (Non-specific Interstitial Pneumonia)	30%
HP (Hypersensitivity Pneumonitis)	15%
Others (Sarcoidosis, LIP, etc.)	10%

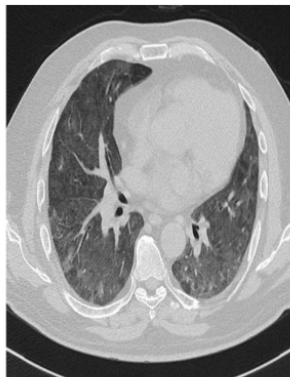HRCT Pattern Distribution in DPLD



HRCT IMAGES:



UIP PATTERN



NSIP PATTERN

Pulmonary Function Tests (PFTs):

Parameter	Mean \pm SD
FVC % predicted	62.5 \pm 14.3%
FEV1/FVC	0.78 \pm 0.06

- Restrictive pattern: 70%

Discussion

The study highlights that **exertional dyspnea and dry cough** are the most common symptoms in DPLD, consistent with prior studies. The **male predominance** and **mean age in the 5th decade** also mirror global epidemiological trends.

Radiologically, **UIP pattern** was predominant, especially in older males, suggesting a higher prevalence of idiopathic pulmonary fibrosis (IPF). **NSIP and HP** patterns were more common in younger patients and those with identifiable exposures.

Functionally, most patients exhibited **restrictive defects**, reflecting the fibrotic nature of the disease process.

Multidisciplinary evaluation, including clinical-radiological-pathological correlation, is vital for accurate diagnosis and management.

Conclusion

In patients with DPLD, clinical presentation is often nonspecific. HRCT remains the cornerstone for diagnosis and pattern recognition. Functional impairment, mainly restrictive correlates well with radiological severity. Early recognition and categorization of DPLD patterns can facilitate timely treatment and may improve outcomes.

Limitations

- Single-center study
 - Limited sample size
 - Lack of histopathological confirmation in all cases
 - No longitudinal follow-up
-

References

1. Raghu G, Remy-Jardin M, Myers JL, et al. Diagnosis of Idiopathic Pulmonary Fibrosis. ATS/ERS/JRS/ALAT Clinical Practice Guideline. *Am J Respir Crit Care Med*. 2018;198(5):e44–e68.
2. Travis WD, Costabel U, Hansell DM, et al. An official American Thoracic Society/European Respiratory Society statement: Update of the international multidisciplinary classification of the idiopathic interstitial pneumonias. *Am J Respir Crit Care Med*. 2013;188(6):733–748.
3. Meyer KC. Diagnosis and management of interstitial lung disease. *Transl Respir Med*. 2014;2:4.
4. Wells AU, Hirani N. Interstitial lung disease guideline: the British Thoracic Society in collaboration with the Thoracic Society of Australia and New Zealand and the Irish Thoracic Society. *Thorax*. 2008;63 Suppl 5:v1–58.
5. Cottin V, Cordier JF. Cryptogenic organizing pneumonia. *Semin Respir Crit Care Med*. 2012;33(5):462–473.

CLINICAL, RADIOLOGICAL AND SPIROMETRIC PROFILE OF PATIENTS WITH DIFFUSE PARENCHYMAL LUNG DISEASE (DPLD): A CROSS-SECTIONAL STUDY

ORIGINALITY REPORT

21%

SIMILARITY INDEX

19%

INTERNET SOURCES

15%

PUBLICATIONS

11%

STUDENT PAPERS

PRIMARY SOURCES

1

www.ncbi.nlm.nih.gov

Internet Source

5%

2

www.jcdr.net

Internet Source

2%

3

www.karger.com

Internet Source

2%

4

Submitted to Adtalem Global Education

Student Paper

2%

5

www.x-mol.com

Internet Source

2%

6

Submitted to University College London

Student Paper

2%

7

Marcy B. Bolster, Kristin B. Highland.
"Interdisciplinary Rheumatology -
Rheumatology and Pulmonology", CRC Press,
2025

Publication

1%

8

journals.sagepub.com

Internet Source

1%

9

www.vpci.org.in

Internet Source

1%

10

link.springer.com

Internet Source

1 %

11

Chuwei Jing, Yuchen Ding, Ji Zhou, Qun Zhang et al. "Optimizing treatment administration strategies using negative mNGS results in corticosteroid-sensitive diffuse parenchymal lung diseases", iScience, 2024

Publication

1 %

Exclude quotes On

Exclude matches Off

Exclude bibliography On