

# CASE REPORT - FAVORABLE OUTCOME OF ACUTE HYDROPS IN KERATOCONUS PATIENT TREATED WITH AUTOLOGOUS BLOOD

*by* Jana Publication & Research

---

**Submission date:** 09-Aug-2025 04:23PM (UTC+0700)

**Submission ID:** 2690351138

**File name:** IJAR-53228.docx (865.02K)

**Word count:** 887

**Character count:** 5503

# CASE REPORT - FAVORABLE OUTCOME OF ACUTE HYDROPS IN KERATOCONUS PATIENT TREATED WITH AUTOLOGOUS BLOOD

## Manuscript Info

### Manuscript History

Received: xxxxxxxxxxxxxxxx

Final Accepted: xxxxxxxxxxxxxxxx

Published: xxxxxxxxxxxxxxxx

### Key words: -

Acute corneal hydrops; Keratoconus;

Autologous blood; Stromal edema;

Interventional treatment

## Abstract

Acute corneal hydrops is a complication of advanced keratoconus, resulting from Descemet's membrane rupture, with intense stromal edema and significant visual loss. Among therapeutic alternatives, the use of autologous blood intra-stromally stands out as an option. In this case, it is presented a 32-year-old man with bilateral keratoconus, use of rigid contact lenses, and irregular medical follow-up. He presented with eye pain and low visual acuity in the right eye for 15 days. After an attempt of clinical treatment with hypertonic and corticosteroid eye drops without significant improvement, autologous blood injection was chosen. After 7 days, partial edema improvement was observed; at 15 days, complete resolution of hydrops. After 3 months, the condition remained stable, allowing visual rehabilitation with lens fitting. Autologous blood acted as a biological plug, promoting healing without complications associated with other approaches, such as gas injection. Thus, autologous blood proved to be an effective and safe alternative in the management of acute hydrops.

Copy Right, IJAR, 2025,. All rights reserved.

## Introduction: -

Acute hydrops is a rare but serious complication observed in the advanced stages of keratoconus. This condition results from a rupture of Descemet's membrane, leading to aqueous humor leakage into the corneal stroma and causing intense, diffuse corneal edema. Clinically, the patient may present with acute ocular pain, photophobia, and a marked decrease in visual acuity<sup>1</sup>. Initial management is typically conservative, involving the use of hypertonic solutions and topical corticosteroids. However, cases refractory to medical treatment may require additional interventions. Techniques such as intracameral gas injection, compressive sutures, and the use of intrastromal autologous blood have been described in the literature as effective therapeutic alternatives that promote faster resolution of stromal edema and may prevent or delay the need for corneal transplantation<sup>1</sup>. This case report aims to present a case of acute hydrops in a patient with keratoconus treated with intrastromal autologous blood injection and to describe the favorable clinical outcome.

## Methodology: -

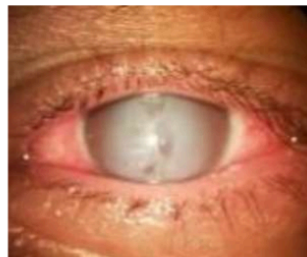This is a case report of a patient treated at a tertiary ophthalmology center, with a clinical and tomographic diagnosis of advanced keratoconus. Clinical data, ophthalmologic physical examination findings, additional exams,

and follow-up information were collected during outpatient monitoring. The patient underwent intrastromal autologous blood injection after the failure of initial conservative treatment. Follow-up included periodic evaluations with photographic and tomographic documentation over a three-month period.

### Results and Discussion: -

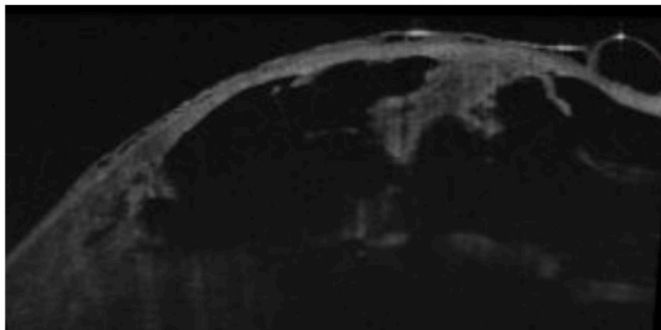
A 32-year-old male patient with a history of bilateral keratoconus and rigid contact lens use, with irregular ophthalmologic follow-up, presented with acute pain and decreased visual acuity in the right eye for the past 15 days. He had been using 5% sodium chloride eye drops every 6 hours and a low-potency corticosteroid every 12 hours since symptom onset, without significant clinical improvement. On examination, diffuse corneal edema was observed in the right eye, with visual acuity limited to hand motion perception (Figure 1). Optical coherence tomography (OCT) revealed the presence of fluid structures with aqueous humor infiltrating the corneal stroma, resulting in corneal edema (Figure 2).

Figure 01 – Ocular Inspection.



Source: Authors (2025)

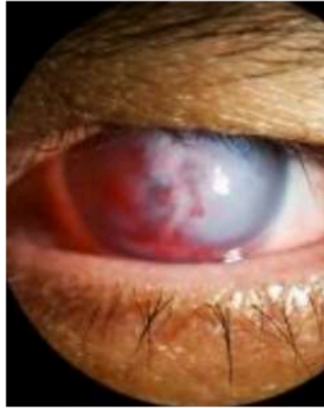Figure 02 – Optical coherence tomography



Source: Authors (2025)

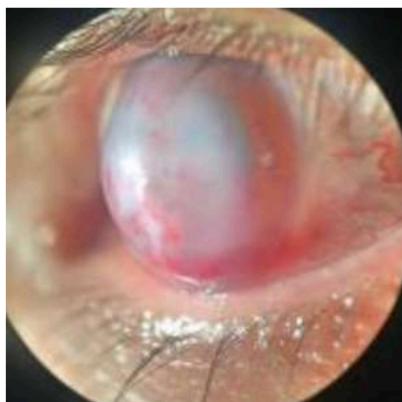In the absence of clinical improvement, an intrastromal injection of autologous blood was performed (Figure 3). During follow-up, persistent stromal edema was noted in the immediate postoperative period; after that, 7 days later, a significant reduction in edema and complete resolution of pain were observed. By day 15, the hydrops had fully resolved (Figure 4). After three months, the patient remained stable and was deemed suitable for a trial of rigid contact lens fitting (Figure 5).

Figure 03 –Autologous blood injection.



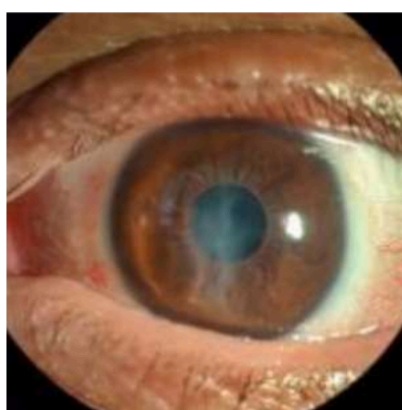
Source: Authors (2025)

Figure 04 – Fifteen days postoperatively



Source: Authors (2025)

Figure 05 – Three months postoperatively



Source: Authors (2025)

The literature describes the combined use of autologous blood as an effective measure for the rapid and safe resolution of stromal edema, facilitating early visual rehabilitation. In this therapeutic approach, autologous blood acts as a plug over the Descemet's membrane rupture<sup>2</sup>. This represents an alternative to C3F8 gas injection, which promotes apposition of the rupture edges, accelerating the reabsorption of edema and the healing process<sup>3</sup>, however, with the associated risk of early cataract formation.

In this case, the intervention demonstrated good efficacy, fast recovery, and patient comfort, reinforcing the importance of an individualized approach. Personalized treatment and close follow-up are essential for therapeutic

success.

### **Conclusion: -**

In this case, the use of intrastromal autologous blood proved to be an effective and safe alternative in the management of acute hydrops in a patient with pre-existing keratoconus. The treatment led to rapid resolution of stromal edema, avoiding the need for corneal transplantation and promoting visual rehabilitation. This case highlights the relevance of early and individualized interventions in scenarios refractory to conventional medical treatment.

### **References: -**

1. Basu S, Vaddavalli PK, Vemuganti GK, et al. Intracameral perfluoropropane gas in acute corneal hydrops. *Ophthalmology*. 2011; 118(5):934-939.
2. Panda A, Kumar S, Kumar A. Management of acute corneal hydrops in keratoconus. *Br J Ophthalmol*. 2007;91(8):1102-1103.
3. Sharma N, Mannan R, Titiyal JS, et al. Intracameral air injection and compressive sutures for acute corneal hydrops in keratoconus. *Cornea*. 2010;29(9):1060-1064.

# CASE REPORT - FAVORABLE OUTCOME OF ACUTE HYDROPS IN KERATOCONUS PATIENT TREATED WITH AUTOLOGOUS BLOOD

## ORIGINALITY REPORT

16%

SIMILARITY INDEX

9%

INTERNET SOURCES

14%

PUBLICATIONS

0%

STUDENT PAPERS

## PRIMARY SOURCES

1

[www.rmmg.org](http://www.rmmg.org)

Internet Source

5%

2

[amjcaserep.com](http://amjcaserep.com)

Internet Source

3%

3

Gonzalo García de Oteyza, Guido Bregliano, Irene Sassot, Luis Quintana, Carolina Rius, Ana Mercedes García-Albisua. "Primary surgical options for acute corneal hydrops: A review", European Journal of Ophthalmology, 2021

Publication

2%

4

"Resolving Dilemmas in Ophthalmology", Springer Science and Business Media LLC, 2024

Publication

1%

5

[www.ncbi.nlm.nih.gov](http://www.ncbi.nlm.nih.gov)

Internet Source

1%

6

H Yahia Chérif, J Gueudry, M Afriat, A Delcampe, P Attal, H Gross, M Muraine. "Efficacy and safety of pre-Descemet's membrane sutures for the management of acute corneal hydrops in keratoconus", British Journal of Ophthalmology, 2015

Publication

1%

7

Yogita Gupta, Chandradevi Shanmugam, Priyadarshini K, Sohini Mandal, Radhika

1%

Tandon, Namrata Sharma. "Pediatric keratoconus", Survey of Ophthalmology, 2025

Publication

8

"Keratoconus", Springer Science and Business Media LLC, 2022

Publication

1%

9

Tanvi Mudgil, Ritu Nagpal, Sahil Goel, Sayan Basu. "Chapter 12 Acute Corneal Hydrops: Etiology, Risk Factors, and Management", Springer Science and Business Media LLC, 2022

Publication

1%

Exclude quotes On

Exclude matches Off

Exclude bibliography On