

Anesthetic management of high grade butterfly glioma of the corpus callosum- A case report

by Jana Publication & Research

Submission date: 14-Aug-2025 12:02PM (UTC+0700)

Submission ID: 2690338851

File name: IJAR-53292.docx (323.14K)

Word count: 1981

Character count: 12903

Abstract- ¹Glioblastoma (GBM), is an aggressive brain tumor associated with poor prognosis. The history of GBM remains unfavorable; however, recent evidence demonstrates prolonged survival with maximal safe surgical resection followed by adjuvant radiotherapy and chemotherapy. ¹GBM typically spreads along white matter tracts. Growth and infiltration in certain tracts and eloquent areas of the brain, such as the corpus callosum, can render these tumors only partially resectable or unresectable. (1) GBM extending along the corpus callosum often shows a pattern of a butterfly on magnetic resonance imaging (MRI), hence the name butterfly glioma. This case report highlights the challenges faced by anesthesiologist in providing an optimal physiological condition during intra-operative period due to its critical location and its aggressive infiltrative nature. This report also focuses on how detailed pre-operative neurological assessment and tailored anesthetic technique can allow early assessment of neurological status and a how, close communication with the surgical team can diligently improve patient's outcome post-operatively.

Keywords- ⁹Glioblastoma (GBM), - Butterfly glioblastoma (bGBM) , Corpus callosum, Lobectomy, Cerebral Perfusion pressure (CPP), Intra-cranial pressure (ICP), Neuro-monitoring (IONM).

Introduction- ¹⁷Butterfly glioblastoma (bGBM) is a type of glioblastoma that spreads across the corpus callosum, affecting both sides of the brain. Previous studies have reported that it occurs in about 2.2% to 14.3% of adult glioblastoma cases. It is often linked to larger tumor size, aggressive treatment, and poor outcome. However, it's unclear if the poor prognosis is due to the tumor's nature or the way it's treated. More research is needed to understand which factors influence outcomes and how treatment decisions impact survival. There is no clear evidence on the best way to treat it, and it's uncertain whether general glioblastoma treatment guidelines apply to this subgroup. Some studies suggest that more aggressive treatment might still help, despite the poor outcomes. (2) In patients with bGBM , anesthetic management must be tailored to the tumor's bi-hemispheric involvement and proximity to eloquent brain regions. Total intravenous anesthesia (TIVA) using agents such as propofol and remifentanyl are recommended to facilitate neurophysiological monitoring and minimize intracranial pressure (ICP). (3) Intraoperative strategies included ICP control with mannitol and high ceiling diuretics, head elevation, and hyperventilation to provide a slack brain to the surgeon. Neuro-monitoring is essential, particularly during callosal dissection. Hemodynamic stability is critical to maintain adequate cerebral perfusion while avoiding hypertensive surges. Postoperative care involves

close neurological monitoring for potential complications such as cerebral edema, seizures, and new deficits.

Case Presentation- A 45-year-old male with no known comorbidities presented to our institution with a history of generalized involuntary jerky movements, suggestive of seizure activity. He had experienced two similar episodes previously. Neuroimaging performed during his initial evaluation elsewhere revealed a lesion consistent with butterfly glioma involving the corpus callosum. He was managed conservatively and referred to our center for further evaluation and treatment. The patient also reported neurobehavioral changes over the past month, including increased talkativeness, irritability, hyperphagia, and memory disturbances. However, recognition of familiar faces and names was preserved, and he remained functionally independent with no impairment in daily activities. There were no motor or sensory deficits, and no complaints of gait disturbance, headache, visual changes, or bowel/bladder dysfunction.

Diagnostic Assessment- On initial evaluation, the patient was hemodynamically stable with a pulse rate of 80 bpm, blood pressure of 150/90 mmHg, respiratory rate of 16 breaths per minute, and oxygen saturation of 99% on room air. Baseline laboratory parameters were within normal limits. Given the history of poor effort tolerance, a cardiology consultation was obtained. The patient was deemed fit for surgery, but classified as high cardiac risk, with a potential for perioperative major adverse cardiac events (MACE). Surgical clearance was granted with recommendations for enhanced perioperative cardiac and neurological surveillance and risk mitigation.

Plan- Oral intubation with Controlled mechanical ventilation under TIVA with all standard ASA monitors, invasive hemodynamic monitoring and IONM.

Therapeutic Intervention- The patient was categorized as ASA III, informed written consent obtained for high risk procedure, outlining post-operative management, peri-operative hemorrhage control if any, major adverse cardiac event risk, prolonged ICU Care, post-operative pulmonary complications and worsening of neurological functions. Primary goal was to optimize surgical conditions, protect neurological functions, maintain CPP, minimize bleeding, potentiate oncological benefits, maintain euvoemia, reduce peri-tumoral edema, maintain adequate urine-output and ensure smooth emergence to allow early neurological assessment. The patient received no premedication prior to surgery. After standard ASA monitoring and pre-oxygenation for 3 minutes, anesthesia was induced with remifentanyl 1 mcg/kg IV (administered slowly), propofol 2 mg/kg IV, and rocuronium 1 mg/kg IV to facilitate tracheal intubation. The airway

was secured with an 8.5 mm flexometallic endotracheal tube. Invasive arterial and central venous access were established under aseptic precautions for continuous monitoring and volume management. A single dose of magnesium sulfate 50 mg/kg IV was administered slowly for its analgesic, neuroprotective, and anesthetic-sparing effects. Maintenance of anesthesia was achieved with TIVA using propofol at 1 mg/kg/hr. and remifentanyl infusion at 0.05–0.2 mcg/kg/min, supplemented with desflurane at 0.6–0.8 MAC to ensure adequate depth while allowing neuromonitoring.(4) In anticipation of significant blood loss, tranexamic acid 1 g IV bolus was given, followed by a continuous infusion at 1 mg/kg/hr.(5) Intraoperative monitoring included invasive arterial pressure, central venous pressure, urine output, and serial blood gas analysis.(6) The surgical procedure, right frontal lobectomy, lasted 5 hours, with an estimated blood loss of approximately 700 mL, which remained within the allowable limit and did not necessitate transfusion. Fluid therapy was guided by hemodynamic parameters and urine output, maintaining euolemia and isobalance throughout. The intraoperative course was uneventful.

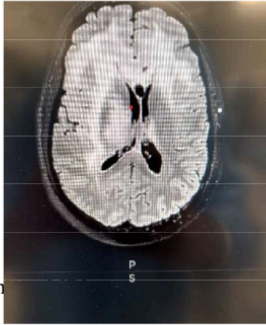


Image1- Bi-hemispheric involvement (butterfly

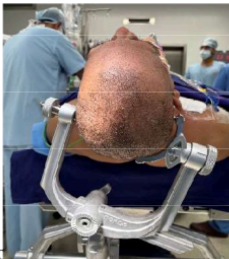


Image-2- Mayfield pins applied and head fixed at 15-30 degrees

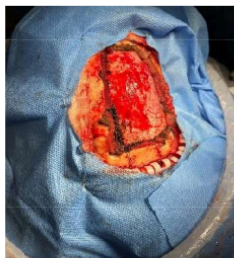

Image-3 – showing bi-coronal flap and frontal craniectomy.

14

Post-operative period and follow-up- At the end of the procedure, neuromuscular blockade was reversed with sugammadex, ensuring complete recovery of neuromuscular function.(7) The remifentanyl infusion was discontinued just prior to drape removal to allow controlled and hemodynamically stable emergence. The patient was extubated smoothly, with spontaneous ventilation, full orientation, and prompt responsiveness to simple verbal commands. He demonstrated intact motor function in all four limbs, enabling immediate and reliable neurological assessment. The anesthetic plan prioritized a smooth emergence to prevent bucking, straining, or coughing on the endotracheal tube, thereby minimizing the risk of intracranial hypertension, hemorrhage, or cerebral edema. Multimodal analgesia was employed using non-opioid agents (e.g., IV paracetamol) thus avoiding excessive sedation. PONV prophylaxis was administered intraoperatively to enhance patient comfort and prevent secondary complications. Comprehensive postoperative instructions were communicated to the neurosurgical and ICU teams, including the need for close neurological monitoring for potential complications such as intracranial hemorrhage, cerebral edema, pneumocephalus, seizures, and new-onset neurological deficits. Standard post-craniotomy protocols were initiated, including follow-up neuroimaging, antiepileptic therapy, and strict fluid and electrolyte management to optimize postoperative recovery and minimize secondary brain injury.

Discussion- Anesthetic management of surgical resection of butterfly glioma poses unique challenges to the anesthesiologist due to the site, extent and its aggressive nature. The main goals of anesthesiologist is to optimize the surgical field, preserve neuro-physiology and ensure smooth emergence. Anesthetic management can be further divided into three phases as follows-

Detailed pre-operative assessment- This phase includes detailed neurological assessment like motor, sensory and cognitive dysfunctions if any. This mainly serves as a baseline value that can be compared to new onset deficits if any. There should be adequate optimization of comorbidities if any before surgery. There should be effective and clear communication with the surgeon regarding the surgical plan, duration, expected blood loss and anticipated neurological deficits if any during post-operative period.

16

Intra-operative management -¹² Total Intravenous Anesthesia (TIVA) with propofol and remifentanyl is the preferred technique for craniotomies, particularly in cases involving raised intracranial pressure (ICP) or when intraoperative neuromonitoring (MEPs, SSEPs) is planned. (8) Propofol provides reliable control over cerebral physiology by reducing (CBF) and cerebral metabolic rate of oxygen (CMRO₂), contributing to ICP reduction.(9) In contrast, volatile agents are associated with increased CBF and ICP and may interfere with neuromonitoring, making them less ideal. TIVA offers preservation of evoked potentials, which is critical when functional mapping or real-time neurophysiologic monitoring is being utilized intraoperatively. An added point of interest is the ongoing investigation into propofol's potential anti-tumor properties, though current evidence remains inconclusive and experimental. Remifentanyl, owing to its rapid onset and offset, enables precise analgesic titration with minimal residual effect, allowing for smooth and prompt emergence. This is particularly advantageous for immediate post-extubation neurological assessment, a key requirement in neurosurgical anesthesia. Hemodynamic goals center around maintaining normotension and ensuring adequate cerebral perfusion pressure (CPP). Hypotension must be avoided, as it compromises CPP. Short-acting agents such as beta-blockers or calcium channel blockers may be used for tight blood pressure control. Fluid therapy typically favors isotonic crystalloids to maintain euvolemia, though debate continues between goal-directed versus restrictive fluid strategies in neurosurgery.(10)

ICP management strategies intraoperatively include:

- Head elevation to 30 degrees with the neck in a neutral, non-compressed position
- Ensuring appropriate endotracheal tube positioning to avoid endobronchial migration and increased airway pressures
- Mild hyperventilation (PaCO₂ ~30–35 mmHg)
- Minimal or no PEEP
- Use of osmotic agents (e.g., mannitol or hypertonic saline)
- Steroids, when indicated (e.g., for vasogenic edema)
- In select cases, lumbar CSF drainage may be considered to further reduce ICP.

Conclusion- Butterfly glioma presents significant anesthetic challenges due to its bilateral cerebral involvement and potential for raised intracranial pressure. The primary anaesthetic goals are to maintain cerebral perfusion pressure, control ICP, and ensure rapid postoperative neurological evaluation. TIVA with agents like propofol and remifentanyl is preferred. Preoperative optimization, intraoperative monitoring (including invasive lines and possibly neurophysiological monitoring), and vigilant postoperative care are crucial. Multidisciplinary coordination enhances safety and outcomes. Given the poor prognosis, anaesthetic care should balance surgical goals with patient comfort, ensuring a smooth, complication-free perioperative course.

Declaration of patient ²consent

The authors confirm that they have gotten the necessary consent from the patient involved. In the form, the patient's parent/guardian has given consent for his images and other clinical information to be reported in the journal. The patient and his parent/guardian understand that his name and initials will not be published, and due efforts will be made to conceal his identity; however, anonymity cannot be guaranteed.

⁴Financial support/sponsorship/Funding - *No funding was received for this research*

Conflicts of interest

There are no conflicts of interest.

References-

1. Opoku-Darko M, Amuah JE, Kelly JJP. Surgical Resection of Anterior and Posterior Butterfly Glioblastoma. *World Neurosurg.* 2018 Feb 1;110:e612–20.
2. Bjorland LS, Dæhli Kurz K, Fluge Ø, Gilje B, Mahesparan R, Sætran H, et al. Butterfly glioblastoma: Clinical characteristics, treatment strategies and outcomes in a population-based cohort. *Neuro-Oncol Adv.* 2022 July 1;4(1):vdac102.
3. Al-Rifai Z, Mulvey D. Principles of total intravenous anaesthesia: basic pharmacokinetics and model descriptions. *BJA Educ.* 2016 Mar 1;16(3):92–7.
4. Kumaria A, Hughes M, Fenner H, Moppett IK, Smith SJ. Total intravenous anaesthesia with propofol and remifentanyl is associated with reduction in operative time in surgery for glioblastoma when compared with inhalational anaesthesia with sevoflurane. *J Clin Neurosci Off J Neurosurg Soc Australas.* 2024 Feb;120:191–5.
5. Brown NJ, Wilson B, Ong V, Gendreau JL, Yang CY, Himstead AS, et al. Use of Tranexamic Acid for Elective Resection of Intracranial Neoplasms: A Systematic Review. *World Neurosurg.* 2022 Apr 1;160:e209–19.
6. Fejleh A. Central Venous Access for Neurosurgery: PRO Subclavian Vein (SCV), CON Internal Jugular Vein (IJV).
7. Hyland SJ, Pandya PA, Mei CJ, Yehsakul DC. Sugammadex to Facilitate Neurologic Assessment in Severely Brain-Injured Patients: A Retrospective Analysis and Practical Guidance. *Cureus.* 14(10):e30466.

8. Ghatol D, Widrich J. Intraoperative Neurophysiological Monitoring. In: StatPearls [Internet]. Treasure Island (FL): StatPearls Publishing; 2025 [cited 2025 July 20]. Available from: <http://www.ncbi.nlm.nih.gov/books/NBK563203/>
9. Neurophysiology - an overview | ScienceDirect Topics [Internet]. [cited 2025 July 20]. Available from: <https://www.sciencedirect.com/topics/neuroscience/neurophysiology>
10. Ryu T. Fluid management in patients undergoing neurosurgery. *Anesth Pain Med*. 2021 July 31;16(3):215–24.

Anesthetic management of high grade butterfly glioma of the corpus callosum- A case report

ORIGINALITY REPORT

18%

SIMILARITY INDEX

11%

INTERNET SOURCES

16%

PUBLICATIONS

6%

STUDENT PAPERS

PRIMARY SOURCES

- | | | |
|--|--|---------------------------------------|
| <div style="background-color: red; color: white; width: 30px; height: 30px; display: flex; align-items: center; justify-content: center; margin-bottom: 10px;">1</div> | <div style="color: red;">Michael Opoku-Darko, Joseph E. Amuah, John J.P. Kelly. "Surgical Resection of Anterior and Posterior Butterfly Glioblastoma", World Neurosurgery, 2018</div> <div>Publication</div> | <div style="font-size: 2em;">5%</div> |
| <div style="background-color: magenta; color: white; width: 30px; height: 30px; display: flex; align-items: center; justify-content: center; margin-bottom: 10px;">2</div> | <div style="color: magenta;">Srikanth Tanjore, Anand Murugesan, Naveen Hedne, Joseph Williams, Pavithra Shanmugam, Prethiv Raj Mohan, Sinduja Vairamuthu. "Better Perioperative Airway Management with Remifentanil in Trans-Oral Robotic Surgery for a Patient with Compromised Airway: A Case Report", Indian Journal of Otolaryngology and Head & Neck Surgery, 2025</div> <div>Publication</div> | <div style="font-size: 2em;">4%</div> |
| <div style="background-color: purple; color: white; width: 30px; height: 30px; display: flex; align-items: center; justify-content: center; margin-bottom: 10px;">3</div> | <div style="color: purple;">Submitted to National University College - Online</div> <div>Student Paper</div> | <div style="font-size: 2em;">1%</div> |
| <div style="background-color: teal; color: white; width: 30px; height: 30px; display: flex; align-items: center; justify-content: center; margin-bottom: 10px;">4</div> | <div style="color: teal;">Reinout A. Bem, Joris Lemson. "Evaluating fluid overload in critically ill children", Current Opinion in Pediatrics, 2024</div> <div>Publication</div> | <div style="font-size: 2em;">1%</div> |
| <div style="background-color: green; color: white; width: 30px; height: 30px; display: flex; align-items: center; justify-content: center; margin-bottom: 10px;">5</div> | <div style="color: green;">Submitted to Queen Margaret University College, Edinburgh</div> <div>Student Paper</div> | <div style="font-size: 2em;">1%</div> |
| <div style="background-color: brown; color: white; width: 30px; height: 30px; display: flex; align-items: center; justify-content: center; margin-bottom: 10px;">6</div> | <div style="color: brown;">www.docslides.com</div> <div>Internet Source</div> | <div style="font-size: 2em;">1%</div> |

7	ebin.pub Internet Source	<1 %
8	journals.lww.com Internet Source	<1 %
9	marvelousessays.com Internet Source	<1 %
10	www.annals.in Internet Source	<1 %
11	www.science.gov Internet Source	<1 %
12	"EUROANAESTHESIA 2006: Annual Meeting of the European Society of Anaesthesiology, Madrid, Spain, June 3–6, 2006", European Journal of Anaesthesiology, 06/2006 Publication	<1 %
13	Andrea Natale, Oussama M. Wazni, Kalyanam Shivkumar, Francis E. Marchlinski. "Handbook of Cardiac Electrophysiology", CRC Press, 2020 Publication	<1 %
14	Robert Bingham, Adrian Lloyd Thomas, M Sury. "Hatch & Sumner's Textbook of Paediatric Anaesthesia Third edition", CRC Press, 2019 Publication	<1 %
15	atuder.org.tr Internet Source	<1 %
16	healthdocbox.com Internet Source	<1 %
17	www.cureus.com Internet Source	<1 %

18 "Annual Meeting of the European Society of Anaesthesiology Munich, Germany, June 9–12, 2007", European Journal of Anaesthesiology, 06/2007

Publication

<1 %

19 Aria Jamshidi, Daniel Eichberg, Ricardo J. Komotar, Michael Ivan. "Safety Analysis of Bilateral Laser Interstitial Thermal Therapy for Treatment of Butterfly Glioma", World Neurosurgery, 2020

Publication

<1 %

20 "Textbook of Neurointensive Care: Volume 2", Springer Science and Business Media LLC, 2024

Publication

<1 %

Exclude quotes On

Exclude matches Off

Exclude bibliography On