

MEDICAL DEVICE-RELATED ADVERSE EVENT: FEMORAL SHEATH FRACTURE DURING PTCA

by Jana Publication & Research

Submission date: 14-Aug-2025 05:21PM (UTC+0700)

Submission ID: 2690342490

File name: IJAR-53328.docx (504.2K)

Word count: 1140

Character count: 7278

MEDICAL DEVICE-RELATED ADVERSE EVENT: FEMORAL SHEATH FRACTURE DURING PTCA

Abstract:

Introduction: A femoral sheath catheter is a flexible tube inserted into the femoral artery or vein during cardiac catheterization to guide a catheter into the heart. It provides femoral arterial access, with the sheath temporarily in place to reduce bleeding. The femoral artery is preferred for its size and compressibility, and closure devices seal the port post-procedure.

Case Summary: A 72 year old male patient of CAD with Inferior Wall Acute Myocardial Infarction was admitted for PTCA. Procedure was without complications and all the procedures were done by trained personnel under the guidance of Cardiac surgeon. Patient was shifted to ICU. Patient had bleeding and had Femoral sheath removal and after removal it was observed that the femoral sheath was broken.

Management: Imaging revealed presence of broken sheath in femoral artery. Exploratory procedure was done to remove the broken sheath.

Outcome: Patient was on ventilator support and was extubated after 3 days.

Discussion: This case highlights the need to recognize and report rare complications like femoral sheath fractures to the Materiovigilance Program of India (MvPI) to enhance device safety, guide clinical practice, and improve patient outcomes.

Conclusion: Reporting rare complications like femoral sheath fractures to the Materiovigilance Program of India is essential for improving device safety and clinical outcomes. Such vigilance ensures better management and prevention of similar incidents.

Keywords: PTCA, Femoral sheath, Embolization, MvPI.

Introduction:

Femoral sheath catheters are essential devices in interventional cardiology, providing secure vascular access during procedures such as percutaneous transluminal coronary angioplasty (PTCA). Inserted into the femoral artery, they facilitate catheter navigation to the coronary vasculature while reducing arterial trauma and bleeding risks. This access site is favored due to its superficial anatomical location, large vessel diameter, and ease of manual compression or use of closure devices post-procedure [1,2]. Despite their widespread use and overall safety, serious complications—though rare—may arise. Common issues include local bleeding, hematoma, pseudoaneurysm formation, arterial

dissection, or thrombosis. Among the most uncommon yet grave events is mechanical fracture of the sheath, which may result in intravascular retention of device fragments, leading to arterial thrombosis, distal embolization, limb ischemia, or myocardial infarction if migration occurs [1,3].

Fracture mechanisms may include manufacturing defects, structural fatigue due to prolonged dwell time, excessive manipulation, or resistance encountered during removal—often exacerbated by arterial spasm or tortuous anatomy [4]. Such events demand immediate recognition and intervention. In India, the

Materiovigilance Programme of India (MvPI) monitors such device-related adverse events at a national level, enabling root cause evaluation, regulatory action, and design improvements [5]. Here, we report a rare case of femoral sheath fracture during PTCA, detail its management and highlight the critical role of rapid intervention and materiovigilance reporting in safeguarding patient outcomes.

Case Description:

² A 72-year-old male with known coronary artery disease presented with signs consistent with inferior wall acute myocardial infarction. The patient was admitted for PTCA. The procedure was executed smoothly by experienced interventional cardiologists with support from a cardiac surgeon. Post-procedure, while in the ICU, active bleeding was noted at the femoral access site and the sheath was removed. The sheath appeared fractured, with a segment missing.

Emergent imaging—via fluoroscopy and Doppler ultrasound—confirmed a retained

fragment lodged in the femoral artery. An attempt at percutaneous embolectomy was made but failed. An exploratory laparotomy was performed under vascular surgery, successfully retrieving the fragment. Postoperatively, the patient required ventilatory support and was extubated on the third day without neurological or vascular complications. The event was classified as a serious device-related adverse event and promptly reported to the Materiovigilance Programme of India for documentation and quality assurance purposes.

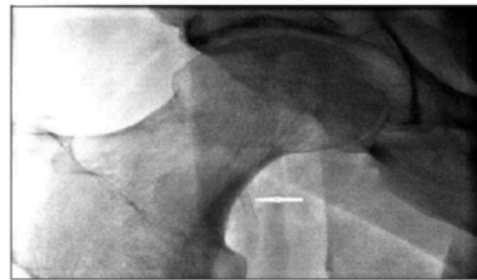


Figure 1. White arrow demonstrating the angiographic image of the trapped introducer sheath in the femoral artery.

Discussion:

Femoral sheath fracture during PTCA is exceedingly rare, with few cases documented in medical literature [1,3,4]. A retained intravascular fragment poses serious risks that vary depending on its location. When lodged in

the coronary circulation, it may precipitate acute thrombosis leading to myocardial infarction. Peripheral retention, as in our patient, can result in distal embolization or acute limb ischemia. The underlying mechanism often involves structural failure—due to flaws in manufacturing or material fatigue—especially under conditions of prolonged use or repeated manipulation. Mechanical stress such as excessive torque, forceful withdrawal, or resistance encountered from arterial spasm, vessel calcification, or tortuosity may contribute significantly to device compromise [4]. Prompt detection via fluoroscopy or ultrasound is essential to guide retrieval efforts. While percutaneous snare techniques are preferred for accessible fragments, surgical intervention becomes necessary when these attempts fail, as seen in our case.

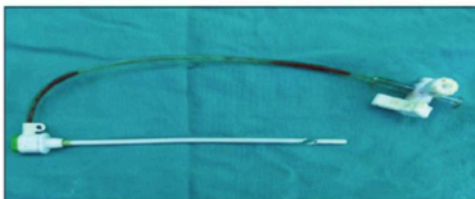


Figure 2. The main body and the fractured part of the introducer sheath after surgical retrieval.

Preventive measures revolve around meticulous device handling: inspecting the sheath before and after use for signs of crack or damage, avoiding forceful manipulation, and reducing dwell time when feasible. Furthermore, training interventional teams to recognize resistance during sheath maneuvers and to act swiftly is paramount. From a public health and regulatory perspective, materiovigilance reporting to MvPI plays a critical role. Documenting such rare but significant events enables pattern recognition, triggers action from manufacturers for redesign or recall, and informs institutional protocols to mitigate future risks [5]. In summary, while femoral sheath fracture is rare, its potentially life-threatening consequences call for heightened clinical vigilance, rapid management, and committed materiovigilance to ensure patient safety.

Conclusion:

This case underscores a rare yet serious complication of femoral sheath fracture during PTCA—highlighting how device failure can result in retained intravascular fragments with potentially grave consequences. Prompt


imaging, timely intervention, and surgical retrieval facilitated complete patient recovery without lasting morbidity. Equally crucial is reporting such events to the Materiovigilance Programme of India for broader safety oversight. Adhering to careful device inspection, avoiding excessive manipulation, and fostering awareness among cath-lab personnel are key preventive strategies. Through vigilant practice and active materiovigilance reporting, similar adverse events can be minimized, reinforcing patient safety in interventional cardiology.

Acknowledgement:

The authors express their ¹sincere gratitude to the Management and Administration of MGM Medical College, Chhatrapati Sambhaji Nagar, ¹for providing the necessary facilities and support to carry out this work. We are also thankful to the Departments of Pharmacology for their cooperation and assistance throughout the preparation of this manuscript. The authors further acknowledge with appreciation the contributions of all researchers whose work has been cited in this article.

References:

1. Yilmaz M, Gungor S, Erturk M, et al. Introducer sheath fracture in the femoral artery: an unpredicted complication. *Anatolian Journal of Cardiology*. 2015;15(9):787–789.
2. Shafi MS, Bapat A, Chag SSM, et al. An unusual femoral sheath severing with successful recapture. *Medical Sciences*. 2020;8(4):49.
3. Patel T, Shah S, Panchal H. Fractured femoral sheath: a rare complication of cardiac catheterization. *Indian Heart Journal*. 2016;68(Suppl 2):S301–S303.
4. Teo SS, Roberts KA, Blomfeld MJ, et al. Femoral shaft fracture resulting from femoral tracker placement in computer-assisted total knee arthroplasty. *Journal of Medical Case Reports*. 2008;2:43.
5. Materiovigilance Programme of India. Indian Pharmacopoeia Commission, Ministry of Health and Family Welfare, Government of India. Available from: <https://www.ipc.gov.in>



MEDICAL DEVICE-RELATED ADVERSE EVENT: FEMORAL SHEATH FRACTURE DURING PTCA

ORIGINALITY REPORT

3%

SIMILARITY INDEX

1%

INTERNET SOURCES

2%

PUBLICATIONS

0%

STUDENT PAPERS

PRIMARY SOURCES

1

Bolisetty Sreenivasulu, Inkollu Sreedhar, Pathi Suresh, Kondapuram Vijaya Raghavan.

"Development Trends in Porous Adsorbents for Carbon Capture", Environmental Science & Technology, 2015

Publication

2%

2

ndl.ethernet.edu.et

Internet Source

1%

Exclude quotes On

Exclude matches Off

Exclude bibliography On