

# A Novel Approach in the treatment of Horizontal Root Fracture using K-File with MTA as an Intra-Radicular splint

*by* Jana Publication & Research

---

**Submission date:** 21-Aug-2025 12:41PM (UTC+0700)

**Submission ID:** 2690333011

**File name:** IJAR-53444.docx (5.13M)

**Word count:** 1474

**Character count:** 8796

#### **A Novel Approach in the treatment of Horizontal Root Fracture using K-File with MTA as an Intra-Radicular splint**

##### **Abstract**

**Background:** Root fractures in permanent teeth are relatively rare and present complex healing processes, occurring more frequently in children. Mineral trioxide aggregate (MTA) is an endodontic material that offers significant advantages over traditional materials used in fracture repair. It is the first restorative substance known to consistently support the formation of cementum and may also aid in the regeneration of the periodontal ligament.

**Case Description:** This report details the endodontic treatment of a horizontally fractured upper left lateral incisor using MTA combined with an intraradicular splinting technique. After repositioning the fractured segments, the tooth was stabilized internally using a K-file and MTA as the sealing material. This case illustrates that MTA, along with intraradicular splinting, is an effective method for managing horizontally fractured teeth.

**Follow-up:** At the six-month follow-up, the tooth remained asymptomatic. Clinical and radiographic evaluations indicated excellent healing outcomes.

**Conclusion:** MTA demonstrates strong potential as a definitive root filling material for horizontal root fractures due to its superior biological compatibility and physical characteristics.

##### **INTRODUCTION**

Root fractures in permanent teeth are relatively uncommon, accounting for approximately 0.5% to 7% of all dental trauma cases. Horizontal root fractures predominantly occur in the anterior maxillary region, typically as a result of frontal impact. They are more commonly seen in fully erupted teeth with completely developed roots.<sup>1,2</sup> These fractures most often affect the middle third of the root and are less frequently found in the apical third.<sup>1,3,5</sup> Fractures located in the coronal third tend to have a poorer prognosis.<sup>5</sup> Treatment generally involves repositioning and stabilizing the affected tooth, if needed, and conducting long-term monitoring to assess pulpal vitality.<sup>6</sup> Root fractures are complex injuries, involving simultaneous trauma to the pulp, periodontal ligament, dentin, and cementum.<sup>1</sup> Mineral Trioxide Aggregate (MTA) is a biocompatible material widely used in endodontics due to its favorable properties. It has shown superiority over other materials in certain procedures related to root repair and bone regeneration.<sup>5</sup> This case report highlights the application of MTA to form a barrier at the coronal aspect of the fracture lines and to serve as an intraradicular splint in a mandibular lateral incisor with horizontal root fractures. The case also includes treatment details and long-term follow-up of a treated maxillary lateral incisor.

##### **CASE DESCRIPTION**

A 15 year old female child visited the reported the Department of Conservative Dentistry and Endodontics of Kanti Devi Dental College and Hospital, Mathura with the complaint of loose

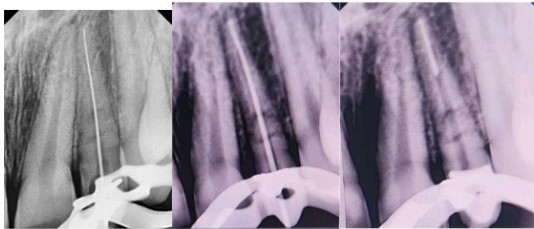
tooth in the upper front region. She had suffered a dental injury in the upper anterior tooth due to fall while playing. Trauma had happened five months ago. The clinical examination revealed grade II mobility. The tooth did not respond to electric and thermal pulp tests. Discomfort was noted during percussion and palpation. Radiographic examination revealed horizontal fracture in the cervical third of the root on the upper left lateral incisor. There was no significant bone loss. Patient's oral hygiene was satisfactory.

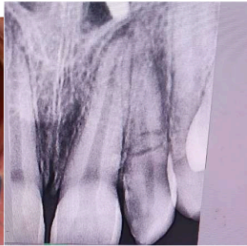
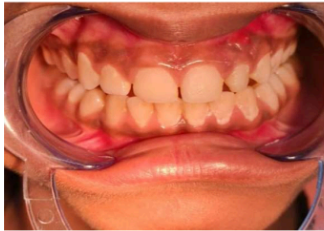
FIGURE 1-Pre-operative photograph

FIGURE 2- Radiograph showing horizontal fracture

The tooth was isolated with rubber dam. Endodontic treatment of the lateral incisor was initiated under local anesthesia (2% lignocaine with 1:80,000 adrenaline) access opening was done. Working length was determined by apex locator and radiographically confirmed. Canals were prepared in step back preparation using hand K-file with apical file size of 45/0.02 (Dentsply Maillefer, OK, USA).



(a)

(b)

(c)

Figure 3-(a) Working length radiograph. (b) Master apical radiograph (c) Post space preparation

The necrotic pulp tissue was extirpated. During the preparation, canals were copiously irrigated using 5.25% NaOCl, 17% EDTA and normal saline. The canal was obturated using the lateral condensation technique with Gutta Percha and AH plus sealer (Dentsply, Konstanz, Germany) followed by temporary sealing of the cavity using Cavit (3M Espe,

Seefeld, Germany) and patient was recalled. In the next appointment, post space was prepared using peeso reamer size no 1 leaving 5mm of gutta-percha in canal. A sterile **#70 K-file** (Dentsply Maillefer, OK, USA) was inserted into the canal, extending from the coronal to the apical fragment. File length was adjusted to stabilize both segments passively without exerting pressure.

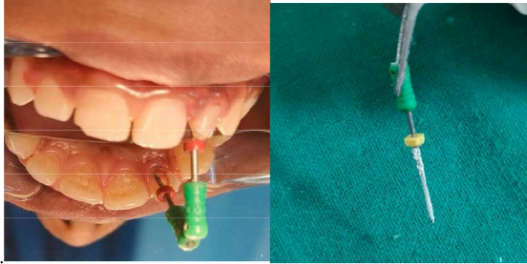


Figure4- Placement of sterile70K-file

Figure 5- 70 K-file coated with MTA

MTA (Angelus, Londrina, PR, Brazil) was taken and mixed according to the manufacturer's instruction. The file was coated with MTA and inserted into the canal to act as intracanal splint, sufficient amount of MTA was maintained around the file in canal. Moist cotton placed over MTA and temporary restoration applied. Patient recalled after 48 hours confirming the set of MTA followed by composite restoration.

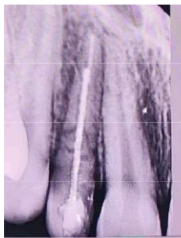

Figure 5 -Radiograph showing K-file coated with MTA and composite .

Follow up was done 6 months interval in which the tooth was asymptomatic to palpation, percussion and there was no mobility seen. In the radiographic examination showed normal width of periodontal space and hard tissue lining of fracture line.

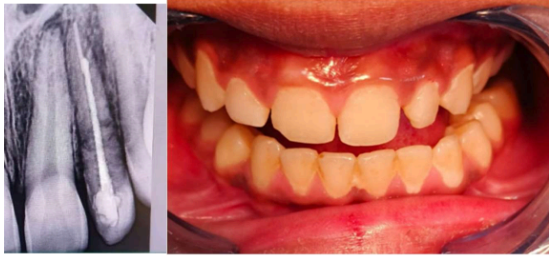

Fig 6- Follow up radiograph of 6 month

## DISCUSSION

This case report details the root canal treatment of a tooth with a horizontal root fracture. In such situations, after appropriate clinical management including repositioning and splinting, periodic follow-up is recommended without immediate root canal therapy.<sup>1</sup> Since the incidence of pulp necrosis in horizontal root fractures is slightly above 20%, it is generally advised to delay endodontic intervention unless clinical or radiographic signs indicate otherwise. Instead, regular clinical and radiographic monitoring is the preferred approach.<sup>4</sup>

Around 25% of adult patients with horizontal root fractures eventually experience permanent pulp necrosis in the coronal fragment, which necessitates root canal treatment.<sup>8</sup> In most cases, the apical fragment remains vital because its blood supply is typically not compromised, especially if the fragment has not been displaced.<sup>6</sup>

Successful treatment of a root-fractured tooth depends on timely intervention and regular evaluations. Understanding the healing patterns of root fractures is essential. The distance between the fractured segments (diastasis) significantly influences both healing and the likelihood of pulp necrosis. Teeth that receive proper treatment for horizontal root fractures generally have a favorable prognosis.<sup>9</sup>

In the present case, an endodontic instrument was used to stabilize the fractured root segments. Similar techniques involving a metal pin or a dental post passively placed in the canal along with endodontic cement have also been reported. Studies suggest that healing occurs more frequently when root canal treatment is limited to the coronal fragment rather than treating both fragments.<sup>8</sup>


Here, MTA (Mineral Trioxide Aggregate) was used to fill the root canal of the fractured tooth. Previous researchers have shown that MTA-filled canals demonstrate better fracture resistance, higher clinical and radiographic success, minimal signs of failure, increased hard tissue formation, and reduced inflammation compared to other filling materials.<sup>10,11</sup> For these reasons, MTA is often the material of choice in treating horizontal root fractures, as it can significantly improve treatment outcomes. This case report highlights a successful 6 months result using MTA in a horizontally fractured tooth with internal splinting.

## **1** **CONCLUSION**

In this case, the treatment of a horizontally fractured tooth was performed using intraradicular splinting with an endodontic file and MTA to seal the fracture line. The case illustrates that intraradicular splinting combined with MTA offers an alternative approach for managing horizontally fractured teeth with a necrotic and mobile coronal fragment.

## **REFERENCE**

1. Andreasen J. O., Andreasen F. M., Mej re I., Cvek M. Healing of 400 intra-alveolar root fractures. 1. Effect of pre-injury and injury factors such as sex, age, stage of root development, fracture type, location of fracture and severity of dislocation. Dental Traumatology. 2004;20(4):192–202.
2. Versiani MA, Sousa CJ, Cruz-Filho AM, Cruz-Perez DE, Sousa-Neto MA. Clinical management and subsequent healing of teeth with horizontal root fractures. Dental Traumatology 2008;24:136-139.
3. Caliskan MK, Pehlivan Y. Prognosis of root-fractured permanent incisors. Endod Dent Traumatol 1996;12:129-36.
4. Andreasen JO, Andreasen FM, Andersson L. Textbook and Color Atlas of Traumatic Injuries to the Teeth. 4th Edition. Oxford: Blackwell Munksgaard; 2007.
5. Feiglin B. Clinical management of transverse root fractures. Dent Clin North Am 1995;39:53-78.
6. Clark SJ, Eleazer P. Management of a horizontal root fracture after previous root canal therapy. Oral Surg Oral Med Oral Pathol Oral Radiol Endod 2000;89:220-3.
7. Bramante CM, Menezes R, Moraes IG, et al. Use of MTA and intracanal post reinforcement in a horizontally fractured tooth: a case report. Dent Traumatol 2006;22:275-8.
8. Cvek M., Mej re I., Andreasen J. O. Conservative endodontic treatment of teeth fractured in the middle or apical part of the root. Dental Traumatology. 2004;20(5):261–269.
9. Bramante C. M., Menezes R., Moraes I. G., Bernardinelli N., Garcia R. B., Letra A. Use of MTA and intracanal post reinforcement in a horizontally fractured tooth: a case report. Dental Traumatology. 2006;22(5):275–278.
10. Erdem A. P., Ozdas D. O., Dinc l E., Sepet E., Aren G. Case series: root healing with MTA after horizontal fracture. European Archives of Paediatric Dentistry. 2009;10(2):110–113.
11. Hatibovi -Kofman  ., Raimundo L., Zheng L., Chong L., Friedman M., Andreasen J. O. Fracture resistance and histological findings of immature teeth treated with mineral trioxide aggregate. Dental Traumatology. 2008;24(3):272–276.



# A Novel Approach in the treatment of Horizontal Root Fracture using K-File with MTA as an Intra-Radicular splint

## ORIGINALITY REPORT

44%

SIMILARITY INDEX

39%

INTERNET SOURCES

32%

PUBLICATIONS

1%

STUDENT PAPERS

## PRIMARY SOURCES

1

[archdent.org](http://archdent.org)

Internet Source

24%

2

[downloads.hindawi.com](http://downloads.hindawi.com)

Internet Source

7%

3

Mihee Kim, Sangho Lee, Nanyoung Lee.  
"Intentional Replantation of a Root-Fractured  
Tooth with Pulp Canal Obliteration", THE  
JOURNAL OF THE KOREAN ACADEMY OF  
PEDIATRIC DENTISTRY, 2016

Publication

2%

4

Reshma Chawla, Ushaina Fanibunda, Vibha  
Hegde. "A novel approach in the treatment of  
horizontal root fracture using self adjusting  
file with MTA as an intra-radicular splint",  
Journal of Pierre Fauchard Academy (India  
Section), 2015

Publication

2%

5

[jcd.org.in](http://jcd.org.in)

Internet Source

1%

6

N Arhun, A Arman, M Ungor, S Erkut. "A  
conservative multidisciplinary approach for  
improved aesthetic results with traumatised  
anterior teeth", British Dental Journal, 2006

Publication

1%

7

[pmc.ncbi.nlm.nih.gov](http://pmc.ncbi.nlm.nih.gov)

Internet Source

1%

8	<a href="http://www.annalsofdentalspecialty.net.in">www.annalsofdentalspecialty.net.in</a> Internet Source	1 %
9	<a href="http://datospdf.com">datospdf.com</a> Internet Source	1 %
10	Mahshid Sheikhnezami, Reza Shahmohammadi, Hamid Jafarzadeh, Amir Azarpazhooh. "Long-Term Outcome of Horizontal Root Fractures in Permanent Teeth: A Retrospective Cohort Study", Journal of Endodontics, 2024 Publication	1 %
11	<a href="http://www.ijdr.in">www.ijdr.in</a> Internet Source	1 %
12	Hsiao-Hua Chang. "Root fracture of immature permanent incisors - a case report", Dental Traumatology, 8/2006 Publication	1 %
13	<a href="http://www.iacde.in">www.iacde.in</a> Internet Source	1 %
14	Choi, Yoorina, Sung-Ok Hong, Seok-Ryun Lee, Kyung-San Min, and Su-Jung Park. "Healing after horizontal root fractures: 3 cases with 2-year follow-up", Restorative Dentistry & Endodontics, 2014. Publication	1 %
15	Kothandaraman Sathyanarayanan. "Endodontic management of horizontal root fractures in maxillary central incisors", European Journal of General Dentistry, 2021 Publication	<1 %
16	Michael M. Bornstein. "Comparison of intraoral radiography and limited cone beam computed tomography for the assessment of	<1 %

## root-fractured permanent teeth", Dental Traumatology, 12/2009

Publication

17

Sibel Kocak. "Intraradicular splinting with endodontic instrument of horizontal root fracture - case report", Dental Traumatology, 10/2008

Publication

<1 %

18

Wilson Roberto Poi. "Repair characteristics of horizontal root fracture: a case report", Dental Traumatology, 4/2002

Publication

<1 %

Exclude quotes On

Exclude matches Off

Exclude bibliography On