

Esthetic zone at risk: Successful endodontic management of internal root resorption in central incisor - A challenging endodontic case report

by Jana Publication & Research

Submission date: 21-Aug-2025 12:46PM (UTC+0700)

Submission ID: 2690335440

File name: IJAR-53449.docx (3.2M)

Word count: 2529

Character count: 14642

Esthetic zone at risk: Successful ¹³endodontic management of internal root resorption in central incisor - A challenging endodontic case report

⁸ABSTRACT

Internal root resorption (IRR) is a rare, progressive condition characterized by the loss of dentin and pulpal walls due to clastic cell activity ¹⁸within the root canal space. This case involves the ⁵maxillary right central incisor, presenting with asymptomatic radiolucency and confirmed via radiographic imaging. Early diagnosis is crucial for effective nonsurgical root canal treatment aimed at halting the resorptive process and preserving the tooth. ⁹This case report highlights the clinical features, diagnostic approach, and management strategies for IRR in an anterior maxillary tooth.

Keywords: ³Internal root resorption, mineral trioxide aggregate, root perforation, trauma.

INTRODUCTION

¹ Internal root resorption (IRR) is a rare dental condition in which the dentin within the root canal space is progressively resorbed due to inflammation within the pulp tissue. The exact cause of internal root resorption is not well understood. However, it is believed to occur due to infection, traumatic injury, or orthodontic treatment that damages the predentin and odontoblast layer. This damage exposes the mineralized dentin to elastic cells, leading to IRR, which can also progress and cause perforation.^[1,2] Early detection and management of IRR are important to prevent further destruction of the tooth structure and to ensure a better prognosis.^[3] The clinical manifestation of internal root resorption is typically asymptomatic and is frequently detected incidentally during routine radiographic examinations. It can be challenging to distinguish between IRR and external cervical resorption (ECR) based on their similar characteristics, which can create difficulties in two-dimensional radiograph analysis.^[4,5]

¹² Internal root resorption (IR) can occur most commonly in the middle third of the root canal^[6]. When IR is localized in the middle or apical third, it is typically asymptomatic⁸ due to the chronic inflammatory nature of the process, and the lesion is often detected incidentally during routine radiographic examination. However, if the resorption area is in the cervical third and the damage is advanced,³ the pink reflection from the granulation tissue facilitates the diagnosis. Also, pain or discomfort may be the chief complaint if the granulation tissue has been exposed to oral fluids.^[7]

Radiographically, internal resorption is seen as a round or oval, symmetrical, or sometimes even asymmetrically shaped radiolucent¹⁵ widening of the root canal with loss of canal outline. It should be differentiated from external resorption by tube shift technique or advanced imaging techniques like cone-beam computed tomography (CBCT).¹⁴ If left untreated, it can continue to expand, weakening the tooth, and may perforate the canal.¹ Treatment includes thorough debridement, cleaning, and disinfection of the entire canal space along with short-term intracanal medication like calcium hydroxide, and later in the absence of any clinical or radiographic manifestation, repair with a biomaterial like mineral trioxide aggregate (MTA),¹⁹ followed by obturation.^[7]

¹⁰ Cone-beam computed tomography (CBCT) is critical in determining the degree, distribution, and location of a lesion. However, due to a variety of factors such as financial constraints or lack of availability, CBCT is not always viable in all circumstances.^[7]

¹ For the treatment of IRR, root canal treatment (RCT) is necessary when the tooth can be saved or the prognosis is favorable. Like any tooth with infected pulp, RCT is performed to remove the intraradicular bacteria and disinfect the root canal space. In IRR cases, the root canal filling material must be flowable in order to adequately fill the irregular defects resulting from internal resorption.^[8]

⁴ The popularity of mineral trioxide aggregate (MTA) as an endodontic repair biomaterial can be attributed to several key factors, including its excellent sealing ability, superior marginal adaptation, and capacity to set in the presence of moisture and blood ^[9, 10]. In addition to numerous laboratory and animal studies, its biocompatibility and ability to induce hard tissue formation have been confirmed in human studies as well ^[11, 12]. MTA also promotes an environment favourable for periodontal healing, facilitating the deposition of new cementum on its surface. These advantageous properties make MTA a highly suitable material for managing tissue damage associated with inflammatory root resorption ^[13].

CASE REPORT

¹¹ A 22-year-old female patient presented with the chief complaint of fractured and discoloured tooth. (Fig-1a). ³ On the clinical and radiological examination, (Fig-1b), tooth #11 had fractured and deep caries reaching the pulp chamber and internal resorption (IR) in the middle third of the root. On clinical examination, there were no symptoms other than mild sensitivity on percussion test and the tooth ¹⁶ did not respond to sensibility tests (cold and electric pulp tests). ¹ No sinus tract was identified, and the periodontal condition was within normal parameters without any pocket depths exceeding 3 mm. Radiographic examination with periapical radiograph with different angulation showed a well-defined oval radiolucent area in the middle third of the root, extending continuously with the canal of tooth #11. After explaining the advantages, the patient was advised CBCT scanning but failed to give us any consent for the same. Patient was skeptical due to radiation. Hence, we had to opt CBCT out. The history revealed that the patient had trauma to the tooth about a year ago and that the tooth was fractured horizontally. The patient stated that she did not come for the treatment because she had no complaints those days other than caries. When history and examination were combined,

it was thought that IR was triggered by trauma¹ the lesion was diagnosed as a necrotic pulp with normal apical status and perforating internal root resorption.

Clinical Management

The patient's consent was obtained. A rubber dam was placed to isolate the tooth, after local anesthesia (2% lidocaine with 1/80000 Epinephrine; Daroupakhsh) root canal treatment was performed immediately using a fissure diamond bur and a high speed handpiece with water spray were used to prepare access cavity. Caries in the coronal part was completely cleaned and the access cavity was opened. The working length was determined using the Root ZX electronic apex locator (J. Morita, MFQ) and confirmed radiographically. X-ray images were used to verify the canal length with an ISO #20 K-type file. (Fig-1c) The root canal was instrumented with stainless steel hand files followed by irrigation with normal saline, 3% NaOCl (VIP, Vensons India) and 17% EDTA solution (DESMEAR; Anabond-Stedman). During and after canal shaping, 2 mL of 3% NaOCl (VIP, Vensons India) was delivered into the root canal, and the activation device was engaged for 20 seconds to agitate the solution using a Dental Ultra X Ultrasonic irrigation activator since it improves the debridement and disrupts the biofilm with cavitation and acoustic streaming. (Eighteenth, Changzhou, China). This cycle was repeated 3 times, after which a thorough rinse with saline was performed. Final irrigation was conducted with 17% EDTA (DESMEAR; Anabond-Stedman) to chelate any remaining debris. Canals were dried with sterile paper points and then the Ca(OH)₂ (Dentocal; Anabond-Stedman) was used as an intracanal dressing was placed by lentulo and cavity was temporarily restored with Cavit-G (3M ESPE, Germany) (Fig-1d) and the patient was recalled after 1 week.

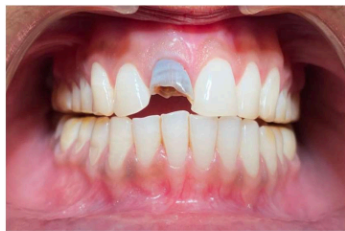
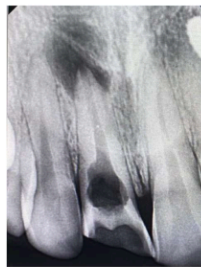
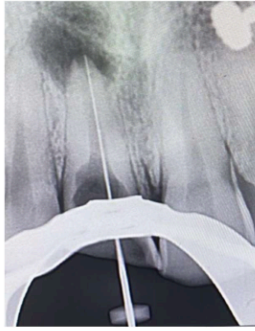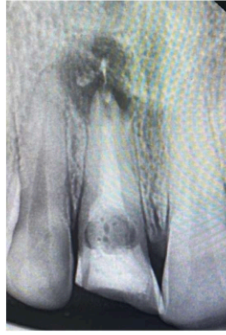Fig-1(a) Pre-operative extraoral



1(b) Pre-operative Radiograph



1(c) Working length determination



1(d) Ca(OH)2 dressing

One week later in the second visit, the tooth was asymptomatic, the Ca(OH)₂ (Dentocal; Anabond-Stedman) ¹ was removed by using ultra sonic agitation of a 17% EDTA irrigation solution (DESMEAR; Anabond-Stedman). After the final irrigation, the root canal was dried with sterile paper cones. Obturation was done with filling the entire canal with MTA putty (BioStructure MTA Putty) material (Fig-2a). ⁶ MTA was then gently condensed to the working length using an endodontic plugger (GDC). The procedure was repeated several times until the root canal was completely filled with MTA (Fig-2b). ⁷ A wet cotton pellet was placed on the MTA and the cavity was sealed temporarily sealed. After 2 days the temporary restoration was removed and ⁵ the access cavity was restored with GIC restoration (GC Gold Label 2 Glass Ionomer cement) (Fig-2c). After one month, the tooth was completely asymptomatic, tooth preparation was done and PFM crown was given to the patient (Fig-2d). ³ No clinical and radiographic findings were found after the 1 year follow-up examination

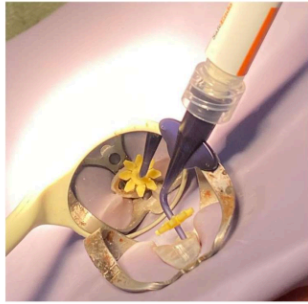
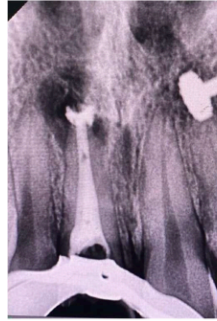
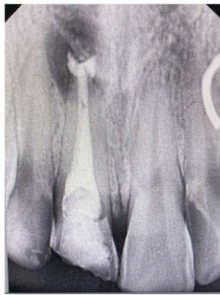
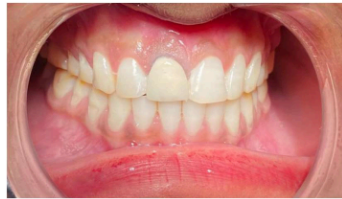Fig-2(a) MTA Putty placement



2(b) MTA filled till resorptive defect



2(c)
Radiograph showing complete obturation along
with sealed perforation



2(d) Final Crown Cementation

DISCUSSION

² Bell first reported a case on internal resorption in 1830, since then there have been numerous reports in the literature.^[14] Pathological root resorption leads to irreversible loss of tooth structure, and if the process is not stopped progression of resorption can may cause tooth loss. Diagnosis of root resorption depends on careful clinical and radiographic examination. Internal root resorption can occur as a potential consequence following trauma or can be associated with pulpal inflammation or infection. Resorption causes irreversible loss of tooth structure, and if not controlled, can result in perforation or even loss of the tooth.^[15] Achieving a complete debridement and disinfection of the canal system, control of the resorptive process and

attaining an impervious seal are challenges often faced during the management of internal resorption.^[16, 17]

Etiology of internal resorption reported was related to a history of trauma. Diagnosis was made based on history and radiographic findings. Internal resorption requires an emergency endodontic care with immediate pulp extirpation and debridement, which can arrest the cellular activity responsible for resorption.^[18] Calcium hydroxide medicament was used to dissolve the necrotic pulp tissue and to alkalize the environment.^[8]

The chemical disinfection involves the use of different concentrations of sodium hypochlorite to disinfect the canal and dissolve the granulation tissue. Calcium hydroxide used as an intracanal medicament also helps to disinfect and dissolve any remaining granulation tissue. Both 3% sodium hypochlorite and calcium hydroxide were used in the present case. If proper treatment protocol is followed, remineralisation of the resorptive defect and formation of hard tissue matrix may be observed. In present case MTA was used for remineralisation of the defect.^[19]

In the present case endodontic management of the resorptive defect involved thorough chemo-mechanical preparation with gentle instrumentations to preserve the root dentin thickness. Irrigants were agitated with endoactivator for thorough removal of necrotic debris from resorptive defect. To achieve proper disinfection and cessation of osteoclastic activity calcium hydroxide intracanal medicament was placed within canal. It has been shown to eradicate bacteria and enhance the effect of sodium hypochlorite in removing organic debris from the root canal system^[20, 21]. Therefore, it is advisable to use calcium hydroxide as an intracanal, antibacterial medicament alongside conventional root canal treatment. To induce remineralisation and fill the internal resorptive defect bioactive material i.e. MTA was used. It was followed by post endodontic restoration with GIC. Later, PFM crown was luted to the prepared tooth to enhance the aesthetics.

Calcium hydroxide was used as an intracanal medicament as it maximizes the effect of disinfection procedures, helps to control bleeding, necrotizes the residual pulp tissue and dissolves any remaining granulation tissue. It also enhances the cessation of osteoclastic activity.

It was preferred to fill the root canal completely with MTA, because MTA is a biocompatible material because of its excellent biocompatibility, sealing ability, regenerative potential and single visit application. Also MTA is very well tolerated by the tissues.^[22] MTA has also

demonstrated encouraging results in therapeutic applications for mending perforations in the presence of moisture and preventing bacterial activity.^[23]

It has been shown that MTA obturation can also cause release of calcium ions through dentinal tubules into resorption defects, which may favor the repair potential of the surrounding tissues. Moreover, MTA preferentially induces alkaline phosphatase expression and activity in periodontal ligament fibroblasts^[24, 25].

CONCLUSION

For successful treatment outcome early diagnosis, removal of the cause, proper treatment of the resorptive defect of tooth is mandatory. The diagnosis of internal inflammatory root resorption is made through a combination of clinical and radiographic findings in daily practice. Modern endodontic techniques including optical aids and ultrasonic improvement of chemical debridement should be used during the root canal treatment of internally resorbed teeth. Alternative materials such as calcium silicate cements like MTA offer new opportunities and better prognosis for the rehabilitation of resorbed teeth.

REFERENCES

1. Tronstad L. Root resorption – etiology, terminology and clinical manifestations. *Dental Traumatology*. 1988;4(6):241-52.
2. Andreasen J, Andreasen F. Root resorption following traumatic dental injuries. *Proc Finn Dent Soc*. 1992;88:95-114.
3. Çalışkan M, Türkün M. Prognosis of permanent teeth with internal resorption: A clinical review. *Endod Dent Traumatol*. 1997;13(2):75-81.
4. Gulabivala K, Searson L. Clinical diagnosis of internal resorption: An exception to the rule. *Int Endod J*. 1995;28(5):255-60.
5. Lyrroudia KM, Dourou VI, Pantelidou OC, et al. Internal root resorption studied by radiography, stereomicroscope, scanning electron microscope and computerized 3D reconstructive method. *Dent Traumatol*. 2002;18(3):148-52.
6. Ne RF, Witherspoon DE, Gutmann JL. Tooth resorption. *Quintessence Int* 1999;30:9–25.
7. Haapasalo M, Endal U. Internal inflammatory root resorption: The unknown resorption of the tooth. *Endod Top* 2006;14:60-79.
8. Jacobovitz M, de Lima RK. Treatment of inflammatory internal root resorption with mineral trioxide aggregate: a case report. *Int Endod J*. 2008;41(10):905-912.
9. Al-Kahtani A, Shostad S, Schifferle R, Bhambhani S. In-vitro evaluation of microleakage of an orthograde apical plug of mineral trioxide aggregate in permanent teeth with simulated immature apices. *J Endod* 2005;31:117–9.
10. Vanderweele RA, Schwartz SA, Beeson TJ. Effect of blood contamination on retention characteristics of MTA when mixed with different liquids. *J Endod* 2006;32:421–4.

11. Holden DT, Schwartz SA, Kirkpatrick TC, Schindler WG. Clinical outcomes of artificial root-end barriers with mineral trioxide aggregate in teeth with immature apices. *J Endod* 2008;34:812–7.
12. Witherspoon DE, Small JC, Regan JD, Nunn M. Retrospective analysis of open apex teeth obturated with mineral trioxide aggregate. *J Endod* 2008;34:1171–6.
13. Torabinejad M, Chivian N. Clinical applications of mineral trioxide aggregate. *J Endod* 1999;25:197–205.
14. Bell T. The anatomy, physiology, and disease of the teeth; 1830. p. 171–2
15. Agrawal VS, Kapoor S. Management of root canal stenosis and external inflammatory resorption by surgical root reconstruction using biodentine. *J Conserv Dent* 2020;23:102–6.
16. Patel S, Ricucci D, Durak C, Tay F. Internal root resorption: A review. *J Endod* 2010;36:1107–21. 12. 13. 14. 15. 16.
17. Li FC, Hung WC. Repair of a perforating internal resorption: Two case reports. *J Dent Sci* 2016;11:338–42.
18. Trope M. Root resorption due to dental trauma general principles. *Endod Top* 2002;1:79–100.
19. Economides N, Pantelidou O, Kokkas A, Tziafas D. Short-term periradicular tissue response to mineral trioxide aggregate (MTA) as root-end filling material. *Int Endod J*. 2003;36(1):44–8.
20. Sjögren U, Figdor D, Spångberg L, Sundqvist G. The antimicrobial effect of calcium hydroxide as a short-term intracanal dressing. *Int Endod J*. 1991;24(3):119–25
21. Byström A, Claesson R, Sundqvist G. The antibacterial effect of camphorated paramonochlorophenol, camphorated phenol and calcium hydroxide in the treatment of infected root canals. *Endod Dent Traumatol*. 1985;1(5):170–75
22. Ford TR, Torabinejad M, McKendry DJ, Hong CU, Kariyawasam SP. Use of mineral trioxide aggregate for repair of furcal perforations. *Oral Surg Oral Med Oral Pathol Oral Radiol Endod* 1995;79:756–63.
23. Arens DE, Torabinejad M. Repair of furcal perforations with mineral trioxide aggregate: Two case reports. *Oral Surg Oral Med Oral Pathol Oral Radiol Endod* 1996;82:84–8.
24. Ozdemir HO, Ozelik B, Karabucak B, Cehreli ZC. Calcium ion diffusion from mineral trioxide aggregate through simulated root resorption defects. *Dent Traumatol* 2008;24:70–3. 2
25. Guven G, Cehreli ZC, Ural A, Serdar MA, Basak F. Effect of mineral trioxide aggregate cements on transforming growth factor beta1 and bone morphogenetic protein production by human fibroblasts in vitro. *J Endod* 2007;33:447–50.

Esthetic zone at risk: Successful endodontic management of internal root resorption in central incisor - A challenging endodontic case report

ORIGINALITY REPORT

69%

SIMILARITY INDEX

67%

INTERNET SOURCES

45%

PUBLICATIONS

3%

STUDENT PAPERS

PRIMARY SOURCES

1	www.ncbi.nlm.nih.gov Internet Source	24%
2	innovpub.org Internet Source	20%
3	jag.journalagent.com Internet Source	11%
4	Irem Güzeler. "Management of trauma-induced inflammatory root resorption using mineral trioxide aggregate obturation: two-year follow up : Management of trauma-induced inflammatory root resorption", Dental Traumatology, 12/2010 Publication	5%
5	zombiedoc.com Internet Source	2%
6	jcda.ca Internet Source	1%
7	Zhu, W.H.. "Endodontic treatment with MTA of a mandibular first premolar with open apex: case report", Oral Surgery, Oral Medicine, Oral Pathology, Oral Radiology and Endodontology, 200807 Publication	1%
8	journals.mu-varna.bg Internet Source	1%

9	lumhs.edu.pk Internet Source	1 %
10	B. Bhuva. "The use of limited cone beam computed tomography in the diagnosis and management of a case of perforating internal root resorption : CASE REPORT", International Endodontic Journal, 08/2011 Publication	<1 %
11	Gracemol Raju, H.C Baranwal. "Non-surgical management of simultaneous occurrence of internal root resorption and calcific metamorphosis: A case report", IP Indian Journal of Conservative and Endodontics, 2024 Publication	<1 %
12	Sari, S.. "Internal Resorption Treated with Mineral Trioxide Aggregate in a Primary Molar Tooth: 18-Month Follow-Up", Journal of Endodontics, 200601 Publication	<1 %
13	ijsr.in Internet Source	<1 %
14	studybam.com Internet Source	<1 %
15	Rui Pereira da Costa, Sérgio André Quaresma, Fabiane Carneiro Lopes, Rafael Camargo et al. "Management of a perforating internal root resorption using mineral trioxide aggregate: a case report with 5-year follow-up", Australian Endodontic Journal, 2020 Publication	<1 %
16	dentjods.sums.ac.ir Internet Source	<1 %

18 Farhad, Ali Reza, Ali Shokrane, and Neda Shekarchizade. "Regeneration or replacement? A case report and review of literature", Dental Traumatology, 2015.

Publication

19 "The Guidebook to Molar Endodontics", Springer Science and Business Media LLC, 2017

Publication

Exclude quotes On

Exclude matches Off

Exclude bibliography On