

A Tale Of Migrating Foreign Body

by Jana Publication & Research

Submission date: 23-Aug-2025 11:56AM (UTC+0700)

Submission ID: 2690325023

File name: IJAR-53482.docx (592.7K)

Word count: 1199

Character count: 6359

A Tale Of Migrating Foreign Body

3 Introduction:

Intraluminal removal of ingested foreign bodies has been documented as far back as 500 BC, with one of the earliest anecdotal accounts found in Aesop's fables. In the tale, a crane inserts its head into the mouth of a predatory animal often depicted as a wolf or lion to extract a bone lodged in the animal's throat following a hasty meal (1). Ingested foreign bodies still remain one of the commonest ENT emergencies of which fish bones are the commonest. They account for more than 85% of all the foreign bodies (2). Fortunately, these foreign bodies can be removed with less morbidity. However, some of these can pass through a mucosal surface, which heals over, and then migrate within the soft tissues of the neck to present at a distant location after a prolonged interval. Hereby we present a rare case in which the fish bone was found within the superior pole of thyroid.

CASE:

A 52-year-old male patient presented in our department with complaints of accidental ingestion of fish bone 10 days back. Following this, the patient swallowed a bolus of rice in attempt to dislodge the foreign body. However, he still had persistent foreign body sensation in throat. On examination his general condition was satisfactory. Vitals were well maintained. Oral cavity and oropharynx examination was normal. Indirect laryngoscopy and video laryngoscopy did not reveal any pooling of saliva, foreign body, oedema, or any congestion. Neck movements were painless. There was no sign of trauma, swelling, or tenderness and laryngeal crepitus was present. Systemic examination was essentially normal. Suspecting a foreign body, an X-ray of the soft tissue neck lateral view was done which showed no foreign body. Because of the persistent complaints of pain on the right-side of neck, we doubted the extraluminal migration of the foreign body. To know the exact location of the foreign body a contrast-enhanced CT scan of neck was done. It showed a small 3.5*2.3*1.8cm sized abscess in right pharyngeal space along the posterolateral aspect of the right thyroid cartilage and the abscess was seen extending to upper pole of right lobe of thyroid. A linear hyperdense 2.3 cm long foreign body/ fish bone was noted within the abscess cavity.

We then planned a neck exploration via external approach under general anaesthesia. A horizontal incision was made at the level of superior border of thyroid cartilage in the right side of neck. Dissection was done in the subplatysmal plane. Superior pole of thyroid was identified. Blackish discolouration was seen at the superior pole. On opening up this area, pus was seen draining out of the cavity. As per the CT findings, the fish bone had to be present within this abscess cavity. A thorough wash with betadine was given and the fish

bone was identified and carefully removed. A 12 no. drain was fixed and suturing was done in layers. Postoperative period was uneventful. Drain was removed on postoperative day 3.

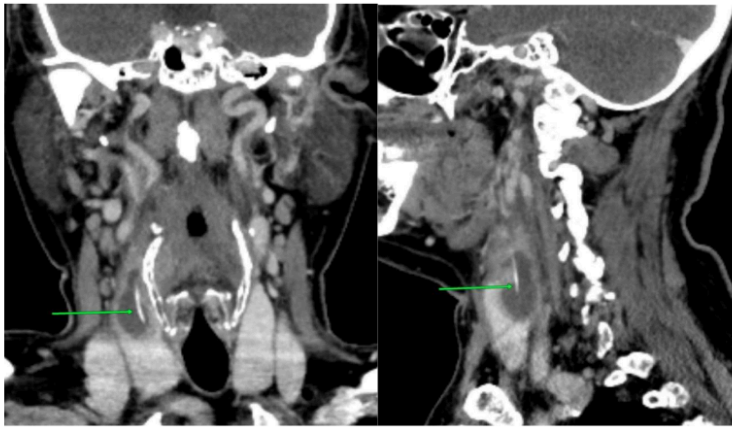


Fig:01

Fig:02

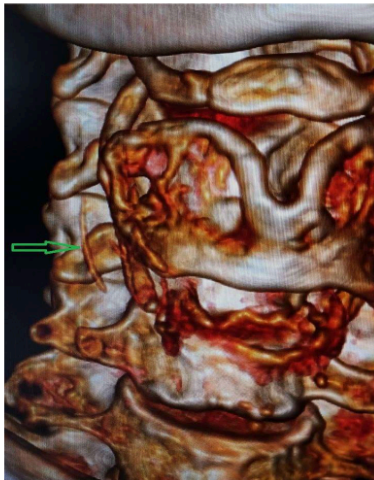


Fig:03

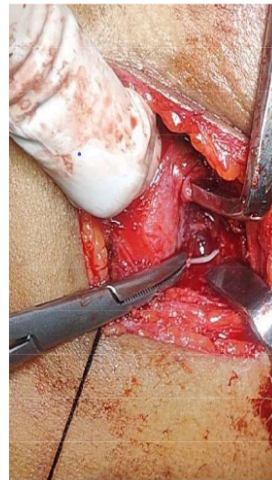


Fig:04

Discussion:

Ingested foreign bodies are more commonly lodged in the tongue base, tonsils or the vallecula and are easily removed in the clinical setting. Rarely, a foreign body may penetrate the oesophageal mucosa and migrate into the soft tissues of the neck, likely due to a combination of oesophageal peristalsis and cervical movement. These migrated foreign bodies can remain asymptomatic, extrude through the skin, or lead to serious complications such as deep neck abscess, carotid artery injury, internal jugular vein thrombophlebitis, or thyroid gland embedment. The incidence of extraluminal migration resulting in a neck abscess is estimated to be less than 1% (3). In 1949 Jemerin and Aronoff were the first to report a migratory foreign body in the thyroid gland (3).

In a series by Goh and Tan, four cases of fish bone migration into the thyroid gland were successfully managed via neck exploration, with only one case requiring thyroid lobectomy (4).

Arumainathan et al (5) reported the first case in which the fish bone lodged in the thyroid was removed without the need to remove the entire gland in 2000. They have also stated that, before their case report, there were only five reported cases of migratory fish bone in the thyroid and all of them were found in the left lobe. In all these cases, a lobectomy was performed because of the abscess on the thyroid and inflammation of the surrounding area.

The primary challenge lies in accurately localizing the foreign body within the soft tissues.

Once identified, removal is typically straightforward. X-rays can be misleading due to calcification of upper airway cartilages or if the foreign body is radiolucent. Contrast enhanced computed tomography (CECT) of neck is the investigation of choice as it not only forms a road map for surgery, but also gives essential information like accurate size of the foreign body, its orientation and relationship with surrounding structures. However, the position of the foreign body during surgery may differ from its location on preoperative CT imaging, due to the mobility of neck soft tissues relative to the underlying bony and cartilaginous structure (6). A C-arm can also be used intraoperatively in case of difficulty in localising the foreign body.

Al Muhanna (7) et al. reported a case in which repeated esophagoscopy failed to identify a foreign body in a patient presenting with painful dysphagia. Subsequent CT imaging revealed a fish bone embedded in the right thyroid lobe.

Sethi and Stanley (8) reported two cases of fish bones penetrating the esophageal wall and emphasized that CT scan is the most effective modality for precise localization of migrated foreign bodies.

Conclusion:

Exploration for a migrated foreign body is like searching for a needle in a haystack, often presenting a significant therapeutic dilemma due to the potential for serious complications.

The longer a foreign body remains impacted, the greater the risk of adverse outcomes, hence the importance of timely diagnosis and intervention. In symptomatic patients, a normal endoscopic evaluation should raise suspicion for a migrated foreign body. CT scan is essential in localising the foreign body. Utilizing CT to guide a systematic external exploration of the neck enhances the accuracy of the procedure, reduces the risk of unsuccessful surgical attempts, and minimizes the potential for serious, life-threatening complications.

References:

- 1) Jackson CL. Ancient foreign body cases. *Laryngoscope* 1917; 27:583-4.
- 2) Chee LW, Sethi DS. Diagnostic and therapeutic approach to migrating foreign bodies. *Annals of Otolaryngology, Rhinology & Laryngology*. 1999 Feb;108(2):177-80.
- 3) Das SK, Das C, Chatterjee P, Sen S, Vasamsetty VP. Migratory Foreign Body Presenting with Thyroid Abscess. *Bengal Journal of Otolaryngology and Head Neck Surgery*. 2021 Sep 27;29(2):200-3.
- 4) Goh YH, Tan NG. Penetrating oesophageal foreign bodies in the thyroid gland. *J Laryngol Otol*. 1999;113:769-71
- 5) Arumainathan UD, Lwin S, Suan TL, Raman R. Removal of a fish bone in the thyroid gland without the need for thyroid lobectomy. *Ear, nose & throat journal*. 2000 Apr;79(4):314-5.
- 6) Kotecha JK. Fish Bone Migrating into the Thyroid Gland. *International Journal of Head and Neck Surgery*. 2015 Sep 1;5(1):42-4.
- 7) Muhanna AA, Abu Chra KA, Dasti H, Behbehani A, Al-Naqeeb N. Thyroid lobectomy for removal of a fish bone. *J Laryngol Otol* 1990;104:511-512.
- 8) Sethi DS, Stanley RE. Migrating foreign bodies in the upper digestive tract. *Ann Acad Med Singapore* 1992;21(3):390-393

A Tale Of Migrating Foreign Body

ORIGINALITY REPORT

35%

SIMILARITY INDEX

24%

INTERNET SOURCES

33%

PUBLICATIONS

0%

STUDENT PAPERS

PRIMARY SOURCES

- | | | |
|---|---|-----|
| 1 | www.ijhns.com
Internet Source | 11% |
| 2 | www.researchgate.net
Internet Source | 4% |
| 3 | Kenneth Remsen, Hugh F. Biller, William Lawson, Max L. Som. "Unusual Presentations of Penetrating Foreign Bodies of the Upper Aerodigestive Tract", Annals of Otology, Rhinology & Laryngology, 2016
Publication | 4% |
| 4 | www.ncbi.nlm.nih.gov
Internet Source | 3% |
| 5 | GM Divya, Hasif Muhammad, KC Ramachandran, K Shiji. "Vertical Cricoid Lamina Ossification: A Rare Pitfall in the Diagnosis of Extraluminal Foreign Body", International Journal of Head and Neck Surgery, 2014
Publication | 1% |
| 6 | Hohman, M. H., W. J. Harsha, and K. L. Peterson. "Migration of Ingested Foreign Bodies into the Thyroid Gland: Literature Review and Case Report", Annals of Otology Rhinology & Laryngology, 2010.
Publication | 1% |
| 7 | Mohsin Ahmed Abdul Nabi Shaikh, Ankit Dilip Mahuvakar, Atish Balajirao Gujrathi, | 1% |

Vijayalaxmi Kishanrao Ambulgekar. "An Ingested Foreign Body Presenting in Subcutaneous Plane on the Chest: A Rare Case", An International Journal of Otorhinolaryngology Clinics, 2013

Publication

8

Usha D. Arumainathan, Saw Lwin, Tan Lye Suan, R. Raman. "Removal of a Fish Bone in the Thyroid Gland without the Need for Thyroid Lobectomy", Ear, Nose & Throat Journal, 2019

Publication

1 %

9

omjournal.org

Internet Source

1 %

10

Tae-Hun Lee, Sang-Wook Park, Somi Ryu, Ki Ju Cho, Seong Jun Won, Jung Je Park. "Two cases of extraluminal migration of fishbones into the thyroid gland and submandibular gland", Ear, Nose & Throat Journal, 2022

Publication

1 %

11

bmcsurg.biomedcentral.com

Internet Source

1 %

12

ecommons.aku.edu

Internet Source

1 %

13

www.scribd.com

Internet Source

1 %

14

Anita M. Thomas, Basharat Nadeem, H. C. Badaridatta. "Migrated Foreign Body Neck", Journal of Case Reports in Medicine, 2012

Publication

1 %

15

S.S. Sreetharan, Narayanan Prepageran, Satwant Singh. "Migratory Foreign Body in the Neck", Asian Journal of Surgery, 2005

1 %

16

Goh, Y.H.. "An unusual neck lump", Journal of Pediatric Surgery, 200007

Publication

1 %

17

Ramanuj Sinha, Indranil Sen, Jayanta Saha, Ankur Mukherjee, Ruma Guha. "Migration of a Fish Bone from the Upper Aerodigestive Tract to the Skin of the Neck: A Case Report", Ear, Nose & Throat Journal, 2019

Publication

1 %

Exclude quotes On

Exclude matches Off

Exclude bibliography On