

Adnexal torsion and pregnancy: a case report and review of the literature

by Jana Publication & Research

Submission date: 25-Aug-2025 11:34AM (UTC+0700)

Submission ID: 2690327030

File name: IJAR-53520.docx (1.54M)

Word count: 1926

Character count: 11445

1 Adnexal torsion and pregnancy: a case report and review of the literature

Abstract :

Adnexal torsion during pregnancy is a rare but critical surgical emergency, particularly challenging when it occurs on the left side. Its non-specific presentation can delay diagnosis and jeopardize both ovarian function and pregnancy viability. Although prompt surgical intervention is crucial, conservative approaches are increasingly favored to preserve fertility and hormonal function. This report describes a rare case of left ovarian torsion in a 23-year-old primigravida at 7 weeks of gestation, caused by a large serous cystadenoma. Diagnosis was confirmed by ultrasound and MRI, and urgent laparotomy revealed a viable ovary despite torsion. The patient underwent detorsion, cystectomy, and ovariopexy, followed by vaginal progesterone supplementation for luteal support. Pregnancy progressed uneventfully to term with the birth of a healthy infant. This case highlights the value of conservative surgical management, the importance of timely imaging, and the potential role of adjunctive progesterone therapy. Further studies are needed to optimize the diagnosis, management, and long-term outcomes of adnexal torsion in pregnancy.

Introduction:-

Adnexal torsion during pregnancy is an uncommon condition, most commonly manifesting in the first two trimesters. Torsion is defined as a complete turn of the adnexa on the axis formed by the utero-ovarian and tubo-ovarian ligaments. It can involve both the ovary and the fallopian tube, the ovary alone, or, less commonly, the fallopian tube alone. Conditions such as adnexal masses or ovarian hyperstimulation (which can lead to cyst formation) increase the risk of torsion.

Clinical diagnosis is challenging due to the non-specific nature of the symptoms, especially in advanced pregnancies where the ovary may ascend, resembling other surgical emergencies like acute appendicitis, cholecystitis, or pyelonephritis.

Pelvic ultrasound and MRI are still the most important diagnostic tools for this condition, helping to make the correct assessment and eliminating the majority of differential diagnoses.

The final diagnosis is made at the time of surgery, but complications such as the induction of uterine contractions and compromising pregnancy viability should be considered before performing any pelvic surgery. This article presents a case of adnexal torsion diagnosed during the first trimester of pregnancy.

2 Case report :-

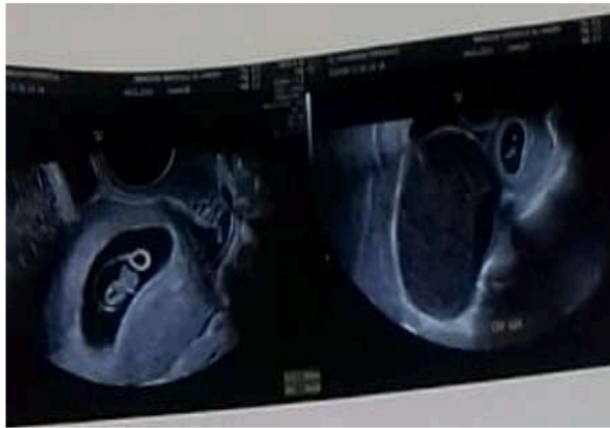We report the case of a 23-year-old primiparous patient with no notable medical antecedents, a history of regular menstrual cycles, and no prior use of contraception. She presented to the obstetric emergency department at 7 weeks of gestation with acute, continuous left iliac fossa pain, which had persisted for 48 hours. The patient reported sudden-onset high-intensity pain radiating to the back. On examination, the patient was alert and oriented to time and place, with stable vital signs, though exhibiting signs of distress. The abdominal examination revealed tenderness in the left iliac fossa, without signs of peritoneal defense or rigidity. A speculum examination revealed a gravid cervix. On vaginal examination, a long posterior cervix was observed, closed and with no discharge. The uterus appeared enlarged, while the right adnexa showed no abnormalities. Tenderness was noted in the left vaginal fornix, the remaining examination findings being unremarkable.

Given the patient's clinical presentation, an ultrasound was performed, revealing a pregnant uterus with a gestational sac measuring 7 weeks and 3 days, with a visible embryo and detectable cardiac activity. A large cystic structure measuring 9 cm in diameter was observed in the left ovary, well-defined, thin-regular walls, unilocular, with no detectable blood flow on Doppler examination (Fig1).

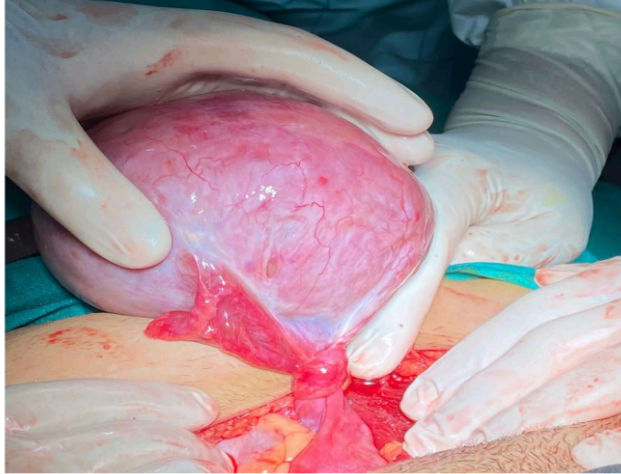
MRI was subsequently conducted, confirming the diagnosis of left-sided adnexal torsion. An ovarian cyst measuring 9 cm in diameter was observed, with features suggestive of a serous cystadenoma. The ovarian parenchyma appeared edematous.

An urgent exploratory laparotomy was performed due to the unavailability of laparoscopic equipment. Preoperative laboratory tests, including complete blood count, blood typing, and coagulation studies, were within normal limits. During surgery, a twisted left ovarian cyst was identified, with no evidence of ischemia. The uterus was enlarged, while the right adnexa appeared normal. Detorsion of the left ovary was performed, followed by a 10-minute immersion in warm saline to promote tissue reperfusion. The cyst was subsequently excised via cystectomy, and an ovariopexy was performed to reduce the risk of recurrence.

Postoperatively, tocolysis was initiated using intravaginal progesterone (40 µg/day) for six weeks to prevent preterm labor. The patient's recovery was uneventful, and her pregnancy progressed without complications. She delivered a healthy male infant weighing 3,200 grams at 40 weeks of gestation.



Figure(1):-Ultrasound imaging of a progressive intrauterine pregnancy associated with a large cystic formation in the left ovary.



Figure(2):-Twisted non-ischemic left adnexa with one spiral turn.

11 Discussion:-

Adnexal torsion during pregnancy is a rare but potential⁹ serious condition, occurring in approximately 3 to 5 per 10,000 pregnancies [2,3]. It is most frequently observed in the first trimester, though it can present at any stage of pregnancy [4,5]. Torsion is often associated with pathological ovaries, including benign or malignant tumors, corpus luteum cysts, or cysts resulting from ovarian hyperstimulation—particularly follicular cysts, hemorrhagic cysts, teratomas, and cystadenomas [6]. The risk of torsion¹⁸ increases with cyst size, especially when it exceeds 5 cm [7]; in our patient, the ovarian cyst measured 9 cm. Ovarian torsion occurs more commonly on the right¹³ side, likely due to reduced mobility of the left adnexa from partial adhesion to the mesosigmoid, hypermobility of the cecum and terminal ileum on the right, and the physiologic¹⁷ longer right utero-ovarian ligament. Thus, our case was unusual, as the torsion involved the left ovary. In the early stages of torsion, lymphatic drainage is compromised, resulting in ovarian enlargement due to edema, followed by venous congestion and hemorrhagic infarction. Complete arterial obstruction can ultimately lead to ovarian necrosis [8].

Diagnosing ovarian¹⁹ torsion is particularly difficult during pregnancy due to the lack of specific clinical signs. Acute, localized abdominal pain is the most common presenting symptom of adnexal torsion [9]. However, the pain may vary in intensity and characteristics, making diagnosis challenging.

3
Ultrasound remains the diagnostic gold standard for evaluating adnexal torsion. While it is limited in its ability to definitively diagnose torsion, it helps exclude other differential diagnoses and assess for indirect signs of ischemia, such as ovarian enlargement. Although Doppler ultrasonography is useful for detecting absent blood flow, the presence of a Doppler signal does not rule out adnexal torsion [10].

MRI, which is often employed as a complementary technique, provides more accurate imaging, particularly in pregnant patients, and is increasingly useful in confirming the diagnosis of torsion [1]. Combining Doppler and MRI offers enhanced diagnostic sensitivity, although these methods should not delay surgical intervention in cases

of suspected torsion. In our case, imaging confirmed an intrauterine pregnancy at 7 weeks and 3 days with positive cardiac activity. A 9 cm unilocular, thin-walled left ovarian cyst without Doppler flow was identified on ultrasound, and MRI findings were consistent with left adnexal torsion, likely due to a serous cystadenoma with associated stromal edema.

Treatment for adnexal torsion is mostly a detorsion, preserving ovarian function. In cases where the ovary appears non-viable, oophorectomy or adnexectomy may be necessary. However, conservative management with detorsion remains the preferred approach, as ovarian tissue has a significant capacity for functional recovery, even after ischemic injury [11]. Fear of complications such as thromboembolic events during detorsion is theoretical, and there is currently no strong evidence to support the routine use of radical treatment in such cases [7,12]. Recent studies advocate for conservative management of even necrotic ovaries, as the macroscopic appearance does not always correlate with the degree of ischemia [13]. Functional recovery of ovarian tissue after torsion has been demonstrated, with preservation rates ranging from 88 to 100% [14].

Ovariopexy involves securing the ovarian end of the uterine ovarian ligament to the posterior surface of the broad ligament using a crimped non-absorbable suture, aiming to prevent recurrence of adnexal torsion by shortening the utero-ovarian ligament and reducing ovarian laxity. Recognized indications include recurrent torsion (particularly on the same side), torsion during pregnancy [15], torsion in premenarchal or adolescent patients, torsion of a normal ovary without an underlying mass, anatomical predisposition such as elongated utero-ovarian ligament. Given the recurrence risk approaching 20% during pregnancy [15], we elected to perform an ovariopexy in this patient.

In our case, given the surgical detorsion of the adnexa during early pregnancy and the potential compromise of luteal function, we initiated vaginal micronized progesterone at a dose of 400 mg twice daily. This approach is supported by the 2021 NICE guidelines, which recommend progesterone supplementation in early pregnancy until 16 weeks into pregnancy for women at risk of miscarriage, based on findings from the PRISM trial and other systematic reviews [16], [17].

Conclusion:-

Adnexal torsion during pregnancy presents significant diagnostic challenges, with non-specific clinical features and limited diagnostic tools. However, imaging plays a crucial role in excluding differential diagnoses and identifying adnexal pathology. Surgical intervention should be conservative, with detorsion as the primary goal.

The prognosis for pregnancy is generally positive, although preterm delivery and miscarriage may occur, especially if the corpus luteum is removed during surgery. Preventive tocolysis and careful monitoring are essential for ensuring the best maternal and fetal outcomes.

Acknowledgements:-

Special thanks to the team of the Gynecology and Obstetrics Department of Mohammed VI University Hospital in Tangier.

Competing interests

Authors have declared that no competing interest exists.

References:-

- [1] Mage G, Canis M, Manhes H, Pouly JL, Bruhat MA. Laparoscopic management of adnexal torsion: A review of 35 cases. *J Reprod Med*. 1989;34:520–4.
- [2] Zanetta G, Mariani E, Lissoni A et al. A prospective study of the role of ultrasound in the management of adnexal masses in pregnancy. *BJOG*. 2003;110(6):578–83.
- [3] Kumari I, Kaur S, Mohan H et al. Adnexal masses in pregnancy: a 5-year review. *Aust N Z J ObstetGynaecol*. 2006;46(1):52–4.
- [4] Oelsner G, Cohen SB, Soriano D et al. Minimal surgery for the twisted ischaemic adnexa can preserve ovarian function. *Hum Reprod*. 2003;18(12):2599–602.
- [5] Boughizane S, Naifer R, Hafsa A et al. Laparoscopic management of adnexal tumours after the first trimester of pregnancy. *J GynecolObstet Biol Reprod*. 2004;33(4):319–22.
- [6] Cass DL. Ovarian torsion. *Semin Pediatr Surg*. 2005;14(2):86–92.
- [7] Grapin-Dagorno C, Chabaud M. Kystes et tumeurs de l'ovaire avant la puberté: aspects chirurgicaux. *Arch Pediatr*. 2008;15(5):786–8.
- [8] Erdemoglu M, Kuyumcuoglu U, Kale A. Pregnancy and adnexal torsion: analysis of 20 cases. *Clin Exp Obstet Gynecol*. 2010;37(3):224–5.
- [9] Kao J-K, Chiu C-C, Wang P-Y, Yu M-K. Pediatric ovarian torsion in a medical centre in Taiwan: case analysis. *PediatrNeonatal*. 2012;53(1):55–9.
- [10] Abu-Musa A, Nassar A, Usta I et al. Laparoscopic unwinding and cystectomy of twisted dermoid cyst during second trimester of pregnancy. *J Am Assoc GynecolLaparosc*. 2001;8(3):456–60.
- [11] Schmeler KM, Mayo-Smith WW, Peipert JF, Weitzen S, Manuel MD, Gordinier ME. Adnexal masses in pregnancy: surgery compared with observation. *Obstet Gynecol*. 2005;105(5):1098-1103. PubMed | Google Scholar
- [12] Crouch NS, Gyampoh B, Cutner AS, Creighton SM. Ovarian torsion: to pex or not to pex? *J PediatrAdolesc Gynecol*. 2003;16(6):381–4.
- [13] Cohen SB, Wattiez A, Seidman DS, Goldenberg M, Admon D, Mashiach S et al. Laparoscopy versus laparotomy for detorsion and sparing of the twisted ischemic adnexa. *JSLs*. 2003;7(4):295. PubMed | Google Scholar
- [14] Huchon C, Fauconnier A. Adnexal torsion: a literature review. *Eur J ObstetGynecolReprod Biol*. 2010;150(1):8–12.
- [15] Hasson J, Tsafir Z, Azem F et al. Comparison of adnexal torsion between pregnant and non pregnant women. *Am J ObstetGynecol* 2010;202(6):536.e1-6
- [16] National Institute for Health and Clinical Excellence. Ectopic pregnancy and miscarriage: diagnosis and initial management. NICE guideline [NG126]; 2021.
- [17] Arri Coomarasamy, M.B., Ch.B., M.D. et al. A Randomized Trial of Progesterone in Women with Bleeding in Early Pregnancy. *New England Journal of Medicine*, Volume 380 • Number 19 • May 9, 2019, Pages: 1815-1824

Adnexal torsion and pregnancy: a case report and review of the literature

ORIGINALITY REPORT

14%

SIMILARITY INDEX

10%

INTERNET SOURCES

10%

PUBLICATIONS

4%

STUDENT PAPERS

PRIMARY SOURCES

1	coek.info Internet Source	2%
2	storage.googleapis.com Internet Source	1%
3	PanVascular Medicine, 2015. Publication	1%
4	Submitted to University of Western Sydney Student Paper	1%
5	Submitted to University of Hertfordshire Student Paper	1%
6	www.brainkart.com Internet Source	1%
7	Submitted to Royal College of Surgeons in Ireland Student Paper	1%
8	wrap.warwick.ac.uk Internet Source	1%
9	www.clinical-medicine.panafrican-med-journal.com Internet Source	1%
10	Dah-Ching Ding, Sidney S. Chen. "Conservative Laparoscopic Management of Ovarian Teratoma Torsion in a Young Woman", Journal of the Chinese Medical Association, 2005 Publication	1%

11	Federico Prefumo. "Adnexal torsion in late pregnancy", Archives of Gynecology and Obstetrics, 01/17/2009 Publication	1 %
12	Rackow, B.W.. "Successful pregnancy complicated by early and late adnexal torsion after in vitro fertilization", Fertility and Sterility, 200703 Publication	1 %
13	clinicalcasereportsjournal.com Internet Source	1 %
14	jrms.mui.ac.ir Internet Source	1 %
15	www.ijrcog.org Internet Source	1 %
16	www.rjpbcs.com Internet Source	1 %
17	"Endometriosis in Adolescents", Springer Science and Business Media LLC, 2020 Publication	1 %
18	www.acquirepublications.org Internet Source	1 %
19	www.sciencecodex.com Internet Source	1 %
20	Joseph Hasson, Ziv Tsafrir, Foad Azem, Shikma Bar-On, Beni Almog, Roy Mashiach, Daniel Seidman, Joseph B. Lessing, Dan Grisaru. "Comparison of adnexal torsion between pregnant and nonpregnant women", American Journal of Obstetrics and Gynecology, 2010 Publication	<1 %

Exclude quotes On

Exclude matches Off

Exclude bibliography On