

# 1                   **Oral cuniculatum carcinoma : a rare variant of squamous cell carcinoma**

## 2 3                   **Abstract**

4  
5                   Oral carcinoma cuniculatum is a rare variant of squamous cell carcinoma, recently recognized  
6                   as a distinct entity in the 2022 WHO classification. It is characterized by slow but locally  
7                   aggressive growth, a deceptive clinical presentation, and a distinctive histopathological  
8                   architecture with endophytic proliferation of deep keratin-filled crypts. We report the case of  
9                   an 80-year-old woman with type 2 diabetes who presented with a palatal lesion evolving over  
10                  seven years. Imaging revealed an infiltrative soft tissue mass without evidence of bone  
11                  destruction. Histopathological examination confirmed the diagnosis of oral carcinoma  
12                  cuniculatum. The main differential diagnoses include verrucous carcinoma and conventional  
13                  squamous cell carcinoma, highlighting the importance of careful clinico-pathological  
14                  correlation to avoid frequent misdiagnosis. The recommended treatment is wide surgical  
15                  excision with clear margins, while radiotherapy should be avoided due to the risk of  
16                  anaplastic transformation. Despite its locally destructive potential, the prognosis remains  
17                  favorable, as regional and distant metastases are exceptionally rare. Greater awareness and  
18                  early recognition are essential to optimize management and improve patient outcomes.

19  
20               **Keywords:** oral carcinoma cuniculatum, squamous cell carcinoma, rare tumor, differential  
21               diagnosis, surgery, prognosis.  
22  
23

## 24               **INTRODUCTION**

25  
26               Oral carcinoma cuniculatum (CC) is a rare form of squamous cell carcinoma,  
27               characterized by slow growth, aggressive behavior, and a distinctive histological appearance.  
28               It is distinguished by an infiltrative invasion in tunnels, reminiscent of rabbit burrows, hence  
29               its name "cuniculatum". It was initially described in 1954 by Aird and al. in the foot, which  
30               remains the most common location[1].

31               This entity is now clearly recognized in the World Health Organization (WHO)  
32               classification of head and neck tumors, in its 5th edition published in 2022 [2]. It often occurs  
33               in the elderly. Different clinical series report a variable female or male predominance [4,5].

34               Diagnosis is based on anatomopathological examination, which, among other things,  
35               allows for the elimination of differential diagnoses. Early diagnosis is crucial for appropriate  
36               treatment.

37               Treatment is primarily surgical. Oral CC has a favorable prognosis, particularly  
38               because, although it can invade locally and destroy tissue, regional or distant metastasis is  
39               rare.

40               The aim of this article is to analyze the clinical and histological characteristics in order  
41               to highlight the difficulties encountered in establishing an accurate diagnosis.  
42

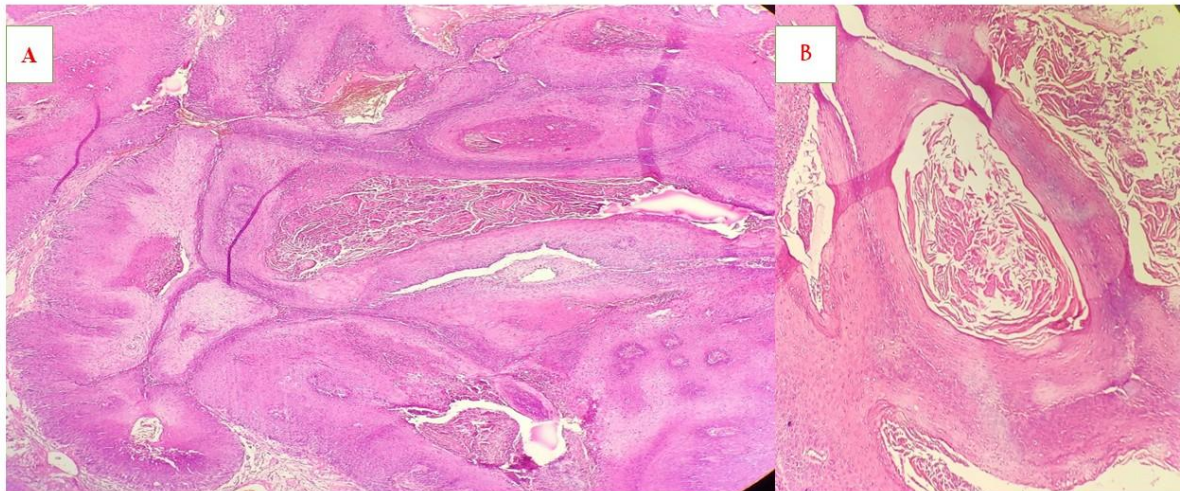
## 43               **OBSERVATION**

44

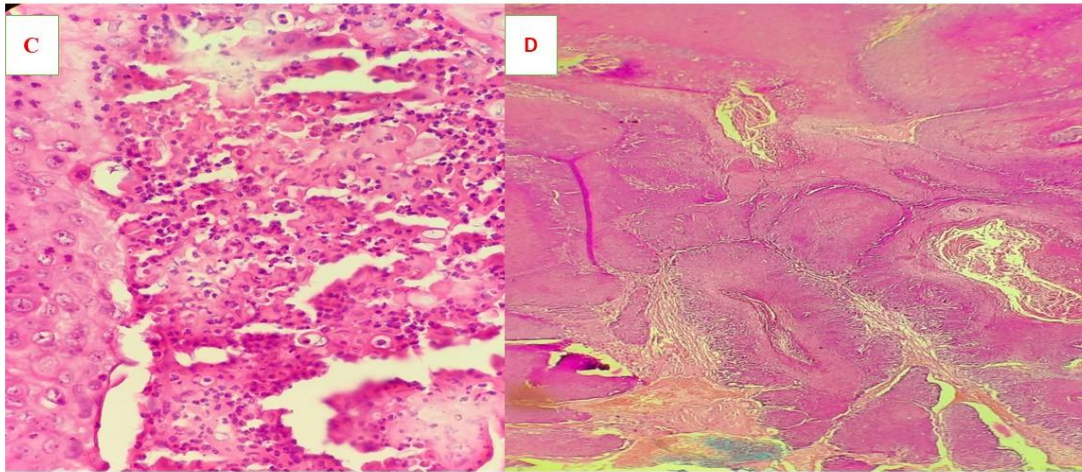
45 This is an 80-year-old woman with a history of type 2 diabetes who presents with a  
46 palatal lesion that has been developing for 7 years. The interview reveals no evidence of  
47 trauma or tobacco or alcohol consumption. The oral examination reveals a whitish infiltrating  
48 lesion measuring 1.5x1 cm.

49 A cervicofacial CT scan showed a well-defined right soft palate tissue thickening,  
50 enhanced after injection of contrast agent, measuring 30x25mm. This mass protruded into the  
51 oral cavity without lysis of the palatine bone or lysis of the mandibular bone with the presence  
52 of bilateral jugulo-carotid adenopathies measuring 10x12 mm on the right and 9x10 mm on  
53 the left.

54 A biopsy was performed, revealing a roughly rounded, whitish fragment with a  
55 polylobed surface measuring 1.2 cm in long axis. Microscopic examination (figures 1 and 2)  
56 showed an endophytic proliferation of squamous nature consisting of ridges of variable size  
57 and shape, with rounded ends, anastomotic and backed by place, centered in keratin and  
58 containing micro-abscesses. The basal layers are composed of cells showing rare nuclear  
59 atypia with the presence of some mitoses. The stroma is fibro-desmoplastic and inflammatory.  
60 The diagnosis of carcinoma cunuculatum was retained.



**Figure 1** : Photomicrograph (HEX 40) showing endophytic proliferation of stratified squamous epithelium enclosing keratin-filled crypts (**image A et B**).



**Figure 2 : Intraepithelial neutrophils and micro-abscesses (image C and D)**

## DISCUSSION

Carcinoma cuniculatum (CC) is a rare and unique form of well-differentiated squamous cell carcinoma, characterized by slow progression and tissue invasion in networks reminiscent of rabbit burrows, hence its name (cuniculi from the Latin = burrow) [1,2]. It is now clearly recognized by the WHO (5th edition 2022) as a distinct entity [2]. Its pathogenesis remains poorly understood. Smoking, alcohol consumption and chronic inflammation are suspected to play a role as risk factors, without a formal link having been demonstrated to date [4].

Oral CC accounts for up to 2.7% of all squamous cell carcinomas. It can affect any site of the body [1]. The oral cavity is the second most common location after cutaneous involvement, with a predilection for the mandibular gingivoalveolar region, followed by the maxilla, while other intraoral sites are less commonly involved [5,6]. The sex distribution of oral carcinoma cuniculatum varies among studies; some show a male predominance, others a slight female predominance [5,7].

It is a slow-growing tumor. Clinical symptoms are nonspecific. Oral CC evolves slowly and indolently, often leading to a delay in diagnosis due to the absence of marked functional signs. Presentations include swelling, oral ulcers, periodontitis with tooth mobility and chronic inflammation, leukoplakia lesions, or chronic pain. These symptoms can be confused with benign lesions or infections, thus delaying diagnosis.

CC often appears as a whitish exophytic lesion, similar to leukoplakia. Its surface is irregular, "cauliflower-like," with irregular edges. On palpation, small holes discharge a thick, purulent, whitish to yellowish exudate rich in keratin debris.

On imaging, carcinoma cuniculatum appears as a well-circumscribed lesion with irregular contours. It often manifests as radiolucency, sometimes with areas of increased density due to keratin or purulent exudate. Bone invasion results in demarcated bone lysis

[2,4,6,8]. Radiological diagnosis is, however, difficult and requires clinical and histopathological correlation.

CC [1,2] is characterized histologically by an endophytic growth pattern of a squamous epithelium forming interconnected crypts filled with keratin. These cavities, narrow and deep, contain cells with clear cytoplasm, with intercellular union bridges and discrete corneal maturation. The nuclei are regular and without atypia, and mitotic activity is rare. The stroma is inflammatory, mainly composed of lymphoplasmocytes, often with intraepithelial microabscesses. Initially, the basement membrane is preserved, but focal breaches appear at an advanced stage indicating transformation to a classic squamous cell carcinoma.

Differential diagnoses of CC can be made mainly with verrucous carcinoma, classic squamous cell carcinoma and papillary squamous cell carcinoma due to its similar clinical and histological features [2,7].

Verrucous carcinoma (VC) is the main differential diagnosis due to their clinical similarity. It is a predominantly exophytic, whitish, papillomatous lesion. Unlike CC, VC presents a very thickened squamous epithelium with intense ortho- or parakeratotic hyperkeratosis accompanied by local stromal invasion. The tumor cells are well differentiated with minimal cytonuclear atypia but there are no characteristic deep branching crypts.

Classic squamous cell carcinoma (classic squamous cell carcinoma) often presents with an ulcero-vegetative or ulcero-infiltrating appearance. It is a fast-growing tumor, unlike CC and CV. Histologically, classic squamous cell carcinoma shows cytonuclear atypia according to the grade of differentiation (well, moderately, poorly differentiated) with foci of keratinization in the form of horny globes or dyskeratotic cells. Mitoses are frequent. There are no deep branching crypts.

Papillary squamous cell carcinoma is characterized as a small papillary exophytic lesion. Its histological distinction from carcinoma cuniculatum is the presence of authentic papillae with fibrovascular axes. The lining epithelium shows cytonuclear atypia, without crypt organization.

Several studies highlight a delay in the diagnosis of oral cuniculatum carcinoma, often confused with benign lesions or inconclusive biopsies due to erroneous interpretations by pathologists [3,4,5,10]. However, no study specifies the duration between the onset and the definitive diagnosis of CC.

Extensive surgical resection with clear margins is recommended. The use of radiotherapy to treat carcinoma cuniculatum is not recommended due to the risk of anaplastic transformation, resulting in loss of tumor differentiation and increased aggressiveness [4,7,9]. Local recurrences are possible, often due to incomplete surgical excision due to difficulty in assessing the tumor boundaries [6,7,10]. The risk of lymph node or distant metastasis is exceptional [5,6,7,9].

## CONCLUSION

Oral carcinoma cuniculatum is a rare and unique form of squamous cell carcinoma, with slow but aggressive growth. Often overlooked, it causes diagnostic delays. Its misleading clinical presentation requires special vigilance from clinicians and pathologists, hence the need for in-depth knowledge of the diagnostic criteria for CC. The implementation of a standardized treatment protocol represents a major challenge to optimize its management and improve patient prognosis.

#### **Bibliographic references**

1591. Aird I, Johnson HD, Lennox B, Stansfeld AG. Epithelioma cuniculatum. Br J Surg. 1954;42(168):245-50.
1612. Muller S, Tilakaratne WM. Update from the 5th Edition of the World Health Organization Classification of Head and Neck Tumors: Tumors of the Oral Cavity and Mobile Tongue. Head Neck Pathol. 2022 Mar;16(1):54-62.
1643. Nagai M, et al. Carcinoma cuniculatum: a rare malignancy with unique diagnostic dilemmas. Cureus. 2023 Apr;15(4):eXXXX.
1664. Sivapathasundharam B, Kavitha B, Padmapriya VM. Carcinoma cuniculatum of the alveolar mucosa: a rare variant of squamous cell carcinoma. Head Neck Pathol. 2019 Dec;13(4):652-5.
1695. Yadav S, Bal M, Rane S, Mittal N, Janu A, Patil A. Carcinoma cuniculatum of the oral cavity: a series of 6 cases and review of literature. Head Neck Pathol. 2022 Mar;16(1):213-23.

- 172 6. Massé R, Duvernay J, Korbi S, Majoufre C, Schlund M. Oral carcinoma cuniculatum,  
173 a rare variant of squamous cell carcinoma. *J Stomatol Oral Maxillofac Surg*. 2024  
174 Sep;125(4):101729.
- 175 7. Farag AF, Abou-Alnour DA, Abu-Taleb NS. Oral carcinoma cuniculatum, an  
176 unacquainted variant of oral squamous cell carcinoma: a systematic review. *Imaging*  
177 *Sci Dent*. 2018 Dec;48(4):233.
- 178 8. Flieger S, Owinski T. Epithelioma cuniculatum an unusual form of mouth and jaw  
179 neoplasm. *Czas Stomatol*. 1977;30(5):395-401.
- 180 9. Berthon JA, et al. Carcinoma cuniculatum of the oral cavity: literature review. *Oral*  
181 *Med Oral Surg*. 2007;13(1):5-18.
- 182 10. Ajith A, et al. Carcinoma cuniculatum of the oral cavity: a diagnostic dilemma. *J Head*  
183 *Neck Physicians Surg*. 2018;6(1):54-6.
- 184