

# Breaking Barriers: When Appendiceal Disease Travels Off Course

## ABSTRACT

Appendix is an intraperitoneal organ .It is affected by various pathologies out of which appendicitis is most common.Mucinous adenocarcinoma is one of the most common neoplastic etiologies .Typical clinical symptoms and imaging ensures prompt intervention and treatment .However it is essential to be aware of certain unusual presentations of appendicular pathologies .The four rare cases in the article highlight how appendicular pathologies presents with rare extraperitoneal involvement and how crucial early imaging and surgical care are to better results, particularly in older or immunocompromised patients.

## KEYWORDS

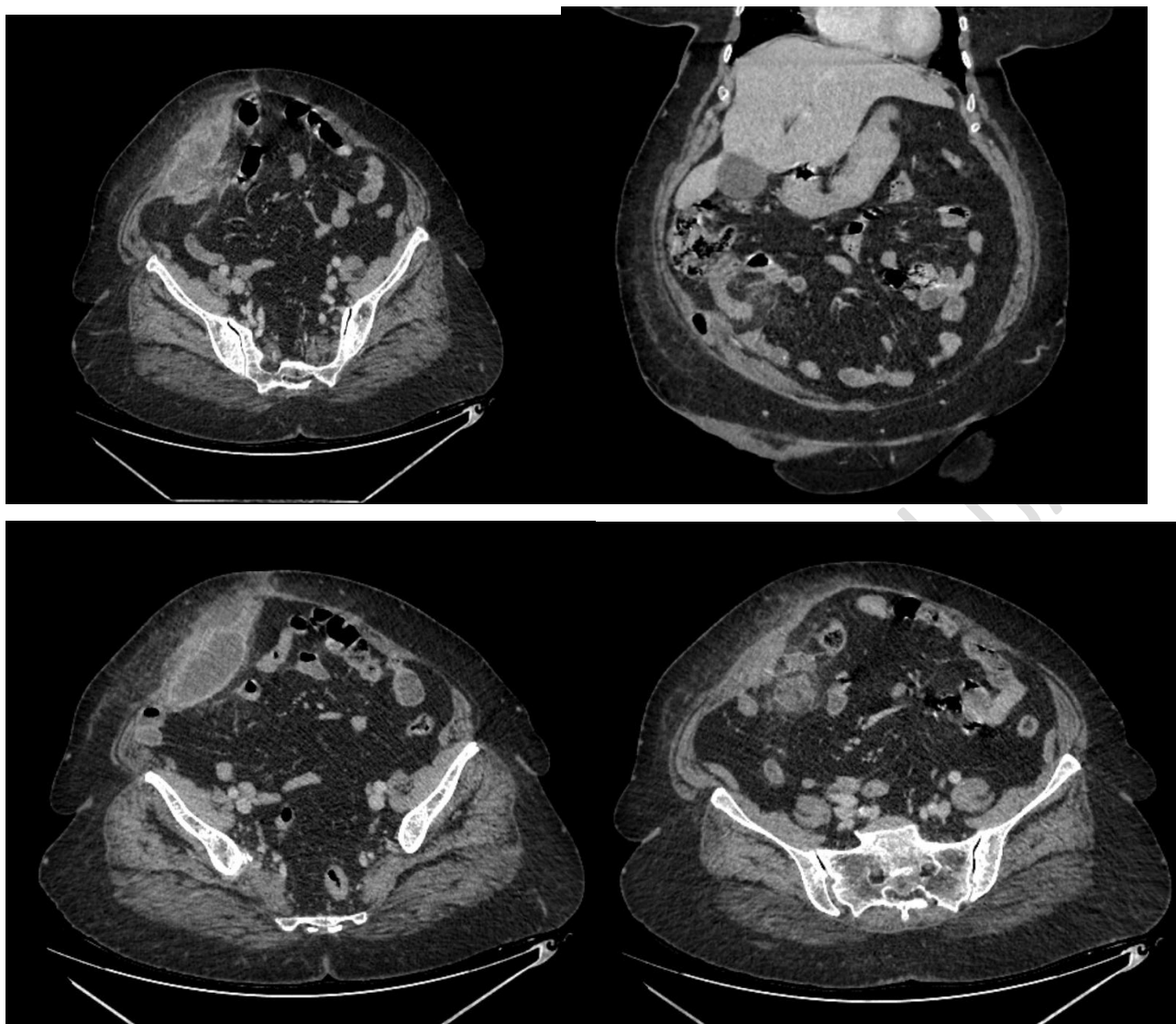
Appendix , retroperitoneum , abscess,mucinous adenocarcinoma , appendicitis

## INTRODUCTION

Appendix is a vestigial organ, typically intraperitoneal in location. The appendix can be impacted by a variety of benign and malignant tumors, inflammations, and infections. While appendiceal tumors are uncommon and typically present as appendicitis, acute appendicitis is frequently encountered in daily practice. Mucinous adenoma, low-grade appendiceal mucinous neoplasm (LAMN), and mucinous adenocarcinoma are the three categories of mucinous appendiceal neoplasms that the World Health Organization (WHO) has identified. Extensions of appendicular pathologies to adjacent structures following perforation or malignancies are usually confined to peritoneal cavity .Extraperitoneal expansions of these appendicular disorders are exceedingly uncommon. Hereby presents four unusual manifestations of appendicular diseases with extra-peritoneal extension are described here.

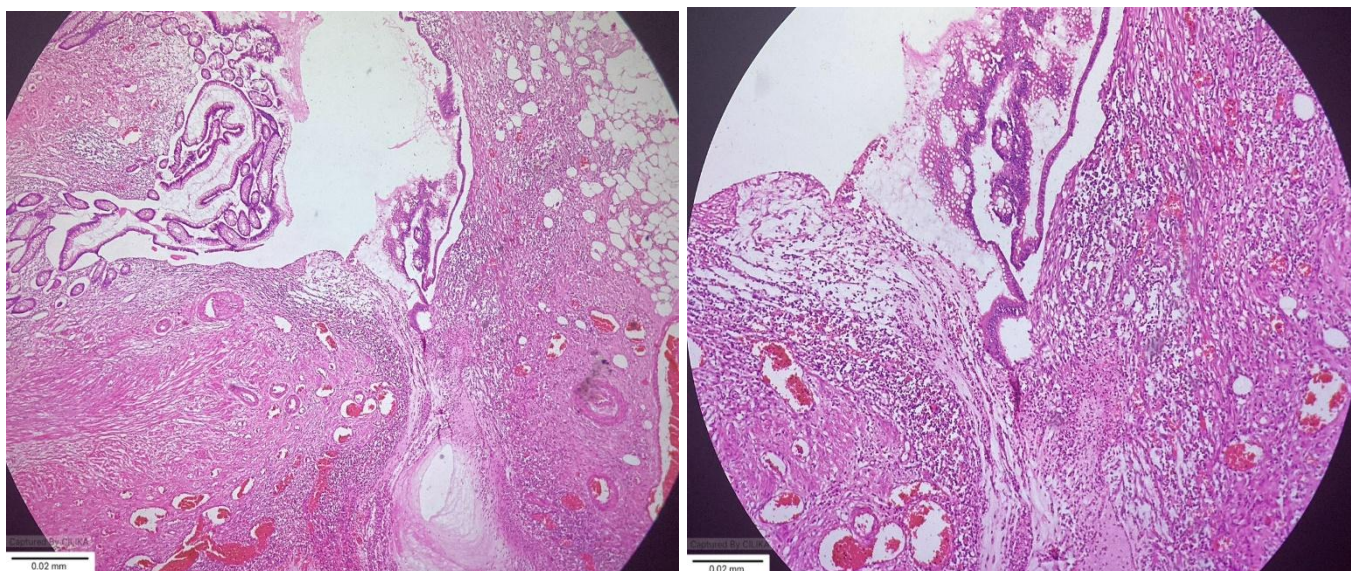
## CASE 1

A 69-year-old lady without any past comorbidities presented with diffuse abdominal pain and high-grade fever for three weeks, later experiencing heaviness on the right side of abdomen . Upon examination, a 6x5 cm swelling with redness and localized warmth was found close to the umbilicus.USG abdomen showed inflamed appendix with significant periappendiceal fat stranding and heteroechoic collection in right lumbar and iliac fossa region.She underwent CECT abdomen which depicted dilated appendix with a periappendiceal abscess that extended into the subcutaneous and muscular planes . One hundred milliliters of pus were drained during an emergency exploratory laparotomy from the site , with resection and ileotransverse anastomosis. Acute appendicitis with perforation and abscess was confirmed by histopathology. The patient recovered, and the postoperative phase went smoothly.



41

Figure 1 Contrast enhanced CT images of abdomen venous phase (a) shows dilated appendix with adjacent heterogeneously enhancing collection (b) coronal image shows dilated appendix, (c) well defined peripherally enhancing multiloculated oblong shaped hypodense collection in the right lower anterior abdominal wall (d) collection with adjacent fat stranding



47

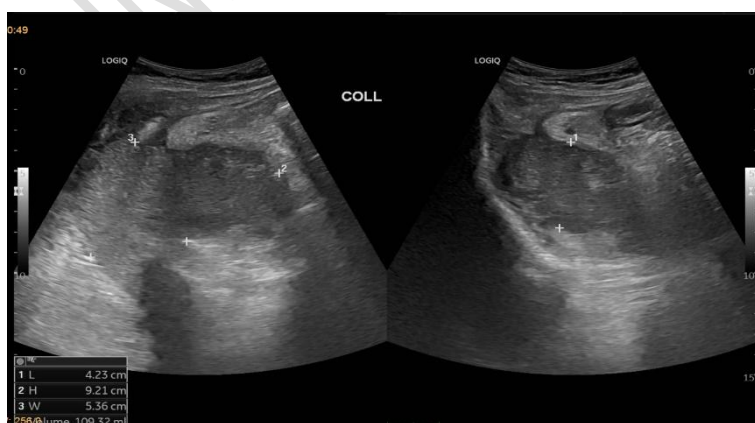48

## 49 CASE 2

50 A 61-year-old diabetic woman had a three-week history of right-sided back discomfort and  
 51 swelling, as well as a brief episode of fever. She was admitted with provisional diagnosis if  
 52 retroperitoneal abscess .Emergency USG-guided percutaneous catheter drainage was done , and  
 53 a pus culture indicated beta-hemolytic Streptococcus and E. coli. CECT abdomen showed dilated  
 54 appendix with heterogenous post contrast enhancement .A fairly well defined irregularly  
 55 margined peripherally enhancing hypodense collection measuring approximately 12.6 x 12.5 x  
 56 10.2 cm ( AP x CC x TR ) ( approximate volume 109 cc )epicentered in posterior pararenal space is  
 57 noted communicating with appendix .Posteromedially collection is seen indenting and  
 58 compressing psoas and iliacus muscles .Laterally collection is seen extending the subcutaneous  
 59 plane in the right iliac fossa and posteroinferior aspect ( extending beyond abdominal wall ).

60 The patient had a right hemicolectomy with ileocolic anastomosis and an exploratory laparotomy.  
 61 histopathology revealed appendix mucinous adenocarcinoma. She had a good surgical response  
 62 and improved symptoms.

63



64

65 Figure 3 Ultrasonograph image showing heterogenous collection.



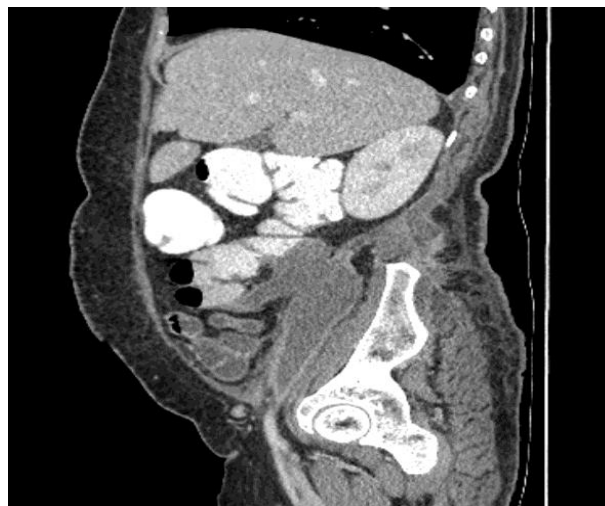
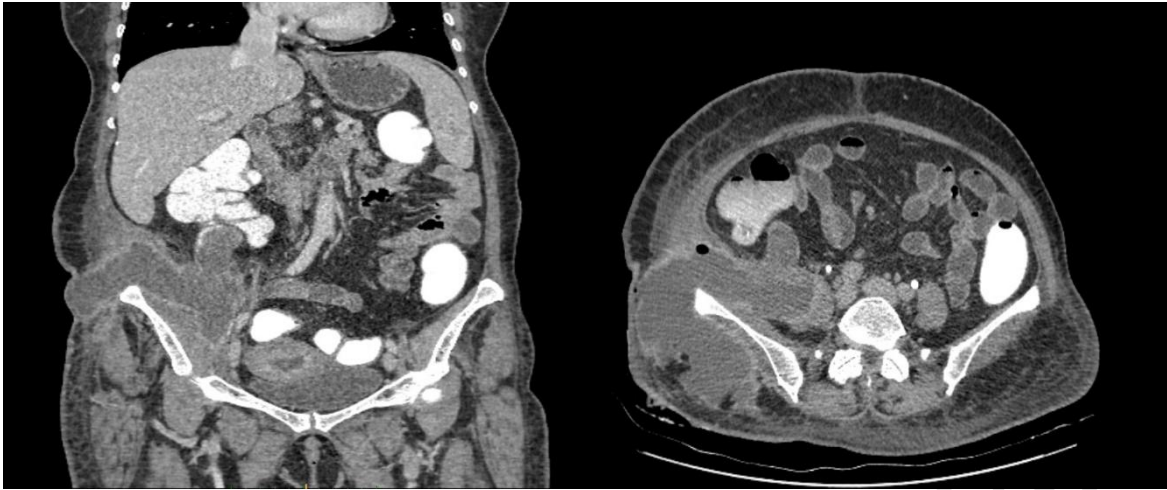
Figure 4 Contrast enhanced CT abdomen, venous phase (a) Coronal ,shows grossly dilated appendix with lobulated irregular appearance (b) Axial section ,appendix communicating with well defined peripherally enhancing hypodense collection epicentered in posterior pararenal space.Collection extending laterally to subcutaneous plane in right iliac fossa.Medially involving right iliopsoas and iliacus muscle.(c)Saggital section, retroperitoneal extension of collection.

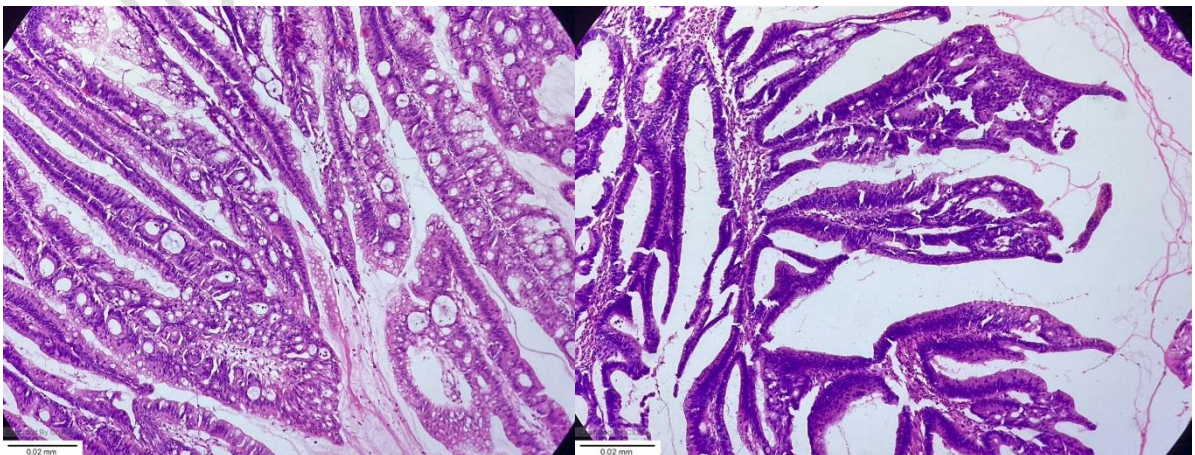
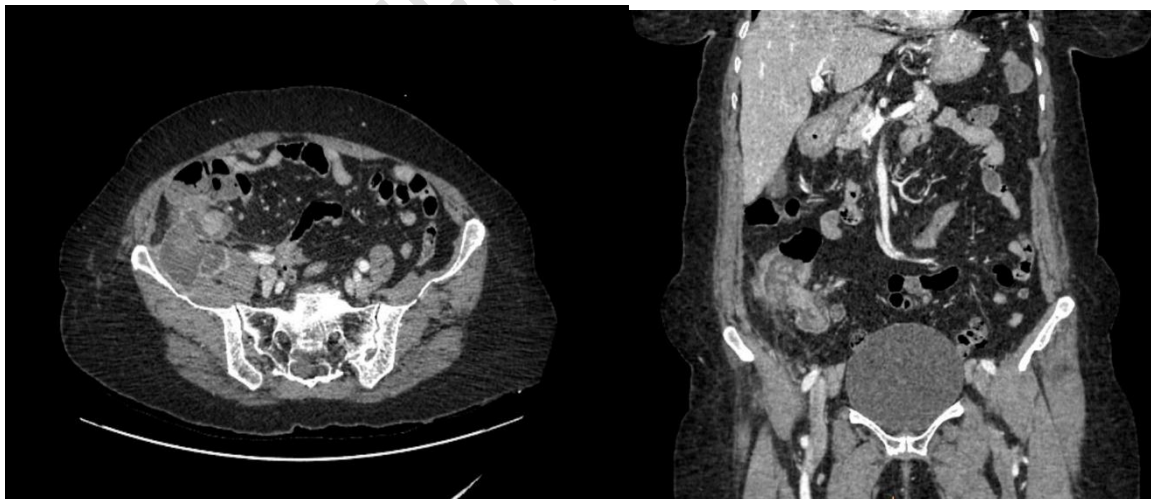


Figure 5 Histopathologic appearance of mucinous adenocarcinoma.(a) shows columnar cells with moderate eosinophilic to mucinous cytoplasm

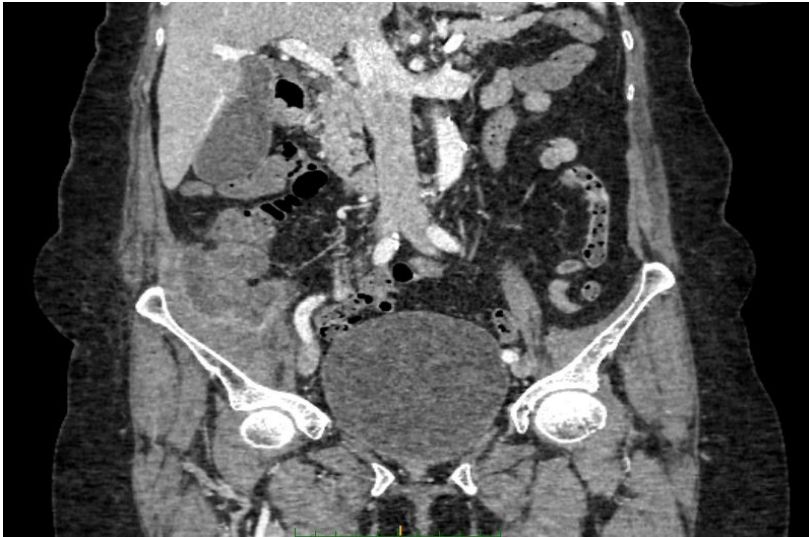### CASE 3

A 74-year-old woman with diabetes and hypertension came in with a history of melena and acute right-sided abdomen pain that got worse when she moved. Both the right lumbar and hypochondriac regions showed signs of local soreness. Patient was admitted with provisional diagnosis of abdominal mass under evaluation.CECT showed an irregular peripherally enhancing cystic area measuring approximately 5.4 x5.5 x6.3 cm ( AP x TR x CC ) in the right iliac region with involvement of distal caecum and proximal ascending colon ( appendix not separately delineated) with few homogenously and heterogeneously enhancing solid areas and adjacent small volume lymphnodes . Cystic area is seen infiltrating the right psoas ,reaching upto iliac bone .

Patient underwent exploratory laparotomy which showed a tumor in caecum infiltrating to the posterior parietal wall and extending to the iliac bone, creating a 5x4 cm void that was filled with necrotic tissue and mucus.Right hemicolectomy was done for the patient . Biopsy report came out to be mucinous adenocarcinoma appendix with tumor infiltration into the visceral peritoneum, appendix muscularis propria, subserosa, and caecal serosa. The patient's postoperative recuperation went smoothly, and their symptoms improved.

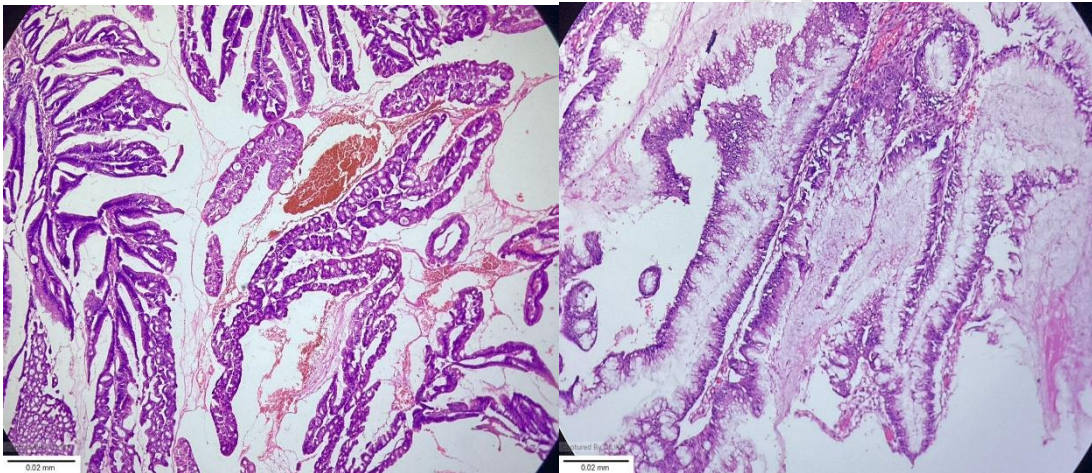




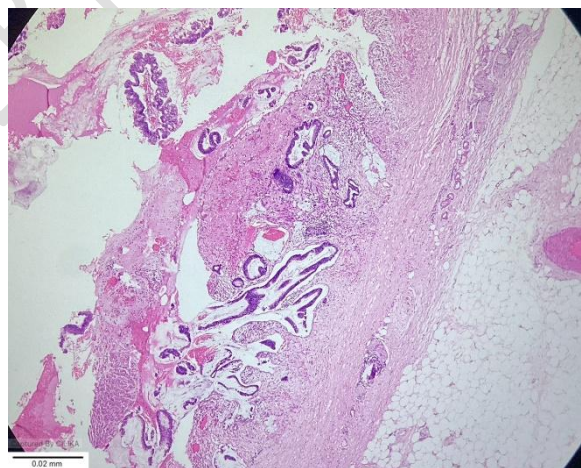


99

100 Figure 6 -Contrast enhanced CT images , venous phase (a-c)axial image shows irregular  
101 peripherally enhancing cystic in the right iliac region with involvement of distal caecum and  
102 proximal ascending colon with few homogenously and heterogeneously enhancing solid areas.



103



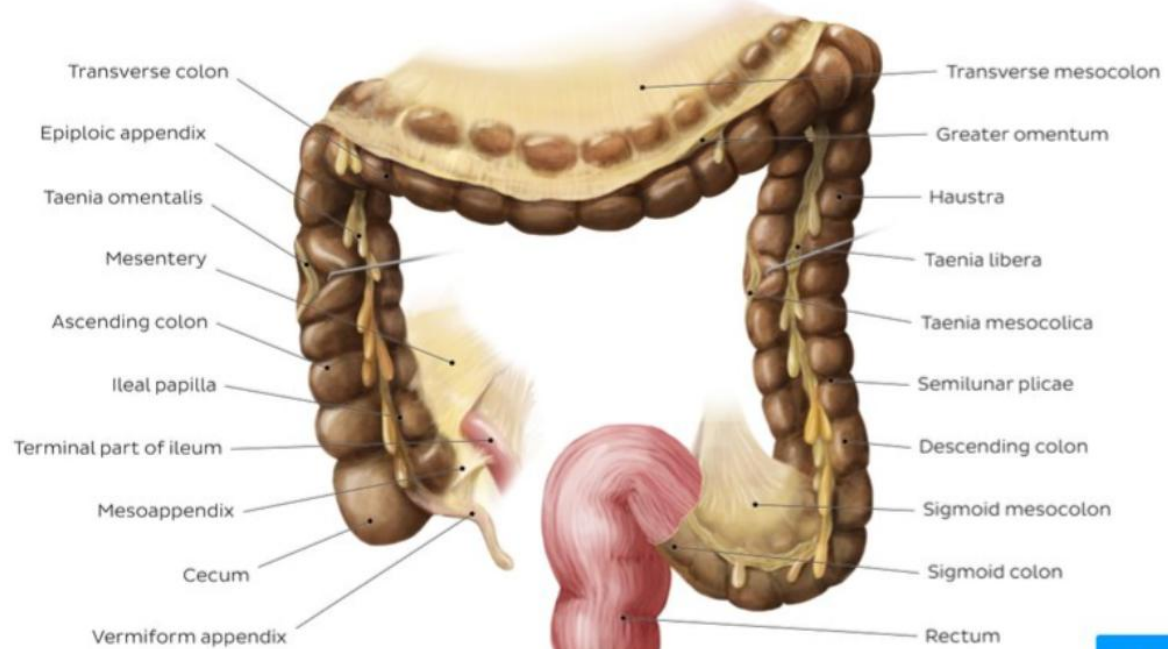
104

105 Figure 7 -Histopathological images of mucinous adenocarcinoma (a)Appendicular mucin filled epithelium  
106 (b) section consist of tumor cells with extracellular mucin (c) image depicts infiltration of neoplasm with  
107 cells arranged in villoglandular pattern

108

## DISCUSSION

The appendix, also called the vermiform appendix, is a tiny, muscular tube with a blind end that is connected to the cecum, which is the first segment of the large intestine. The appendix originates from the posteromedial aspect of the cecum. It is supported by the mesoappendix, a fold of mesentery which suspends the appendix from the terminal ileum. The position of the free-end of the appendix is highly variable and can be categorised into seven main locations depending on its relationship to the ileum, caecum or pelvis. The most common position is retrocecal. Although its exact role is still unknown, it is vulnerable to tumors, mucocoeles, and appendicitis, among other illnesses.



The most prevalent condition affecting the appendix, appendicitis frequently results in severe stomach discomfort and necessitates emergency surgery. Serious side effects like perforation, peritonitis, or abscess formation may result from delayed diagnosis and treatment. The appendix's fluctuating position and the vagueness of its symptoms may cause a delay in diagnosis. Serious consequences like intestinal blockage or widespread peritonitis could result from such delays.

Appendix tumors are uncommon; they only occur in little more than 1% of appendectomy specimens. Most are epithelial or neuroendocrine tumors, which frequently manifest as mucocoeles. During assessment for symptoms similar to appendicitis or through unrelated findings, imaging may show these neoplasms. Additionally, they may show up as urinary symptoms, gastrointestinal bleeding, or an increase in abdominal circumference as a result of diseases like pseudomyxoma peritonei.

After appendiceal perforation, the formation of a retroperitoneal abscess is an extremely uncommon yet dangerous consequence. Retroperitoneal abscesses are more difficult to identify and treat than intraperitoneal infections because of their deep anatomical location and the presence of large amounts of fat tissue, which makes draining more difficult. These infections have the potential to spread to nearby regions, such as the lower extremities and psoas muscle. Metastatic involvement from appendicular origins is uncommon, despite the higher prevalence of initial retroperitoneal cancers. Rarely are retroperitoneal abscesses from appendiceal disorders documented in the literature.

This case series emphasizes the value of early diagnosis and timely surgical intervention. It consists of three new cases as well as a review of prior data. For patients dealing with this rare but dangerous condition, prompt management—including appendectomy and abscess drainage—is essential to lowering morbidity and guaranteeing positive results.

## CONCLUSION

In contrast to the usually peritoneal-confined sickness, this case series focuses on uncommon appendiceal disorders that disseminate extraperitoneally. Three cases showed mucinous adenocarcinoma with atypical extraperitoneal extension, and one case comprised a retroperitoneal abscess caused by a perforated appendix. The significance of preserving clinical suspicion in atypical abdominal or pelvic presentations is highlighted by these cases. Prompt surgical or oncological intervention, precise imaging, and early detection are essential. Gaining knowledge of these uncommon symptoms helps with accurate diagnosis and treatment, which eventually improves results in challenging or ambiguous clinical scenerios.

## TEACHING PONTS

- Appendix is an intraperitoneal organ .Appendicitis , mucocoele, appendicular neoplasm are the pathologies affecting appendix
- Appendicular pathological complications are confined within peritoneum , with pseudomyxoma peritoni being the most common
- Extraperitoneal involvement is extremely rare.Rare presentation include retroperitoneal abcess formation extending to abdominal wall
- Identifying the rare presentation is essenatila for early identification an drompt medial interventions.

## MCQ S



**1. Which of the following best describes the primary objective of the case series on retroperitoneal appendicular pathologies?**

- A) To evaluate new pharmaceutical treatments for appendicitis.
- B) To explore rare extraperitoneal manifestations of appendicular diseases and emphasize early diagnosis and intervention.
- C) To analyze the nutritional status of patients with appendiceal cancer.
- D) To develop a non-surgical management protocol for appendiceal abscesses.

**Answer: B**

**2. In the case series, which diagnostic tools were consistently utilized to assess patients with extraperitoneal appendicular complications?**

- A) Blood cultures and MRI.
- B) Colonoscopy and plain abdominal X-rays.
- C) Ultrasonography, contrast-enhanced CT, laparotomy, and histological examination.
- D) PET scan and biopsy alone.

**Answer: C**

**3. According to the study, which patient outcome was observed following surgical intervention for extraperitoneal appendicular conditions?**

- A) Complete recovery in all patients without complications.
- B) Recurrence of disease in the majority of patients.
- C) Successful recovery in most patients, with one fatality due to hemodynamic instability.
- D) Immediate discharge of all patients within 24 hours.

**Answer: C**

## REFERENCES

1. Salehipour M, Haghpour A, Dehghani A. Retroperitoneal mass, a rare manifestation of mucinous adenocarcinoma of appendix: A case report. Clin Case Rep. 2022;10:e06602. doi: 10.1002/ccr3.6602
2. Nahhas A, Abderahman A, Kharaba A. A snake in the grass: retroperitoneal abscess due to perforated appendicitis—management, approach and recommendations. Journal of Surgical Case Reports, 2019;5, 1–3 doi: 10.1093/jscr/rjz163
3. Hsieh C, Wang Y, Yang H, Chung P. Retroperitoneal Abscess Resulting from Perforated Acute Appendicitis: Analysis of Its Management and Outcome. Surg Today (2007) 37:762–767 DOI 10.1007/s00595-006-3481-5
4. Li J, Li F, Wang C, Sun Y. Management of retroperitoneal appendiceal perforation: a case report. Journal of Surgical Case Reports, 2024, 2, rjae069
5. Leonards LM, Pahwa A, Patel M K, Petterson J. Neoplasms of the Appendix: Pictorial Review with Clinical and Pathologic Correlation, Jun 9 2017 <https://doi.org/10.1148/rg.2017160150>

6. Leite N P ,Pereira J M ,Cunha R ,Pinto P . CT Evaluation of Appendicitis and Its Complications: Imaging Techniques and Key Diagnostic Findings .  
<https://doi.org/10.2214/ajr.185.2.0185040>

#### **Acknowledgment**

We acknowledge , consultant surgeon, and Dr. Jessy MM, HOD Department of Pathology, for their valuable contribution toward the clinical and pathological findings, respectively.

#### **Ethical approval**

Institutional Review Board approval is not required.

#### **Declaration of patient consent**

The authors certify that they have obtained all appropriate patient consent.

#### **Conflicts of interest**

There are no conflicts of interest.

#### **Use of artificial intelligence (AI)-assisted technology for manuscript preparation**

The authors confirm that there was no use of artificial intelligence (AI)-assisted technology for assisting in the writing or editing of the manuscript, and no images were manipulated using AI.

#### **Financial support and sponsorship**

Nil.