

# FUNCTIONAL AND RADIOLOGICAL OUTCOME OF FEMORAL NECK SYSTEM IN TREATMENT OF FEMORAL NECK FRACTURES IN YOUNG ADULTS

## Introduction

Femoral neck fractures represent a significant orthopedic concern, particularly in young adults, due to their association with high-energy trauma such as motor vehicle accidents, falls from height, or sports injuries. Unlike elderly patients—where these fractures are typically linked to osteoporosis and low-energy mechanisms—fractures in younger individuals present complex biomechanical challenges. The preservation of native hip function and prevention of complications like avascular necrosis (AVN), non-union, and implant failure are key goals of treatment. Traditional fixation methods, such as multiple cannulated screws and dynamic hip screws (DHS), have limitations including inadequate rotational stability and a relatively high reoperation rate. As a result, the Femoral Neck System (FNS), a newer implant, has emerged as a promising alternative offering biomechanical advantages like enhanced stability, dynamic compression, and reduced failure risks.

The femoral neck plays a critical role in transmitting weight-bearing forces and has a precarious vascular supply, primarily through the medial circumflex femoral artery. Any disruption to this supply can lead to ischemia and eventual AVN of the femoral head. Due to its intracapsular location, a femoral neck fracture poses unique healing challenges that necessitate precise surgical intervention. In young adults, where the longevity and function of the native hip are paramount, total hip arthroplasty is generally avoided, making the choice of internal fixation methods critically important. The FNS, with its integrated lateral plate, fixed-angle bolt, and anti-rotation screw, aims to address the shortcomings of traditional

implants. This design not only enhances angular and rotational stability but also allows controlled dynamic compression, promoting more effective fracture healing.

Biomechanical studies have demonstrated that the FNS offers superior resistance to shear and rotational forces compared to conventional cannulated screws. These characteristics are especially relevant for younger, more active individuals who require durable and stable fixation for early mobilization and long-term joint preservation. Historically, femoral neck fractures in young patients have shown high complication rates, with substantial numbers requiring secondary procedures such as valgus osteotomy or even hip replacement. The FNS is designed to mitigate these complications by improving mechanical stability and reducing micromotion at the fracture site.

Despite its theoretical advantages, clinical evidence supporting the use of FNS in young adults remains limited. Most existing studies have focused on elderly populations with different biomechanical profiles. Therefore, there is a pressing need to assess the functional and radiological outcomes of the FNS specifically in younger patients. This study seeks to address that gap by evaluating the effectiveness of the FNS in promoting fracture union and restoring function in young adults with femoral neck fractures.

## **Materials and methods**

This prospective clinical study was conducted to evaluate the radiological and functional outcomes of femoral neck fractures in young adults treated with the Femoral Neck System (FNS). The study included patients aged between 18 and 50 years who presented with fresh, closed femoral neck fractures and underwent fixation using the FNS at a tertiary care hospital. Only patients who met the inclusion criteria—specifically, those with fractures less than three weeks old and without any pathological or open injuries—were enrolled after obtaining informed consent.

Preoperative evaluation included detailed history-taking, clinical examination, and radiological assessment using standard anteroposterior and lateral X-rays of the pelvis and affected hip. The fractures were classified using the Pauwels and Garden classification systems to assess displacement and orientation, which were then used to guide surgical planning. Baseline investigations and necessary pre-anesthetic evaluations were also conducted to ensure fitness for surgery.

All surgeries were performed under spinal or general anesthesia on a fracture table, with closed or open reduction achieved depending on the complexity of the fracture. Fluoroscopic guidance was used throughout the procedure to ensure accurate placement of the FNS, which consists of a locking plate, a fixed-angle bolt, and an anti-rotation screw. Postoperatively, patients were closely monitored, and standard antibiotic and analgesic protocols were followed. Early mobilization with non-weight bearing was initiated as tolerated by the patient, typically within the first week after surgery.

Follow-up assessments were conducted at regular intervals—specifically at 6 weeks, 3 months, 6 months, and 12 months. During each visit, clinical evaluation included pain assessment, range of motion, and gait analysis. Radiological evaluation was performed using X-rays to assess fracture healing, implant position, and signs of complications such as avascular necrosis (AVN), non-union, or implant failure. Functional outcomes were measured using the Harris Hip Score (HHS), a validated tool that assesses pain, function, absence of deformity, and range of motion.

Data collected were compiled and statistically analyzed using appropriate software. Continuous variables were presented as means and standard deviations, while categorical variables were expressed as frequencies and percentages. Repeated measures ANOVA was used to determine the significance of differences in outcomes, with a p-value of  $<0.05$ .

72 considered statistically significant. The primary endpoints were fracture union and functional  
73 outcome as per the HHS, while secondary endpoints included complications and need for  
74 reoperation.

PEER REVIEW IN IJAR

## Tables and figures

**Table 1. Patient characteristics (n=20)**

Parameters	Frequency	Percentage
Age group (years)		
21-25	5	25
26-30	12	60
31-35	2	10
36-40	1	5
Sex		
Male	14	70
Female	6	30
Mode of injury		
RTA	15	75
Self fall	5	25

**Table 2. Post-treatment characteristics of patients (n=20)**

Parameters	Frequency/ mean	Percentage/ SD
Mean time to radiological union (weeks)	14.4	4.1
Complications		
Implant cut-out	2	10
Avascular necrosis	1	5
Infection	1	5
Femoral neck shortening $\geq 5$ mm		
Yes	4	20
No	16	80

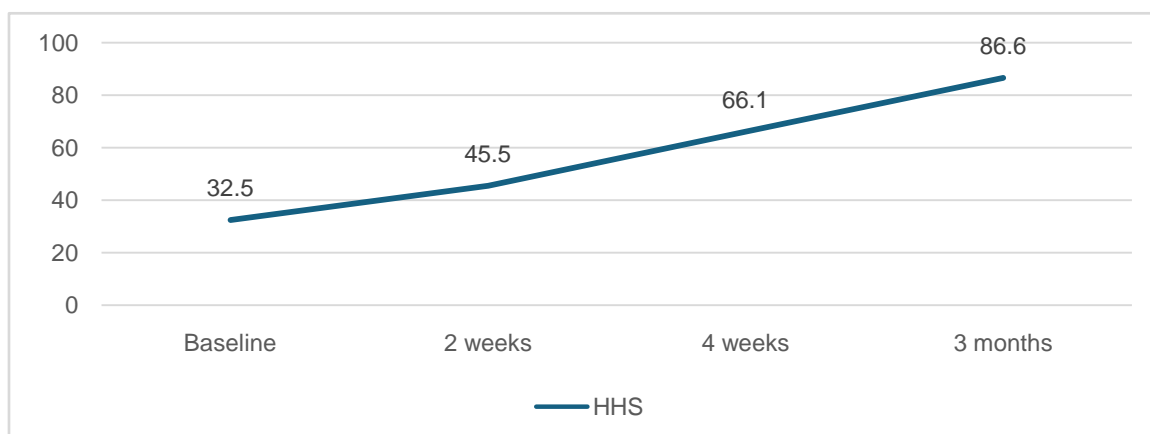
## Results

The study analyzed 20 young adult patients with femoral neck fractures treated using the Femoral Neck System (FNS). The majority of participants (60%) were between 26 and 30 years old, with a male predominance of 70%. Road traffic accidents accounted for 75% of the injuries, underscoring the high-energy trauma pattern typical in this age group. Functional outcomes, assessed through the Harris Hip Score (HHS), showed substantial improvement during follow-up. The mean HHS improved from 32.5 at baseline to 45.5 at 2 weeks, 66.1 at 4 weeks, and reached 86.6 at 3 months postoperatively, reflecting excellent functional recovery ( $p < 0.001$ ). Concurrently, pain levels measured using the Visual Analog Scale (VAS) decreased significantly from a baseline mean of 7.7 to 1.2 at 3 months ( $p < 0.001$ ), indicating effective pain relief and patient comfort during rehabilitation.

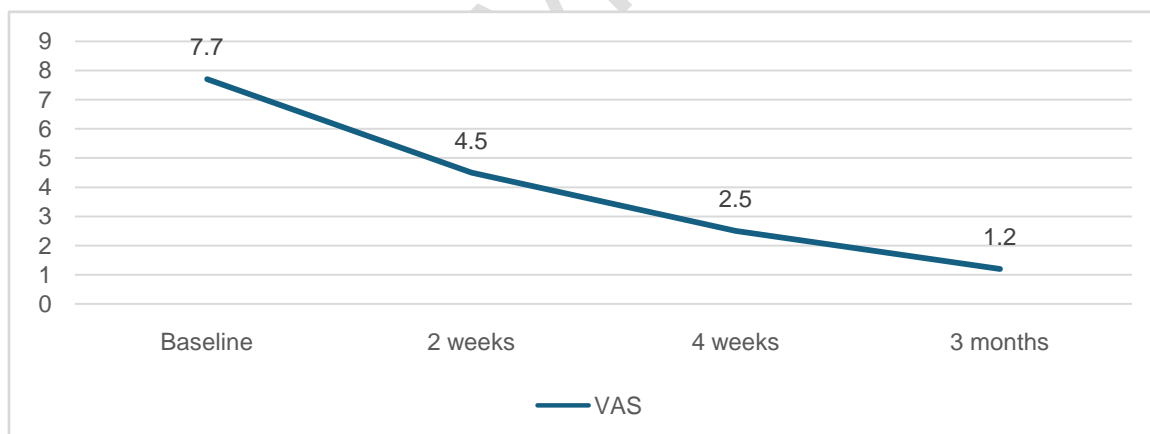
Radiological evaluation revealed that fracture union was achieved in an average of 14.4 weeks ( $SD = 4.1$  weeks), suggesting a relatively prompt healing process consistent with the mechanical stability offered by the FNS. The overall complication rate was low. Implant cut-out was reported in 2 patients (10%), avascular necrosis (AVN) in 1 patient (5%), and postoperative infection in 1 patient (5%). Notably, there were no instances of implant failure, non-union, or reoperation, emphasizing the reliability of FNS in maintaining stable fixation and promoting fracture healing without secondary interventions.

Femoral neck shortening of  $\geq 5$  mm was noted in 4 patients (20%), while 16 patients (80%) experienced no significant shortening, indicating a favorable outcome compared to traditional fixation techniques.

**Figure 1. Post-treatment Harris Hip Score changes characteristics (n=20)**



**Figure 2. Post-treatment VAS Score changes of patients (n=20)**





## Discussion

The management of femoral neck fractures in young adults remains a significant orthopedic challenge, primarily due to the risk of complications such as non-union and avascular necrosis (AVN) stemming from disruption of the femoral head's vascular supply. The present study aimed to evaluate the efficacy of the Femoral Neck System (FNS), a relatively new internal fixation device, in addressing these challenges and promoting favorable outcomes in young patients. Our results suggest that the FNS offers reliable fixation, early union, and satisfactory functional recovery with minimal complications, thus presenting a promising alternative to traditional fixation methods like multiple cannulated screws and dynamic hip screws (DHS).

One of the key findings in our study was the high rate of fracture union observed, with an average healing time of 14.4 weeks. This outcome can be attributed to the biomechanical design of the FNS, which provides angular stability, controlled dynamic compression, and resistance to rotational forces. These features are crucial in femoral neck fractures, where shear and torsional stresses can compromise healing. Previous studies have highlighted the limitations of traditional methods, especially in vertically oriented fractures classified as Pauwels Type III, which are inherently unstable. Our results echo findings by Stoffel et al., who demonstrated the biomechanical superiority of the FNS over conventional screw configurations in terms of load-bearing capacity and rotational control.

Functional outcomes, as measured by the Harris Hip Score (HHS), were encouraging. The majority of patients achieved excellent or good scores by the 3-month follow-up, indicating effective restoration of hip function and mobility. Early weight-bearing and mobilization are

critical to preventing complications such as joint stiffness, muscle wasting, and thromboembolic events, and the FNS facilitated this process without compromising fracture stability. The significant reduction in pain, as evidenced by the declining VAS scores, further supports the effectiveness of the implant in improving postoperative comfort and rehabilitation.

Although the complication rate in this study was low, it is important to acknowledge the few adverse events observed. Two patients experienced implant cut-out, one developed AVN, and another presented with a superficial infection. These outcomes are consistent with existing literature, which suggests that even with advanced fixation techniques, complications cannot be entirely eliminated. However, the absence of non-union or implant breakage in our cohort is noteworthy and supports the hypothesis that the FNS provides robust mechanical support, particularly beneficial in young, active patients.

Shortening of the femoral neck was observed in 20% of cases, which, while higher than ideal, is still an improvement over some historical outcomes reported with cannulated screws. It is possible that meticulous surgical technique, appropriate patient selection, and the implant's inherent design features contributed to minimizing the rate and extent of shortening. These findings underscore the importance of accurate fracture reduction and implant positioning, which are critical determinants of success in femoral neck fracture management.

The present study demonstrates that the Femoral Neck System (FNS) is an effective and reliable method for the treatment of femoral neck fractures in young adults. By providing superior biomechanical stability, controlled dynamic compression, and resistance to rotational forces, the FNS facilitates early mobilization and fracture union. Functional outcomes assessed using the Harris Hip Score and pain reduction evaluated via the Visual Analog Scale indicate significant postoperative improvement. The overall complication rate

was low, with no cases of non-union and only isolated instances of implant cut-out, avascular necrosis, and infection. These results highlight the FNS as a valuable alternative to conventional fixation techniques, especially in high-demand, younger patients where preservation of the native hip joint is critical.

## **Conclusion**

The present study demonstrates that the Femoral Neck System (FNS) is an effective and reliable method for the treatment of femoral neck fractures in young adults. By providing superior biomechanical stability, controlled dynamic compression, and resistance to rotational forces, the FNS facilitates early mobilization and fracture union. Functional outcomes assessed using the Harris Hip Score and pain reduction evaluated via the Visual Analog Scale indicate significant postoperative improvement. The overall complication rate was low, with no cases of non-union and only isolated instances of implant cut-out, avascular necrosis, and infection. These results highlight the FNS as a valuable alternative to conventional fixation techniques, especially in high-demand, younger patients where preservation of the native hip joint is critical.

## REFERENCE

1. Physicians RCo (2017) National hip fracture database (NHFD) annual report 2017. In. RCP London.
2. Zelle BA, Salazar LM, Howard SL, Parikh K, Pape HC (2022) Surgical treatment options for femoral neck fractures in the elderly. *Int Orthop*. 10.1007/s00264-022-05314-3 [DOI] [PubMed]
3. Panteli M, Rodham P, Giannoudis PV. Biomechanical rationale for implant choices in femoral neck fracture fixation in the non-elderly. *Injury*. 2015;46:445–452. doi: 10.1016/j.injury.2014.12.031. [DOI] [PubMed] [Google Scholar]
4. Stoffel K, Zderic I, Gras F, Sommer C, Eberli U, Mueller D, Oswald M, Gueorguiev B. Biomechanical evaluation of the femoral neck system in unstable Pauwels III femoral neck fractures: a comparison with the dynamic hip screw and cannulated screws. *J Orthop Trauma*. 2017;31:131–137. doi: 10.1097/BOT.0000000000000739. [DOI] [PubMed] [Google Scholar]
5. Schopper C. Biomechanical evaluation of the femoral neck fracture fixation technique with the new implant FNS in comparison to DHS Blade. DHS Screw with antirotation screw and Three Cannulated Screws. In: Universität Ulm; 2018. [Google Scholar]
6. Cintean R, Pankratz C, Hofmann M, Gebhard F, Schutze K. Early results in non-displaced femoral neck fractures using the femoral neck system. *Geriatr Orthop Surg Rehabil*. 2021;12:21514593211050153. doi: 10.1177/21514593211050153. [DOI] [PMC free article] [PubMed] [Google Scholar]
7. He C, Lu Y, Wang Q, Ren C, Li M, Yang M, Xu Y, Li Z, Zhang K, Ma T. Comparison of the clinical efficacy of a femoral neck system versus cannulated screws in the treatment of

femoral neck fracture in young adults. *BMC Musculoskelet Disord.* 2021;22:994. doi: 10.1186/s12891-021-04888-0. [DOI] [PMC free article] [PubMed] [Google Scholar]

8.Hu H, Cheng J, Feng M, Gao Z, Wu J, Lu S. Clinical outcome of femoral neck system versus cannulated compression screws for fixation of femoral neck fracture in younger patients. *J Orthop Surg Res.* 2021;16:370. doi: 10.1186/s13018-021-02517-z. [DOI] [PMC free article] [PubMed] [Google Scholar]

9.Nibe Y, Matsumura T, Takahashi T, Kubo T, Matsumoto Y, Takeshita K (2021) A comparison between the femoral neck system and other implants for elderly patients with femoral neck fracture: a preliminary report of a newly developed implant. *J Orthop Sci.* 10.1016/j.jos.2021.04.016 [DOI] [PubMed]

10.Stassen RC, Jeuken RM, Boonen B, Meesters B, de Loos ER, van Vugt R (2021) First clinical results of 1-year follow-up of the femoral neck system for internal fixation of femoral neck fractures. *Arch Orthop Trauma Surg.* 10.1007/s00402-021-04216-0 [DOI] [PubMed]

11.Tang Y, Zhang Z, Wang L, Xiong W, Fang Q, Wang G. Femoral neck system versus inverted cannulated cancellous screw for the treatment of femoral neck fractures in adults: a preliminary comparative study. *J Orthop Surg Res.* 2021;16:504. doi: 10.1186/s13018-021-02659-0. [DOI] [PMC free article] [PubMed] [Google Scholar]

12.Vazquez O, Gamulin A, Hannouche D, Belaieff W. Osteosynthesis of non-displaced femoral neck fractures in the elderly population using the femoral neck system (FNS): short-term clinical and radiological outcomes. *J Orthop Surg Res.* 2021;16:477. doi: 10.1186/s13018-021-02622-z. [DOI] [PMC free article] [PubMed] [Google Scholar]

13.Zhou XQ, Li ZQ, Xu RJ, She YS, Zhang XX, Chen GX, Yu X. Comparison of early clinical results for femoral neck system and cannulated screws in the treatment of unstable

femoral neck fractures. *Orthop Surg.* 2021;13:1802–1809. doi: 10.1111/os.13098. [DOI]  
[PMC free article] [PubMed] [Google Scholar]

14.Zhang YZ, Lin Y, Li C, Yue XJ, Li GY, Wang B, Wang YQ, Zhu ZQ (2022) A comparative analysis of femoral neck system and three cannulated screws fixation in the treatment of femoral neck fractures: a six-month follow-up. *Orthop Surg.* 10.1111/os.13235 [DOI] [PMC free article] [PubMed]

15.Niemann M, Braun KF, Ahmad SS, Stöckle U, Märdian S, Graef F (2022) Comparing perioperative outcome measures of the dynamic hip screw and the femoral neck system. *Medicina (Kaunas)* 58. 10.3390/medicina58030352 [DOI] [PMC free article] [PubMed]

PEER REVIEW IN IJAR

PEER REVIEW IN IJAR



PEER REVIEW IN IJAR