

# Jana Publication & Research

## Successful Treatment of Laser Induced Hypopigmentation with Platelet-Rich Plasma Case Report

 VRC31

 BioTech

 Institut Seni Indonesia Surakarta

---

### Document Details

#### Submission ID

trn:oid::1:3419504125

#### Submission Date

Nov 21, 2025, 12:06 PM GMT+7

#### Download Date

Nov 21, 2025, 3:42 PM GMT+7

#### File Name

IJAR-54892.pdf

#### File Size

282.2 KB

10 Pages





2,033 Words

11,441 Characters




# 10% Overall Similarity

The combined total of all matches, including overlapping sources, for each database.

## Match Groups

- 
**9 Not Cited or Quoted 6%**  
 Matches with neither in-text citation nor quotation marks
- 
**6 Missing Quotations 3%**  
 Matches that are still very similar to source material
- 
**0 Missing Citation 0%**  
 Matches that have quotation marks, but no in-text citation
- 
**0 Cited and Quoted 0%**  
 Matches with in-text citation present, but no quotation marks

## Top Sources

- 8%  Internet sources
- 6%  Publications
- 1%  Submitted works (Student Papers)

## Match Groups

- 9 Not Cited or Quoted** 6%  
Matches with neither in-text citation nor quotation marks
- 6 Missing Quotations** 3%  
Matches that are still very similar to source material
- 0 Missing Citation** 0%  
Matches that have quotation marks, but no in-text citation
- 0 Cited and Quoted** 0%  
Matches with in-text citation present, but no quotation marks

## Top Sources

- 8% Internet sources
- 6% Publications
- 1% Submitted works (Student Papers)

## Top Sources

The sources with the highest number of matches within the submission. Overlapping sources will not be displayed.

1	Internet	www.mdpi.com	2%
2	Internet	asra.com	1%
3	Internet	pmc.ncbi.nlm.nih.gov	1%
4	Internet	sealff.org	1%
5	Student papers	Queen Mary and Westfield College	<1%
6	Internet	apcz.umk.pl	<1%
7	Publication	Aditi Vashisht, Arvind Krishna, Robin Chugh, Abhinav David, Divyanshu Srivastava...	<1%
8	Internet	dokumen.pub	<1%
9	Internet	public-pages-files-2025.frontiersin.org	<1%
10	Publication	Denisa Vladulescu, Lucian G. Scurtu, Anca Angela Simionescu, Francesca Scurtu, ...	<1%

11

Publication

"Platelet-Rich Plasma in Tissue Repair and Regeneration", Springer Science and B...

<1%



## **Successful treatment of laser-induced hypopigmentation with platelet-rich plasma case report**

UNDER PEER REVIEW IN IJAR

## Abstract

Introduction: Platelet-rich plasma (PRP) has become an increasingly popular treatment that

extracts plasma enriched with a high concentration of platelets and growth factors from the patient's blood to improve cosmetic and functional outcomes. This versatile treatment is useful in treating alopecia, psoriasis, hyperpigmentation, vitiligo, and improving skin rejuvenation. By processing a patient's blood, PRP allows for platelets and growth factors to be reintroduced into the skin, which can promote healing, tissue regeneration, and in this case, a restoration of skin pigmentation.

Case presentation: This case report demonstrates the use of PRP therapy on a 28-year-old Caucasian female with no significant past medical history suffering from hypopigmentation following laser hair removal. After failed topical corticosteroid treatment, three sessions of PRP were performed, spaced 6 weeks apart, resulting in almost complete clearance of hypopigmentation.

Conclusion: The positive outcome observed in this patient suggests that PRP may be a promising treatment option for various types of hypopigmentation, potentially offering a non-invasive and effective approach for patients suffering from this condition.

## Introduction

Platelet-rich plasma (PRP) is a treatment modality derived from a patient's own blood, enriched with a high concentration of platelets and growth factors. Its use began in the 1980s for various medical conditions, including orthopedic injuries, infertility, erectile dysfunction, and regenerative medicine [1]. In the field of dermatology, PRP has gained popularity and is now used for hair growth, psoriasis, skin rejuvenation, hyperpigmentation, and vitiligo [1]. Its

regenerative properties through the release of growth factors allow for stimulation of cell differentiation, proliferation, and tissue repair which has been proven beneficial in treating various skin conditions.

Vitiligo treatment with PRP is an idea that has been studied more recently, indicating that PRP has the ability to release cytokines and growth factors, allowing for cell differentiation, proliferation, and regeneration of cells [2]. This has proven successful in helping with repigmentation and improving healing rates when combined with narrow ultraviolet B and transplantation of epidermal cells [3]. These findings have sparked interest in PRP's broader applications in pigmentary disorders. One area that remains underexplored is the use of PRP in treating laser-induced hypopigmentation. Laser therapies, though effective for certain dermatologic concerns, present with the risk of post-laser pigmentary changes. Here, we present the case of a 28-year-old female who had improvement in laser-induced hypopigmentation after PRP injections.

## Case Report

A 28-year-old Caucasian female with no significant past medical history presented to the office with a two-month history of post-inflammatory hypopigmentation status post-laser hair removal (LHR). As demonstrated in Figure 1 a, circular hypopigmentation spots were located on the bilateral lower legs spanning from the knee to the ankle. After the initial laser hair removal two months ago, the patient reported scabbing, followed by the appearance of circular hypopigmentation patches. The hypopigmentation patches were determined to be moderate in severity, covering 15% body surface area. The LHR was performed in the winter. The patient was not tan at the time of the procedure, and she avoided sunlight following the treatment. The

47 patient documented that she has no personal history of vitiligo, other pigmentation disorders, or  
48 autoimmune disease.

49 At her first visit, which the patient reported to be two months after her laser hair removal, she  
50 was prescribed triamcinolone acetonide 0.1% topical cream along with daily use of Aquaphor.

51 She was also counseled on skincare, including avoiding sun exposure and using sunscreen.

52 Despite using the steroids in a 2-week on, 2-week off regimen for two months, there was  
53 minimal improvement, so the treatment was discontinued. PRP therapy was initiated two weeks  
54 after discontinuation of the steroids. Before each PRP treatment, the bilateral pretibial regions  
55 were anesthetized with 7% tetracaine, and 23% lidocaine in addition to ice for pain control.

56 During the first treatment, 22cc of blood was drawn, centrifuged, and divided into 4, 3cc  
57 syringes for injection into the bilateral lower legs. Following treatment, the patient was informed  
58 to take precautions against sun exposure. Including avoiding the application of sunscreen to the  
59 legs for 12 hours post-procedure and withholding regular skin care regimen with topical  
60 moisturizer for 2-3 days. Also, avoiding alcohol-based toners for 10-14 days post-procedure.

61 Six weeks later, the hypopigmentation was significantly improved at patient follow-up, and the  
62 second treatment was initiated. The third was done an additional six weeks later, completing her  
63 recommended three sessions of PRP. By the conclusion of the three treatments, the patient  
64 exhibited considerable improvement as demonstrated in Figure 1 b, with hypopigmentation  
65 nearly entirely resolved in the lower legs.



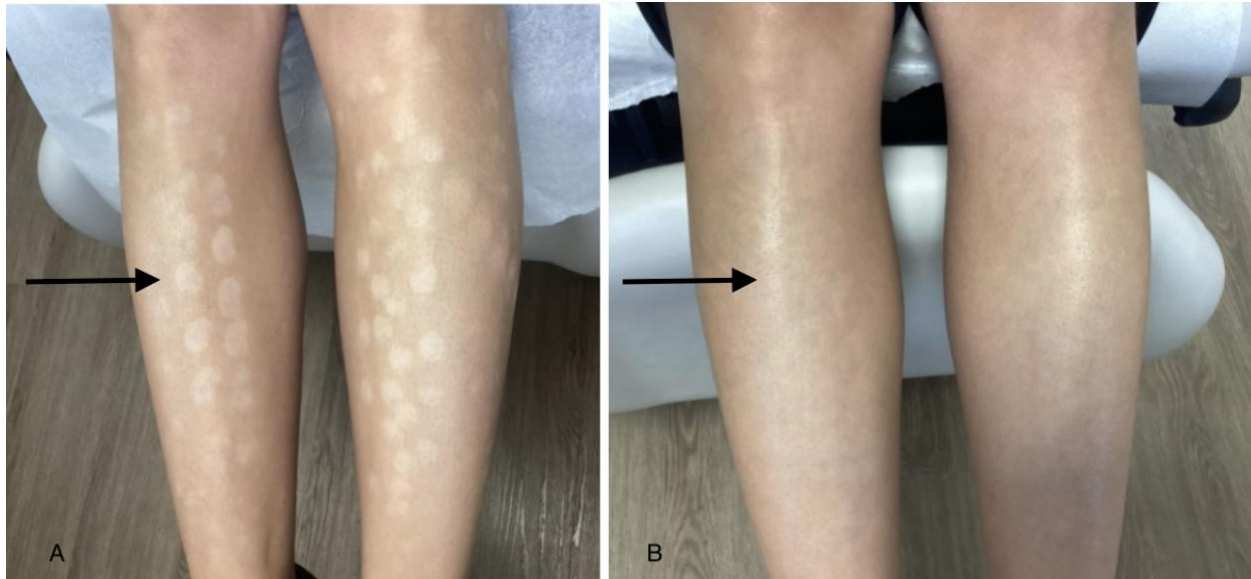


Figure 1. *Before (A) image of circular hypopigmentation patches of the bilateral lower extremities of a 28-year-old Caucasian female 2 months post laser hair removal. After (B) images of the bilateral lower extremities of the same 28-year-old Caucasian female demonstrating repigmentation following three sessions of PRP.*

## Discussion

PRP therapy is a versatile treatment with cosmetic and functional applications extending beyond the most commonly studied treatments. PRP therapy was initially used in the 1970s in hematology for patients suffering from thrombocytopenia [4]. Its use expanded in the 1980s and 1990s for surgical procedures in reconstruction plastic surgery [4]. As medicine has progressed, PRP has been introduced into many specialties including orthopedics, cardiology, sports injury, gynecology, urology, and dermatology [4]. Over the last decade, PRP has been an upcoming aesthetic treatment modality, specifically to combat facial aging, targeting wrinkles, open pores, and pigmentation [5]. PRP therapy uses centrifugated blood with a high concentration of platelets and their growth factors in a small volume of plasma. Growth factors are secreted from

alpha granules inside the platelet cells [6]. About 10 minutes after injection, alpha granules release the growth factors [6]. Platelet cells continue to make and release growth factors over the next week after treatment [6]. The release of these growth factors has been documented to improve bone fracture healing, injuries of muscles, articular cartilage lesions, and peripheral nerve injuries [6]. Additionally, it has the ability to improve the healing of wounds, alopecia, inflammatory disorders, and skin rejuvenation [6].

Regarding skin pigmentation, PRP has been reported to be effective in treating hypopigmentation by preventing apoptosis of melanocytes [6]. After injection of PRP, there is a stimulation of Akt which inhibits the degradation of beta-catenin, ultimately stimulating the proliferation of melanocytes [6]. Additionally, PRP helps to strengthen intercellular adhesions with the help of growth factors that stimulate the proliferation of keratinocytes and fibroblasts [6]. Antiinflammatory effects of PRP include the downregulation of cytokines, including the release of interleukin-1, interferon-gamma, and tumor necrosis factor-alpha [6]. Melanocytic proliferation, intercellular adhesion strengthening, and antiinflammatory effects contribute to repigmentation.

While PRP therapy has been increasingly studied and applied in the context of vitiligo [1], limited data remains regarding its efficacy in repigmentation for other skin conditions. Vitiligo is one of the primary areas where PRP therapy has shown promise. However, there is an opportunity for a broader exploration of the use of PRP in the context of repigmentation. While some small-scale studies suggest that PRP may be beneficial in forms of post-inflammatory hypopigmentation [7], burns [8], and scars [9], there is a lack of comprehensive clinical trials to determine its efficacy. This case demonstrates the potential that PRP therapy has for the use of repigmentation in a unique dermatologic condition. As PRP therapy continues to evolve as a

105 treatment for additional dermatologic concerns, additional studies are needed to investigate its  
106 potential further.

107

## 108 **Conclusion**

109 This case report highlights a relatively unexplored application of PRP therapy for patients  
110 suffering from laser-induced hypopigmentation, which is notoriously challenging to treat. In this

111 case, a 28-year-old Caucasian female with no significant past medical history demonstrated  
112 significant repigmentation after undergoing three sessions of PRP in six-week intervals. The  
113 positive outcome observed in this patient suggests that PRP could offer a viable treatment  
114 solution for treating other cases of laser-induced hypopigmentation as well as other causes of  
115 hypopigmentation, including those caused by trauma, burns, and other skin disorders. Given the  
116 promising results observed in this case, additional case reports and further clinical studies are  
117 necessary to explore the potential positive effect that PRP can have in treating hypopigmentation.

118

## 119 **Patient Perspective**

120 The patient initially presented to the office two months after undergoing laser hair removal at  
121 another practice. She expressed concerns due to her previous experience, as she had never  
122 encountered issues with hypopigmentation before and was uncertain whether any effective  
123 treatment options were available. After a trial of topical corticosteroids, which proved  
124 unsuccessful, the patient became frustrated and sought an alternative treatment approach. She  
125 was open to trying PRP therapy, as the appearance of her legs was of significant importance to  
126 her. The patient tolerated the PRP procedure well during the office visit and adhered to the

scheduled follow-up appointments for the subsequent two treatments. She expressed a high level of satisfaction with the outcome of the treatment.

## References

1. Mercuri SR, Vollono L, Paolino G. The Usefulness of Platelet-Rich Plasma (PRP) for the Treatment of Vitiligo: State of the Art and Review. *Drug Des Devel Ther.* 2020 May 7;14:1749-1755. doi: 10.2147/DDDT.S239912. PMID: 32440100; PMCID: PMC7213865.
2. Pretorius J, Habash M, Ghobrial B, Alnajjar R, Ellanti P. Current Status and Advancements in Platelet-Rich Plasma Therapy. *Cureus.* 2023 Oct 17;15(10):e47176. doi: 10.7759/cureus.47176. PMID: 38021947; PMCID: PMC10652151.
3. Rodriguez M, Mayrovitz HN. The History and Current Status of Platelet-Rich Plasma Therapy in Dermatology. *Cureus.* 2024 Aug 31;16(8):e68306. doi: 10.7759/cureus.68306. PMID: 39350861; PMCID: PMC11441414.
4. Gupta S, Paliczak A, Delgado D. Evidence-based indications of platelet-rich plasma therapy. *Expert Rev Hematol.* 2021 Jan;14(1):97-108. doi: 10.1080/17474086.2021.1860002. Epub 2020 Dec 17. PMID: 33275468.
5. Nanda S, Chauhan K, Shetty V, Dashore S, Bhatia S. Platelet-Rich Plasma in Aesthetics. *Indian Dermatol Online J.* 2021 Nov 25;12(Suppl 1):S41-S54. doi: 10.4103/idoj.idoj\_290\_21. PMID: 34976880; PMCID: PMC8664171.
6. Vladulescu D, Scurtu LG, Simionescu AA, Scurtu F, Popescu MI, Simionescu O. Platelet-Rich Plasma (PRP) in Dermatology: Cellular and Molecular Mechanisms of

Action. Biomedicines. 2023 Dec 19;12(1):7. doi: 10.3390/biomedicines12010007. PMID: 38275368; PMCID: PMC10813350.

7. Uysal CA, Ertas NM. Platelet-Rich Plasma Increases Pigmentation. J Craniofac Surg. 2017 Nov;28(8):e793. doi: 10.1097/SCS.0000000000002893. PMID: 27438442.

8. Santos KC, Dos Santos BM, Ribeiro M, de Miranda Moraes J, Cagnini DQ, Liebano RE, Araujo GHM. Full-thickness burn scar treatment using a combination of microneedling and platelet-rich plasma in animal model. Tissue Cell. 2024 Dec;91:102610. doi: 10.1016/j.tice.2024.102610. Epub 2024 Nov 14. PMID: 39571420.

9. Alser OH, Goutos I. The evidence behind the use of platelet-rich plasma (PRP) in scar management: a literature review. Scars Burn Heal. 2018 Nov 18;4:2059513118808773. doi: 10.1177/2059513118808773. PMID: 30479843; PMCID: PMC6243404.

#### Author contributions

E.G contributed to writing the manuscript draft and preparing Figure 1. E.G., A.L., and C.F. reviewed and edited final drafts of the manuscript. All authors reviewed and approved the final manuscript.

Funding None.

Data availability No sets of data were created or analyzed.

#### Declarations

172 Conflict of interest None.

173 Consent to publish Patient signed written informed consent and agreed to submission of the case

174 report, photographs, and their clinical results.

175

UNDER PEER REVIEW IN IJAR