

 <p>ISSN NO. 2320-5407</p>	<p>Journal Homepage: - www.journalijar.com</p> <h2 style="text-align: center;">INTERNATIONAL JOURNAL OF ADVANCED RESEARCH (IJAR)</h2> <p style="text-align: center;">Article DOI: 10.21474/IJAR01/10052 DOI URL: http://dx.doi.org/10.21474/IJAR01/10052</p>	
---	---	---

RESEARCH ARTICLE

CAVITARY THROMBOSIS, A NEOPLASTIC COMPLICATION TO BE FEARED.

Achraf Mouden, Smiti Yassine, Oussama Ssouni, Brahim El Ahmadi, Abdelilah Ghannam and Zakaria Belkhadir.

Anesthesia and care unit service, national institute of oncology, Rabat Morocco.

Manuscript Info

Manuscript History

Received: 12 September 2019

Final Accepted: 14 October 2019

Published: November 2019

Key words:-

Cavitary thrombosis, esophageal neoplasia, ultrasound.

Abstract

Introduction: Thrombosis of the right cavities is rare, it concerns 4% of pulmonary emboli in the ICOPER register. This prevalence is probably underestimated.

It must be considered as an immediate vital threat; untreated, mortality is 80 to 100%

Observation: We will report the case of a patient, hospitalized in the intensive care unit after a neoplastic surgery of the esophagus and for whom a transthoracic ultrasound performed because of respiratory distress and tachycardia objectified a right ventricular intracavitary thrombosis.

Discussion: The presence of a moving right intra-atrial mass during pulmonary embolism confers a higher risk of death to the patient.

This localization of thrombi could be explained by an embolization resulting from peripheral venous thrombosis, an impaired right ventricular systolic function; an atrial rhythm disorder or a simple dilation of the atria. Authors have reported mechanisms caused by central venous catheter; carbon monoxide poisoning.

Heparin alone is insufficient in these patients, treatment may involve either surgical thrombectomy or intravenous thrombolysis.

the generalization of ultrasound in the emergency and resuscitation departments as well as the training of practitioners should make it possible to diagnose thrombosis of the right heart chambers more early and, more generally, the existence of an acute pulmonary heart.

Conclusion: Thrombosis of the right cavities is rare, it concerns 4% of pulmonary emboli; Heparin alone is insufficient in these patients, even when the clinical condition is stable. Treatment may involve either surgical thrombectomy or intravenous thrombolysis. Therapeutic diagnosis and management is an emergency, because if not treated in time, the mortality is 80 to 100%.

Copy Right, IJAR, 2019,. All rights reserved.

Introduction:-

Thrombosis of the right cavities is rare, it concerns 4% of pulmonary emboli in the ICOPER register. This prevalence is probably underestimated [1].

It must be considered as an immediate vital threat; untreated, mortality is 80 to 100% [2].

Corresponding Author:-Achraf Mouden.

Address:-Anesthesia and care unit service, national institute of oncology, Rabat Morocco.

We will report the case of a patient, hospitalized in the intensive care unit and for whom a transthoracic ultrasound performed in front of a respiratory distress objectified a right ventricular intracavitary thrombosis.

Observation:-

Mrs K.L aged 66, obese with a body mass index at 36kg / m², having as antecedent hypothyroidism under levothyrox and arterial hypertension put on calcium antagonist and angiotensin receptor antagonist.

Hospitalized in resuscitation after exeresis surgery for oesophageal neoplasia.

Problems posed during her stay in intensive care:

1. Digestif hemorage treated by proton pompe inhibitors and surgery
2. Septic shock, of pulmonary origin put under emipenem , cholimycine , amikacine , metronidazol .
3. Difficulty with respiratory withdrawal due to pneumopathies and postoperative pleurisy, for which the patient had a tracheotomy on the 17th day of her hospitalization.
4. neuromyopathy

During her respiratory withdrawal, the patient presented a polypnea with tachycardia without fever , reason why we suspected pulmonary embolism.

a heart ultrasound has been realized , wich showed non-dilated right cavities with a Right Ventricle / Left Ventricle ratio <0.8, but presence of a hyperechogenic image on the right ventricle suspecting a thrombus (figure 1) , with a normal ultrasound of the lower limb. To confirm the thrombosis, the patient did a myocardial MRI. The patient was placed on enoxaparin curative dose, and 3 days after on 30 mg od rivaroxaban daily.

No thrombolysis was done because of high risk of hemorage. The evolution was good, the improvement of the respiratory state with decrease of the size of the intracavitary thrombus. The patient leaved the resuscitation service in the following days, totally autonomous on the respiratory level.

Discussion:-

Thrombosis of the right cavities is rare, it concerns 4% of pulmonary emboli in the ICOPER register. This prevalence is probably underestimated [1].

It must be considered as an immediate vital threat. Untreated, mortality is 80 to 100% [2].

The presence of a moving right intra-atrial mass during pulmonary embolism confers a higher risk of death to the patient.

This localization of thrombi could be explained by an embolization resulting from peripheral venous thrombosis. Another mechanism is in situ formation favored by impaired right ventricular systolic function; an atrial rhythm disorder or a simple dilation of the atria. Authors have reported mechanisms caused by central venous catheter [3]; carbon monoxide poisoning [4].

Heparin alone is insufficient in these patients, even when the clinical state is stable, because its survival benefit is significantly lower than that of thrombolysis (mortality rate of 28.6% vs. 11.3% respectively) or surgical embolectomy [2,5]. Treatment may involve either surgical thrombectomy or intravenous thrombolysis.

A review by Rose et al. reported_ the cases of 177 patients with floating thrombus diagnosis in the right cavities. Overall mortality was 48 out of 177 patients (27.1%). Therapeutically, 35 patients (19.8%) received anticoagulation, 63 patients (35.6%) underwent surgical embolectomy, 62 patients (35.0%) had thrombolysis and 16 patients (9.0%) were not treated. Mortality rates for patients receiving heparin therapy, surgical embolectomy, and thrombolysis were 28.6%, 23.8%, and 11.3%, respectively. One hundred percent of untreated patients are deceased. [6]

A prospective series by Gilbert and al. evaluated the incidence of floating thrombus in TransThoracic ultrasonography for patients admitted for severe pulmonary embolism by thrombolysis over a period of 18 months and selected thrombolysis as the first line of treatment.

Of the 12 patients, 9 had thrombolysis (the other 3 patients had a contraindication). Seven of the 9 patients survived with disappearance of the floating thrombus and depression of acute pulmonary signs at 12, 24 hours and 7 days.[7] In some hospital series, complete disappearance of thrombi within 2 to 24 hours after thrombolysis was observed in 50%, 75% or even 100% of patients [8].

In a meta-analysis of scientific publications from 1999 to 2013, Gandhi and al. compared the efficacy of the three treatments (anticoagulation, thrombolysis and surgical embolectomy) [8]. Multivariate analysis revealed a clear advantage of thrombolysis compared to heparin anticoagulation with an odd ratio of 4.83 (95% CI 1.52-15.36). Similarly, surgical embolectomy appeared favorable with a OR of 2.61 (95% CI 0.90-7.58). While the latest European recommendations have not removed this ambiguity on the optimal treatment of emboli associated with intracardiac masses, they have had the merit of underlining the need for urgent treatment [9].

Untreated mortality is 80 to 100% [2]. The complete disappearance of thrombi within 2 to 24 hours after thrombolysis can reach 100% [8].

the generalization of ultrasound scanners in the emergency and resuscitation departments as well as the training of practitioners should make it possible to diagnose thrombosis of the right heart chambers more early and, more generally, the existence of an acute pulmonary heart [10].

Conclusion:-

Thrombosis of the right cavities is rare, it concerns 4% of pulmonary emboli; Heparin alone is insufficient in these patients, even when the clinical condition is stable. Treatment may involve either surgical thrombectomy or intravenous thrombolysis. Therapeutic diagnosis and management is an emergency, because if not treated in time, the mortality is 80 to 100%.

Conflict Of Interest

The authors declare no competing interest.

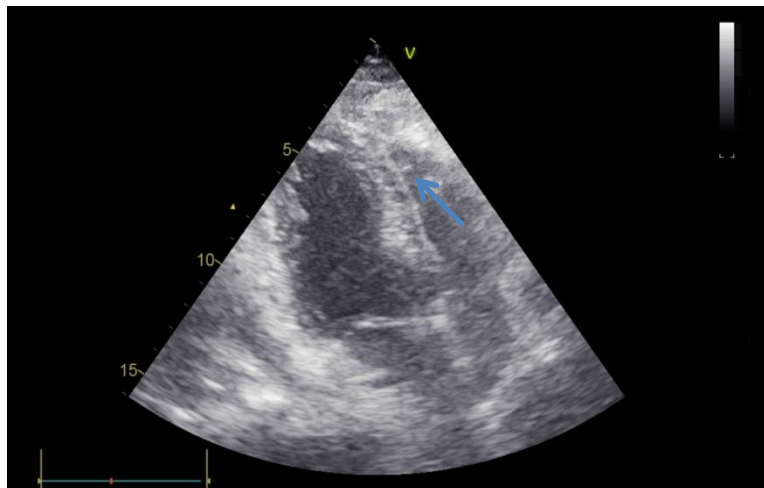


Figure 1:-echocardiographic image showing an intracavitary thrombus in the right ventricle

References:-

1. Torbicki A, Galie N, Covezzoli A, Rossi E, De Rosa M, Goldhaber SZ. Right heart thrombi in pulmonary embolism: results from the International Cooperative Pulmonary Embolism Registry. *J Am Coll Cardiol* 2003;41:2245–51.
2. Rose PS, Punjabi NM, Pearse DB. Treatment of right heart thromboemboli. *Chest* 2002;121:806–14.
3. Burns KE, McLaren A. Catheter-related right atrial thrombus and pulmonary embolism: a case report and systematic review of the literature. *Can Respir J J Can Thorac Soc* 2009;16(5):163–5.
4. Choi H, Kim D-H, Sun BJ, Kim J-S, Yang J, Kim S-M, et al. A case of carbon monoxide poisoning with thrombus in right atrium. *J Cardiovasc Ultrasound* 2012;20(4):205–8.

5. European Working Group on Echocardiography. The European Cooperative Study on the clinical
6. Rose PS, Punjabi NM, Pearse DB. Treatment of right heart thromboemboli. *Chest* 2002;121:806–14.[7] Mollazadeh R, Ostovan MA,
7. Pierre-Justin G, Pierard LA. Management of mobile right heart thrombi: a prospective series. *Int J Cardiol* 2005;99:381–8.
8. Ferrari E, Benhamou M, Berthier F, Baudouy M. Mobile thrombi of the right heart in pulmonary embolism: delayed disappearance after thrombo-lytic treatment. *Chest* 2005;127(3):1051–3
9. Konstantinides SV, Torbicki A, Agnelli G, Danchin N, Fitzmaurice D, Galiè N, et al. Task Force for the Diagnosis and Management of Acute Pulmonary Embolism of the European Society of Cardiology (ESC). 2014 ESC guidelines on the diagnosis and management of acute pulmonary embolism. *Eur Heart J* 2014;35(43):3033–69 [3069a–3069k]
10. L. Pellegrini a,*, Y. Le Dolley b, B. Marot a, A. Riberi c, M. Bellezza a, F. Kerbaul ; Interest of echocardiography in the diagnosis and monitoring of a pulmonary embolism complicating a freefloating thrombus in right heart cavities ; 2012 Published by Elsevier Masson SAS on behalf of the French Anesthesia and Resuscitation Society (Sfar).