



ISSN NO. 2320-5407

Journal homepage: <http://www.journalijar.com>

INTERNATIONAL JOURNAL
OF ADVANCED RESEARCH

RESEARCH ARTICLE

EFFECT OF LEAD ACETATE ON AREA OF ENDOMETRIUM OF MICE UTERUS AND THE PROTECTIVE ROLE OF GARLIC EXTRACT

Naureen Waseem¹ and Shadab Ahmed Butt²

1. Post Graduate Trainee, Army Medical College, Rawalpindi, (NUST).

2. Head of Anatomy Department, Army Medical College, Rawalpindi (NUST).

Manuscript Info

Manuscript History:

Received: 16 August 2013

Final Accepted: 23 August 2013

Published Online: September 2013

Key words:

Garlic extract, Lead acetate.

Abstract

Objective

The study was conducted to evaluate the effect of lead acetate on the histology of area of uterine endometrium and the protective role of garlic extract in an animal model.

Study Design

Laboratory based Randomized Control Trial

Place and duration of study

Department of Anatomy, Army Medical College in collaboration with National Institute of health from April—June 2013

Material and Methods

Thirty female BALBc mice were selected. 10 animals were placed in each group. Group A being the control was given normal diet. Group B was given lead acetate at a dose of 30mg/kg/day. Group C was given lead acetate 30mg/kg/day and garlic extract 500mg/kg/day through oral gavage tube for 60 days. Animals were sacrificed and dissected at the end of 60 days. Right uterine horn was processed, embedded and stained for histological study.

Area of endometrium was measured by using the Motic images Plus 2.0 ML software.

Results

There was increase in area of endometrium of uterus in group B when compared to Group A. The area of endometrium was relatively reduced in group C when compared with group B. In group C results were near to Group A.

Conclusion

The area of endometrium was markedly affected in lead acetate treated group which improved when treated with garlic extract.

Copy Right, IJAR, 2013. All rights reserved.

Introduction

Lead is an environmental and industrial pollutant found in almost all phases of biological systems. It is a metal which has been associated with human activities since 200 BC. Health risks due to lead toxicity are one of the world's current problems.

From the view point of human reproduction, lead is known to cause a number of adverse consequences in both men and women. The female reproductive system and, therefore human fertility may be affected by exposure to environmental toxicants. Lead is even found in some popular brands of lipsticks. The

amount of lead present in lipsticks is six times the amount found in candy, approved by FDA. According to Neman (2008) most lipsticks contain lead. She reported that chance of breast cancer increases with increasing dose of lead in lipsticks. Lead poisoning due to occupational exposure is very common in adults leading to reversible changes in mood and personality (Dhir and Dhand, 2010). Depending on the level of exposure, lead can adversely affect the central nervous system, renal function, immune system, genital and cardiovascular system. Lead poisoning is defined by the American

Academy of Pediatrics as blood lead levels higher than 10µg/dl (Ragan and Turner, 2009). Same levels were considered as a cause of concern by World Health Organization (Barbosa *et al.*, 2005).

Lead being one of the reproductive toxicant, can affect the gonadal structure and functions and can cause alterations in fertility (Qureshi and Sharma, 2012). Most of the available literature is related to the action of lead on male subjects. The effects on the physiology, histomorphology, development and biomarkers have been observed on different organs of animals and humans. In most of the previous studies, the harmful effects of lead were noted (Eugenia *et al.*, 2009; Yousaf and Abdullah, 2010; Ait *et al.*, 2009)

For centuries fruits and vegetables have attributed to beneficial health effects. In recent years, research work threw light on the use of plants on the reproductive health of man and animals (Raji *et al.*, 2012). Garlic (*Allium Sativum*) is one of the studied plants, with a long history of therapeutic use. Health benefits of garlic have been extensively reported (Sharma *et al.*, 2010; Asadaq and Inamdar, 2010). It exhibits antioxidant properties due to rich organosulphur compounds. Data suggests that antioxidants have an important role in abating some hazards of lead.

Reports on the effects of garlic on female reproductive system are yet to be established (Raji *et al.*, 2012). The rationale of current study is to observe the effects of lead acetate on female reproductive organs and the protective role of garlic extract.

Material and Methods

This laboratory based randomized controlled trial was conducted in the Department of Anatomy, Army Medical College Rawalpindi, in collaboration with National Institute of Health (NIH), Islamabad from April—June 2013. The experiment was carried out with permission of ethical committee on animal experiments, of the Army Medical College, Rawalpindi.

The animals were randomly divided into three equal groups using random number table. Thirty female BALB/c mice weighing 25-27 grams were used in the experiment and were housed in controlled environment of Animal house of NIH, Islamabad. Mice were fed with NIH laboratory diet for two months.

Animals in group A served as Control and were fed on normal diet. Mice in experimental group B were given lead acetate at a dose of 30 mg/kg body weight once daily for two months by oral gavage tube. Animals in group C were given lead acetate at a dose of 30mg/kg body weight once daily along with garlic extract 500 mg/kg through oral gavage tube once daily for two months.

At the end of 60 days, the animals were anaesthetized by placing ether soaked cotton in the jar. The animals were placed on a clean sheet of paper on a dissecting board. The midline incision was made on the skin of the abdomen by scalpel. The flaps in the body wall were spread open by making lateral incisions and were pinned back to expose the organs. Right uterine horn was removed and was placed in 10 percent formalin in duly labeled plastic containers. Then the uterine horn was processed and embedded. Tissues were cut into 5 microns thick sections using rotary microtome. The sections were stained with autostainer with Hematoxylin and Eosin (H&E) for routine histological study of uterus.

Histopathological study

Area of the endometrium

Area of the endometrium was calculated by using the Motic images Plus 2.0 ML software. The software was properly calibrated for X4 objective with the calibration slide provided with the microscope Model: DMB 3.223. The slides of the endometrium were then focused on the screen. Capture command was selected for taking images of the slides using motic live imaging module. The images were automatically transferred and saved in the computer. The images were properly zoomed in to focus the area of interest. After that the “irregular” tool was selected for measurement of area. The luminal area was outlined on the luminal surface of the endometrium and marked as area 1. The “irregular” tool was again selected to mark the border of the endometrium at the junction with myometrium and marked as area 2. The area of the endometrium was then calculated by subtracting the area 1 from area 2. The final reading was recorded as the area of the endometrium for that slide (Qamar, 2011).

Statistical analysis

The data was analyzed by using statistical package for social services (SPSS) version 18. Descriptive statistics were used to describe the results. The significance difference was determined using ANOVA and Post Hoc Tuckey test. Results were considered significant at $p < 0.05$.

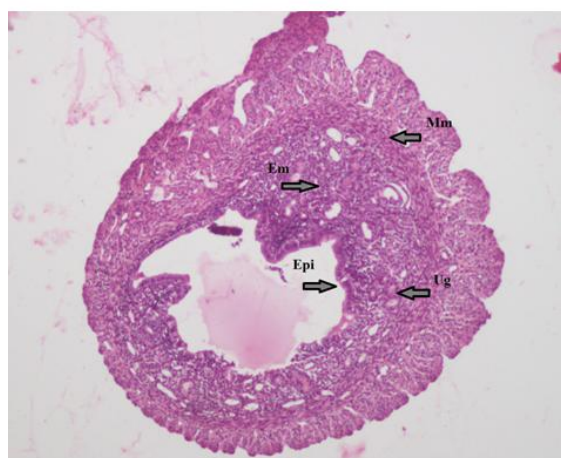
Results

The uterine wall of control group showed three layers (endometrium, myometrium and perimetrium). The endometrium consisted of simple columnar epithelium and an underlying connective tissue stroma with glands (Fig-1a). Myometrium consisted of thick inner circular layer and a thinner outer longitudinal layer of smooth muscle. Perimetrium is the outer serosal layer.

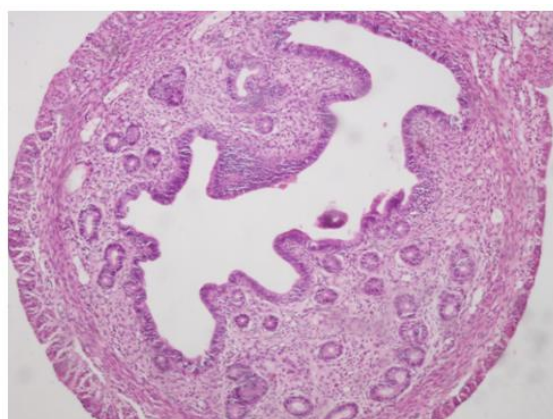
The H&E stained slides of group B showed increase in area of endometrium in animals exposed to lead in

experimental group B (fig -1b, table-1). There was increase in number and size of the uterine glands when compared to the control. The uterus sections in experimental group C showed microscopic picture that closely approximate that of the control group. The area of the endometrium was reduced when compared to experimental group B. The glands were of uniform size and reduced in number when compared to experimental group B.

Significant results were present between groups A and B regarding area of endometrium. Results were statistically insignificant when group B was compared to group C. The results of group C were not significantly different when compared with control group (table-2).



(a)



(b)

Figure- 1 Cross section of uterus of control group showing normal structure of endometrium (Em) seen in fig (a), Epi; simple columnar epithelium, Ug; uterine glands, Mm; myometrium, and increase in area of endometrium with dilated glands seen in fig (b) at 40X (H&E) in experimental group B

TABLE-1: Comparison of mean values of area of endometrium between groups

	Group A (n = 10)	Group B (n = 10)	Group C (n = 10)	p-value	Significance
Area of Endometrium	1.2518E7 ± 3.72004E6	1.9529E7 ± 4.53657E6	1.6988E7 ± 4.99966E6	0.005	< 0.05

Values were described as Mean ± SD

TABLE-2 Statistical significance of area of endometrium in control group A and experimental group B and C

	Group A vs. Group B		Group A vs. Group C		Group B vs. Group C	
	p-value	significance	p-value	significance	p-value	Significance
Area of Endometrium	0.004	< 0.05	0.081	> 0.05	0.420	> 0.05

*p-value <0.05 significant

**p-value <0.001 highly significant

Discussion

The objective of this study was to see the effects of lead acetate on the histology of area of endometrium of mice uterus and the protective role of garlic extract. In the present study lead induced histological alterations in the area of endometrium of uterus and the changes were ameliorated with administration of garlic extract. The experimental groups were compared with the control group, as well as with each other. The results of group B were compared with group C and of group A with group C. In a previous study Tchernitchin *et al.*, 2011 reported endometrial stroma edema as a result of estrogen action when rats were exposed to lead prenatally. In our study, statistically significant results on comparison of group A and group B showed that lead acetate led to endometrial hyperplasia which resulted in increase in area of endometrium. This might be due to endometrial edema or increased glandular hyperplasia. Secondly endometrial cells require a balance between estrogen and progesterone. The disturbance of this balance may lead to constant endometrial proliferation (Qamar, 2011). This may be a cause of increase rates of infertility, miscarriages, still birth and poor infant outcomes associated with exposure to lead (Qureshi and Sharma, 2012). On the other hand statistically insignificant results on comparison of group B and group C showed that garlic slightly improved the area of the endometrium histologically, but the results

were statistically insignificant when these two groups were compared. This might be due to estrogen like actions of garlic being one of the famous phytoestrogen (Sherin, 2011).

This study showed increase in area of endometrium in experimental group B as compared to control group A. After treatment with garlic extract, there was relatively decrease in area of endometrium as compared to experimental group B. Results were significant between control A and experimental group B. The results were not significantly different between experimental group C and control group A showing that lead acetate led to increase in area of endometrium which improved after co administration of garlic extract.

Conclusion

The results lead to the conclusion that persistence and exposure to lead in our environment seemed to have effects on the histomorphology of uterus which improved after treatment with garlic extract. More significant results existed when group A was compared with group B. The changes were more obvious in group B exposed to lead acetate for 2 months as compared to group C which was coexposed to garlic extract. Results between A and C were not statistically significant as the mean readings were close to each other. So it can also be concluded that garlic extract played a protective role, resulting in improvement of the tissue exposed to lead.

Acknowledgements

Authors express gratitude to Lt Col Khadija Qamar (Associate Professor, Anatomy Department, Army Medical College) for assistance and help.

References

Ait, H. N., Slimani, M., Merad, B.B. and Zaoiu, C. (2009). Reproductive toxicity of lead acetate in adult male rats. *American Journal of Scientific Research*, 3: 38-50.

Asadaq, S. M. B. and Inamdar, M. N. (2010). Pharmacodynamic and pharmacokinetic interactions of propranolol with garlic (*Allium Sativum*) in rats. *Evidence Based Complementary and Alternative medicine*, 1-11.

Barbosa, J. F., Tanus-Santos, J. E., Gerlach R. F. and Parsons, P. J. (2005). A critical review of biomarkers used for monitoring human exposure to lead: advantages, limitations and future needs.

Environmental health perspectives, 113(12): 1669-74.

Dhir, V. and Dhand, P. (2010). Toxicological approach in chronic exposure to lead on reproductive functions in female rats. *Toxicol Int.*, 17(1); 1-7.

Eugenia, D., Alexandra, T., Diana, A. and Cristina, R. T. (2009). The consequences in utero exposure to lead acetate on exposure and integrity biomarkers of reproductive system in female rats. *Medicina veterinara*, XLII(2): 295-300.

Neman, N. (2008). www.wingsandheros.com/articles/general-health-wellness-news-tips/lipstick-information-drnahid-neman-mt-sinai-hospital.html

Qamar, K. (2011). Effect of mifepristone, a progesterone antagonist on the morphology of the rat uterus. FCPS thesis, College of Physicians and Surgeons, Pakistan.

Qureshi, N. and Sharma, R. (2012). Lead toxicity and infertility in female swiss mice: A review. *Journal of Chemical, Biological and Physical Sciences*, 2(4): 1849-1861.

Ragan, P. and Turner, T. (2009). "Working to prevent lead poisoning in children: getting the lead out" *JAAPA: Official journal of American Academy of Physician Assistants*, 22(7): 40-45.

Raji, L. O., Fayemi, O. E., Ameen S. A. and Jagun, A. T. (2012). The effects of aqueous extract of *Allium sativum* (garlic) on some aspects of reproduction in the female albino rat (wister strain). *Global Veterinaria*, 8(4): 414-420.

Sharma, V., Sharma, A. and Kansal, L. (2010). The effect of oral administration of *Allium sativum* extracts on lead nitrate induced toxicity in male mice. *Food Chem Toxicol.*, 48: 928-936.

Sherin, W. (2011). Histological and ultrastructural changes in the adult male albino rat testis following chronic crude garlic consumption. *Annals of Anatomy*, 193: 134-141.

Tchernitchin, A. N., Gaete, L., Bustamante, R. and Baez, A. (2011). Effect of prenatal exposure to lead on estrogen action in the prepubertal rat uterus. *ISRN Obstret Gynecol.*, doi 10.5402/2011/329692.

Yousif, W. H. and Adbullah, S. T. (2010). Reproductive efficiency of rats whose mothers treated with lead acetate during lactation: role of vitamin E. *Iraqi Journal of Veterinary Sciences*, 24(1): 27-34.