



RESEARCH ARTICLE

Comparative Anatomical Study on The Ciliary Ganglion of Snakes (Reptilia - Squamata - Ophidia)

Ahmed I. Dakrory^{1,2} and Amel R. Omar¹

1-Department of Zoology, Faculty of Science, Cairo University

2-Department of Biology, Faculty of Science, Taif University

Manuscript Info

Abstract

Manuscript History:

Received: 12 July 2014

Final Accepted: 26 August 2014

Published Online: September 2014

Key words:

Ciliary ganglion- *Natrix tessellata*-
Coluber rogersi- *Malpolon*
monspessulana.

*Corresponding Author

Ahmed I. Dakrory

In the present study, there is a well developed ciliary ganglion. In *Natrix tessellata* and *Coluber rogersi*, this ganglion consists of two types of neurons, large ones at the periphery and smaller ones at the center. In *Malpolon monspessulana*, there is only one type of neurons; i.e., there is no regional differentiation. The ciliary ganglion in *Natrix tessellata* has two roots; radices ciliares brevis and longa, whereas in *Coluber rogersi* and *Malpolon monspessulana*, has only one root; mixed root in *Coluber* and radix ciliaris brevis in *Malpolon*. In the three species studied, there is no direct connection between the ciliary ganglion and the carotid plexus, i.e., there is no sympathetic root for the ganglion. In *Natrix tessellata* and *Coluber rogersi*, two ciliary nerves arise from the ciliary ganglion, whereas in *Malpolon monspessulana*, there is a single ciliary nerve.

Copy Right, IJAR, 2014,. All rights reserved

Introduction

The ciliary ganglion is a cranial parasympathetic ganglion that is located in the postorbital region of the head in the majority of vertebrates. Such ganglion is well represented in reptiles, birds and mammals. However, it seems to be transitory or absent to large extent in Amphibia (Norris, 1908; Kuntz, 1914; Paterson, 1939; Dakrory, 2002). Among fishes, the ciliary ganglion is either present and well developed (Freihofer, 1978; Piotrowski and Northcutt, 1996; Dakrory, 2000 & 2003; Ali and Dakrory, 2008), or totally absent (Jenkin, 1928; Chandy, 1955). In reptiles, the ciliary ganglion together with the ocular muscles and their nerves are vestigial in the blind snake *Leptotyphlops cairi* (Abdel-Kader, 2005).

Functionally, the ciliary ganglion plays a major role in both the accommodation of the eye and animal behavior (Evans and Minckler, 1938; Bullock et al., 1977; Guyton and Hall, 1996). Dakrory (2003) observed a close relation of the ciliary ganglion development and habit of the fishes. The ganglion is well developed in the diurnal and surface feeding fishes and is poorly developed in the fishes living in turbid lightless water, nocturnal fishes and bottom feeding fishes.

The nature of the ciliary ganglion and its relation in reptiles has attracted the attention of anatomists a long time ago; Haller von Hallerstein (1934), Evans and Minckler (1938), Santamaria-Arnaiz (1959), Soliman (1968), Mostafa and Hegazy (1990), Mostafa (1991) and Abdel-Kader et al. (2007). There was an obvious contradiction between the observation of Haller von Hallerstein (1934) and that of Santamaria-Arnaiz (1959) on the formation of the ganglion. So, this point needs further investigation.

The ciliary ganglion possesses two or three roots; radix ciliaris brevis (parasympathetic root) and radix ciliaris longa (sensory root) and a sympathetic root. In snakes studied, there is only the first two roots (Hegazy, 1976; Mostafa, 1990; Abdel-Kader, 2006), whereas in the snake *Eryx jaculus* (Hegazy, 1976) three roots are found.

The sympathetic connection with the ganglion in reptiles has not yet been well-defined (Soliman, 1968; Mostafa and Hegazy, 1990; Mostafa, 1991; Dakrory, 1994; Abdel-Kader, 2006; El-Bakry et al., 2007; Abdel-Kader et al., 2007). The number of the ciliary nerves arising from the ganglion varies from one to three among reptiles.

There are conflicting points of view among investigators, not only regarding the origin of the ciliary ganglion, but also in regard to the nature of its cells, the number of ganglion roots, its sympathetic connection and the number of ciliary nerves. This wide diversity in the opinions about the ciliary ganglion and its relationships seems to be a sufficient reason for the study of this subject.

From the present point of view, this study may anticipate for new anatomical evidence from ophidian to support ideas in the reptilian evolution. Also, it may help us to understand the phylogenetic relation between Ophidia and other reptiles.

MATERIALS AND METHODS

Three species of snakes from Balteem, Wadi El Natrun, were collected for this study, namely *Natrix tessellata*, *Coluber rogersi* and *Malpolon monspessulana* of family Colubridae. Two embryos of each species were fixed in Bouin's fixative for 24 hours, and were washed several days with 70% ethyl alcohol. The heads of the first two species were stained in *toto* with Grenacher's Borax carmine for three days. The heads of the three species were sectioned transversely at 12 micrometers thickness after embedding in paraffin wax. Serial sections of *Natrix tessellata* and *Coluber rogersi* were counterstained using picroindigo-carmine, while the serial sections of *Malpolon monspessulana* were stained in haematoxylin and then counter stained with eosin. The transverse sections were reconstructed in a lateral view and photographed to show the relation between the ciliary ganglion and the nerves and the other head structures.

RESULTS

Present study deals with the ciliary ganglion of three snake species of the family Colubridae. These are *Natrix tessellata*, *Coluber rogersi* and *Malpolon monspessulana*. The ciliary ganglion is a well defined ganglionic mass of cells placed posteriorly in the orbital region. It measures about 192 μm in length in the first species, about 168 μm in the second species and about 240 μm in the third one. In *Natrix tessellata* and *Coluber rogersi* the ciliary ganglion appears in the transverse sections as triangular in shape (Figs. 4 & 6, G.CL) formed of two types of neurons, large neurons at the periphery and smaller ones in the center (Figs. 1, 2, 5 & 7, LN & SN), while in *Malpolon monspessulana* the ciliary ganglion appears irregular in shape and formed of only one type of neurons (Figs. 3 & 9, G.CL).

The ciliary ganglion is located in a position surrounded by both the rectus superior muscle and the ramus superior of the nervus oculomotorius dorsally, the ramus nasalis of the nervus trigeminus dorsomedially, the ramus inferior of the nervus oculomotorius ventromedially, the rectus lateralis muscle ventrally, the nervus abducens ventrolaterally and the sclera of the eye laterally (Fig. 4, G.CL) in *Natrix tessellata*. In *Coluber rogersi*, it is located dorsal to the rectus lateralis muscle, dorsomedial to the nervus abducens, dorsolateral to the ramus inferior of the nervus oculomotorius and lateral to the ramus nasalis of the nervus trigeminus, ventromedial to the sclera of the eye and ventral to the rectus superior muscle and the ramus superior of the nervus oculomotorius (Fig. 6, G.CL). In *Malpolon monspessulana*, it lies in a position surrounded by the ramus superior of the nervus oculomotorius and the rectus superior muscle dorsomedially, the ramus inferior of the nervus oculomotorius ventromedially, the rectus lateralis muscle ventrally, the ramus nasalis of the nervus trigeminus and the eye ball ventrally (Fig. 8, G.CL).

In the first Colubrid species, the ciliary ganglion has two roots (Fig. 1, RCB & RCL), the motor (parasympathetic) root and a sensory one. The motor root (radix ciliaris brevis) arises from the ramus inferior of the nervus oculomotorius and runs forwards passing lateral to the ramus inferior of the nervus oculomotorius, dorsomedial to the rectus inferior muscle and ventromedial to the rectus superior muscle. It enters the ganglion from its ventromedial side. The sensory root (radix ciliaris longa) originates from the dorsal side of the ramus nasalis of the nervus trigeminus. It extends anterolaterally for a short distance and enters the ciliary ganglion from its posterior end. In the second species, the radix ciliaris brevis and the radix ciliaris longa reach the ciliary ganglion through a one mixed branch arises from the ventrolateral side of the ramus nasalis of the nervus trigeminus (Figs. 2 & 6, CO.BR). In the third one, the ciliary ganglion has only one motor root, the radix ciliaris brevis (Figs. 3 & 8, RCB). This root arises from the dorsolateral side of the ramus inferior of the nervus oculomotorius that extends dorsally passing dorsolateral to the latter ramus, lateral to the ramus nasalis of the nervus trigeminus and medial to the nervus abducens to enter the ganglion from its lateral side. These fibres terminate in the ganglion in synapse with the postganglionic cell bodies. The ciliary ganglion is quite touching the ramus nasalis of the nervus trigeminus, and

hence, the sensory fibres are transmitted to the ganglion through the intermingling surface between them, i.e. there is no radix ciliaris longa.

In the three species studied, there is no direct connection between the ciliary ganglion and the carotid plexus, i.e., there is no direct sympathetic root.

In *Natrix tessellata* and *Coluber rogersi*, two ciliary nerves arise from the ciliary ganglion (Figs. 1, 2, Nn.CL). These two nerves pass anterolaterally to enter the eyeball through the same foramen in its fibrous sclera. In *Malpolon monspessulana*, a single strong ciliary nerve (Fig. 3, Nn.CL) arises from the ciliary ganglion. This nerve runs anteriorly and laterally to enter the sclera of the eye through a special foramen. The ciliary nerves, in all the snakes examined, pass laterally and anteriorly to terminate into the muscles of the ciliary body and its epithelial surfaces and the choroid blood vessels.

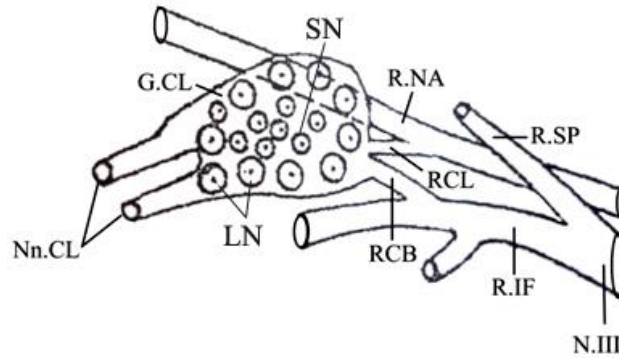


Fig. 1: Reconstruction of the ciliary ganglion of *Natrix tessellata* in a lateral view.

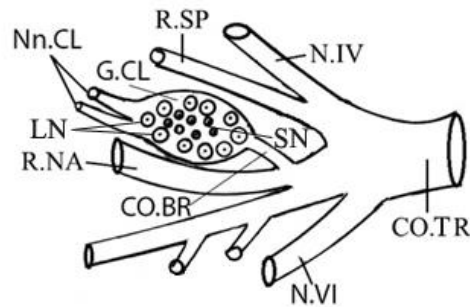


Fig. 2: Reconstruction of the ciliary ganglion of *Coluber rogersi* in a lateral view.

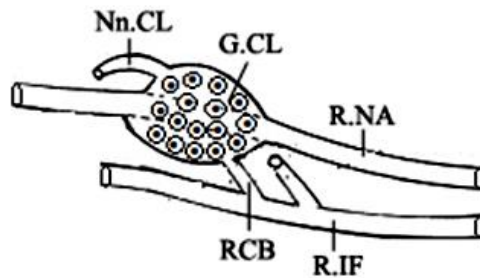


Fig. 3: Reconstruction of the ciliary ganglion of *Malpolon monspessulana* in a lateral view.

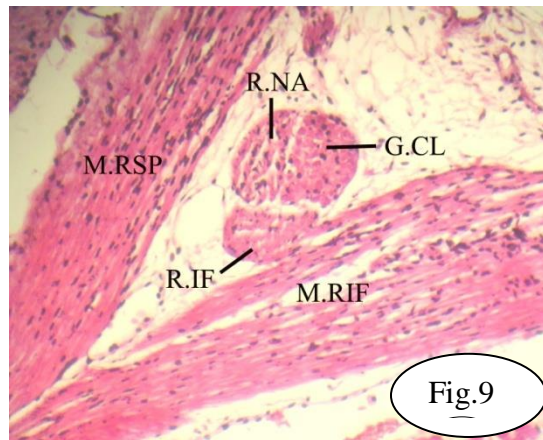
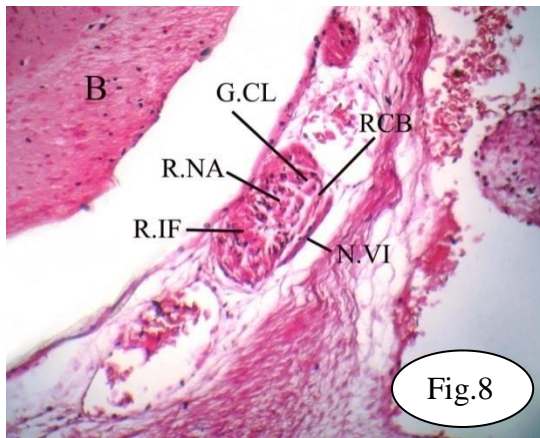
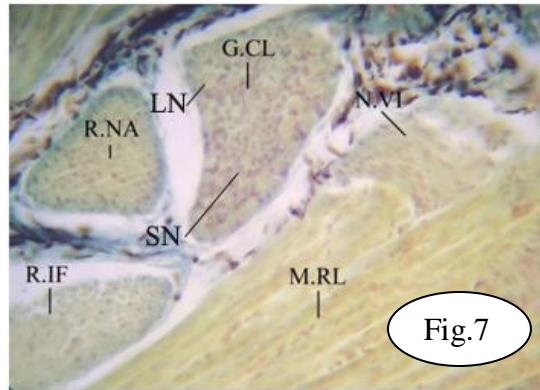
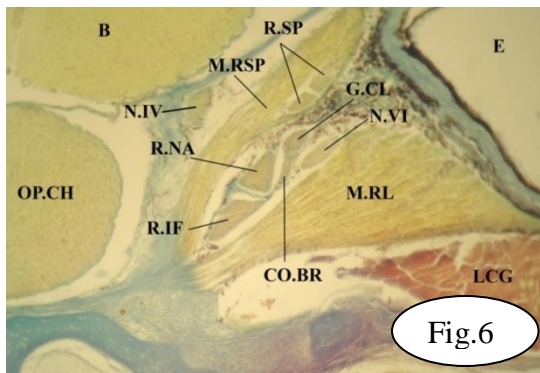
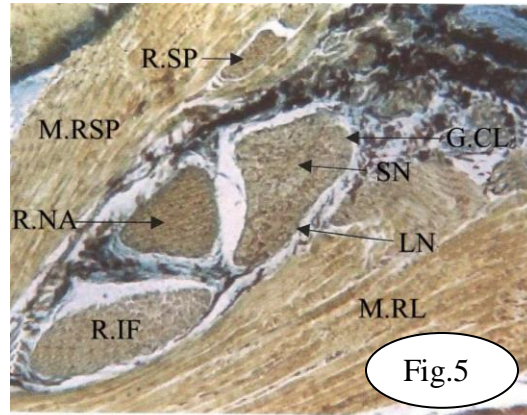
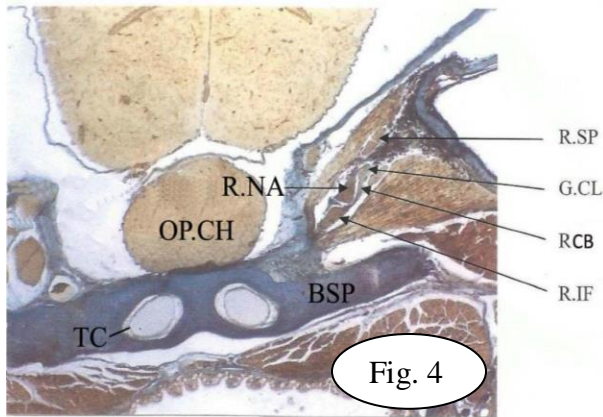


Fig. 4: Photomicrograph of a part of a transverse section of *Natrix tessellata* passing in the postorbital region showing the position of the ciliary ganglion and the radix ciliaris brevis. X 40. Fig. 5: Photomicrograph of a part of a transverse section of *Natrix tessellata* passing in the postorbital region showing the position and structure of the ciliary ganglion into two types of neurons. X 160. Fig. 6: Photomicrograph of a part of a transverse section of *Coluber rogersi* passing in the postorbital region elucidating the separation of the common branch from the ramus nasalis of the nervus trigeminus and its entering to the ciliary ganglion. X 100. Fig. 7: Photomicrograph of a part of a transverse section of *Coluber rogersi* passing in the postorbital region showing the structure of the ciliary ganglion. X 800. Fig. 8: Photomicrograph of a part of a transverse section of *Malpolon monspessulana* demonstrating the position of the ciliary ganglion and the radix ciliaris brevis. X 800. Fig. 9: Photomicrograph of a part of a transverse section of *Malpolon monspessulana*

illustrating the structure of the ciliary ganglion and its connection with the ramus nasalis of the nervus trigeminus. X800.

LIST OF ABBREVIATIONS:

B, Brain.
 BSP, Basisphenoid bone.
 CO.BR, Common branch.
 CO.TR, Common trunk.
 G.CL, Ciliary ganglion.
 LN, Large neurons.
 M.RL, Rectus lateralis muscle.
 M.INF, Rectus inferior muscle.
 M.RSP, Rectus superior muscle.
 N.III, Nervus oculomotorius.
 N.IV, Nervus trochlearis.
 N.VI, Nervus abducens.
 OP.CH, Optic chiasma.
 R.IF, Ramus inferior.
 R.NA, Ramus nasalis of the nervus trigeminus.
 R.SP, Ramus superior.
 RCB, Radix ciliaris brevis.
 RCL, Radix ciliaris longa.
 SN, Small neurons.
 TC, Trabecula crani.

DISCUSSION

According to the observed structure of the ciliary ganglion, two types of neurons are recognized; large neurons at the periphery and small ones at the center of both *Natrix tessellata* and *Coluber rogersi*, whereas the ciliary of *Malpolon monspessulana* composed of only one type of neurons. In this regard, the ganglion is thoroughly divided into two distinct regions. Such observation is the not mentioned before in the ophidians so far described. In the ophidian literature, the ciliary ganglion was found to be consisting of one structure and to be formed of one type of neurons. Galvao (1917) described the ciliary ganglion of ophidians as formed of strictly unipolar cells. Hegazy (1976) found similar results in the serpents *Psammophis sibilans*, *Eryx jaculus*, and *Cerastes vipra*. The same finding was also observed in the lacertilian studied by Abdel-Kader et al. (2007), El-Bakry et al. (2007) and Dakrory (2009). Two types of neurons was observed in the lacertilian studied by Mostafa and Hegazy (1990) and Dakrory (1994 & 2009). In this respect, Haller von Hallerstein (1934) described the ciliary ganglion of reptiles and birds confirming the existence of two parts; the first is composed of small neurons, while the second is formed of large ones. This finding was mentioned in birds by Oehme (1968), Soliman et al. (1976) and Abdel-Kader and Fathy (2000). In this context, Bullock et al. (1977) stated that, the ciliary ganglion of chick is composed of two cell populations, one controlling the smooth muscles in the choroid and the other for the iris and ciliary body. The same was mentioned by Radzimirska (2003) in the domestic turkey, *Meleagris gallopavodomesticus*.

In mammals, the ciliary ganglion is undivided into two regions in any case. These pattern structure was observed in cat (Taylor and Weber, 1969), guinea pig (Watanabe, 1972), in man (Stefani, 1972) and in both the hedgehog and bat (Hegazy and Mostafa, 1990).

In both *Natrix* and *Malpolon*, investigated, the ciliary ganglion is connected with the ramus inferior of the nervus oculomotorius by the radix ciliaris brevis, while, in *Coluber*, there is no radix ciliaris brevis and the parasympathetic fibres arising from the nervus oculomotorius reaching the ganglion through one common mixed branch. The first case was found to be the same in many ophidians and lacertilians, as stated by several authors. On the other hand, the radix ciliaris brevis is very extremely short so that the ganglion appears touching the nervus oculomotorius in *Lacerta agilis* and *Lacerta muralis* (Lenhosseck, 1912) and *Ptyodactylus hasselquistii* (Soliman, 1968; Abdel-Kader, 1990). In contrast, the ciliary ganglion is firmly attached to the ramus inferior of the nervus oculomotorius, i.e., the radix ciliaris brevis is lacking and the preganglionic parasympathetic fibres are transmitted directly to the ganglion through the intermingling surface in the geckos *Tarentola mauritanica* (Soliman and Mostafa, 1984), *Stenodactylus slevini* (Mostafa and Hegazy, 1990) and *Tropiocotes tripolitanus* (El-Bakry et al., 2007) and in the amphisbaenian *Diplometopon zarudnyi* (Dakrory, 1994).

Among birds, the preganglionic parasympathetic fibres, carried by the nervus oculomotorius are transmitted to the ciliary ganglion either through an anastomosing branch; the radix ciliaris brevis or through the

direct attachment of the ganglion to the ramus inferior of the nervus oculomotorius. The radix ciliaris brevis is mentioned in *Struthio* (Webb, 1957), in *Upopa epops* and *Passer domesticus* (Soliman et al., 1976) and in *Merops albicollis* (Abdel-Kader and Fathy, 2000). On the other hand, the ciliary ganglion is firmly attached to the ramus inferior of the nervus oculomotorius with the absence of the radix ciliaris brevis in the chick (Carpenter, 1906), in *Streptopelia senegalensis* (Soliman et al., 1976) and in *Gallinula chloropus* (Abdel-Kader, 1999).

Concerning mammals, Schwalbe (1879) reported that not all the higher vertebrates possess a short root, as it is the case in many mammals (sheep, calf, dog, rabbit), and the ganglion is situated directly on the trunk of the nervus oculomotorius. The same condition was described by Christensen (1935) in the cat, Godinho (1972) in the ruminants, Watanabe (1972) in the guinea pig, Hegazy and Mostafa (1990) in both the hedgehog and bat, Sinnreich and Nathan (1981) in the man and by Nowak et al. (2004) in the Egyptian spiny mouse, *Acomys cahirinus*. In the baboon *Papio cenocephalus*, on the other hand, the ciliary ganglion receives two branches from the ramus inferior (Gasser and Wise, 1972).

Among fishes, the preganglionic parasympathetic fibres of the nervus oculomotorius are transmitted to the ciliary ganglion by branch, i.e., the radix ciliaris brevis in *Lampancyctus teucopsorus* (Ray, 1950), *Pseudorhombus arsius* (Marathe, 1955) *Polypterus senegalus* (Piotrowski and Northcutt, 1996) and in *Tilapia zillii* (Dakrory, 2003; Ali, 2005). On the other hand, such fibres are transmitted directly to the ganglion through the intermingling surface between them, i.e., no radix ciliaris brevis in *Polycentrus schomburgkii* (Freihofer, 1978), *Trichiurus lepturus* (Harrison, 1981), *Ctenopharyngodon idellus* (Dakrory, 2000) and in both *Mugilcephalus* and *Gambusia affinis affinis* (Dakrory, 2003).

In *Natrix* species, the ciliary ganglion is connected with the ramus nasalis of the nervus trigeminus by the radix ciliaris longa. This was found in the snakes *Psammophis sibilans* and *Cerastes vipera* (Hegazy, 1976), *Psammophis schokari* and *Spalerosophis diadema* (Mostafa, 1990) and *Telescopus dhara* (Abdel-Kader, 2006). The same finding was also found in the lizards *Lacerta viridis*, *Acanthodactylus boskiana*, *Agama mutabilis* and *Mabuya quinquetaeniata* (Soliman, 1968), *Agama pallida* (Soliman et al., 1984), *Agama sinaita*, *Stenodactylus slevini* and *Eumeces schneidri* (Mostafa and Hegazy, 1990) and *Varanus griseus* (Dakrory, 2009). In the gecko *Gymnodactylus kotschy* (Evans & Minckler, 1938), in the amphisbaenian *Diplometopon zarudnyi* (Dakrory, 1994) and in *Uromastix aegypticus* (Dakrory, 2009), however, the radix ciliaris longa joins both the ciliary ganglion and the ciliary nerve distal to the ganglion. Again in the lizard *Chalcides ocellatus* (Soliman & Hegazy, 1969) and the snake *Eryx jaculus* (Hegazy, 1976), the radix ciliaris longa occupies a small area in the dorsal side of the ciliary ganglion. It passes across the ganglion then turns to enter the ciliary nerve. However, Santamaria-Arnaiz (1959) and Dakrory (2009), dealing with *Chalcides ocellatus* and *Sphenops sepesoides* respectively, stated that the radix ciliaris longa passed in contact with the ciliary ganglion but did not enter it. Also, Osawa (1898) found that the radix ciliaris longa did not enter the ganglion, but it joined the ciliary nerves in *Hatteria punctata*. In *Coluber rogersi*, the microscopic examination of the serial transverse sections reveals that the ciliary ganglion is connected with the ramus nasalis after its releases from the common trunk through a mixed branch separates from it. This branch carries two types of fibres; the parasympathetic fibres from the nervus oculomotorius and the viscerosensory fibres from the nervus trigeminus. The parasympathetic fibres (parasympathetic root of ciliary ganglion) that originated in the brain and leaves it in the nervus oculomotorius and transfers to the ramus nasalis of the nervus trigeminus at the fusion between them. These fibres are carried from the ramus nasalis to ciliary ganglion together with the sensory fibres originating in the Gasserian ganglion (radix ciliaris longa= sensory root of the ciliary ganglion) by one common mixed branch. In *Malpolon monspessulana* investigated, the ciliary ganglion is quite touching the ramus nasalis of the nervus trigeminus and the sensory fibres are transmitted to the ganglion by the intermingling surface between them, i.e. there is no radix ciliaris longa.

In birds, no direct connection appears to exist between the ciliary ganglion and the ramus ophthalmicus. Such connection, however, is carried out between the latter ramus and the ciliary nerves distal to the ganglion. This appears to be common in birds; as described by Soliman et al. (1976). However, a direct connection between the ramus ophthalmicus and the ciliary ganglion were described. It was mentioned in *Struthio* (Webb, 1957), *Upopa epops* (Soliman et al., 1976) and in *Merops albicollis* (Abdel-Kader and Fathy, 2000). On the other hand, Bonsdroff (1952) described, for the corona, two rami from the nervus trigeminus, which have the typical relations of the long root (radix ciliaris longa) of the ganglion.

In mammals, the sensory fibres are carried to the ciliary ganglion through the ramus ophthalmicus of the trigeminal nerve. In the rhesus monkey (Christensen, 1933), and in both the hedgehog *Hemiechinus auritus* and in the bat *Rhossellus aegyptiacus* (Hegazy and Mostafa, 1990), the ganglion receives sensory fibres constituting its sensory root via a branch which connects it with the long ciliary nerve of the nasociliary branch. The communicating branch, i.e., the sensory root, however, is directly given off from the nasociliary branch in the rhesus monkey (Kuntz, 1933), in domestic ruminants (Godinho and Getty, 1971) and in the baboon (Gasser and Wise, 1972).

However, there is no direct connection between the ciliary ganglion and the nasociliary branch in the cat (Dupas, 1924; Christensen, 1935) and in the rhesus monkey (Bast, 1933) and hence the so-called sensory root of the ganglion is not found. In such species, the connection, however, is carried out between the long ciliary nerve of the nasociliary branch and one of the short ciliary nerves arising from the ganglion. At the point of union between the long and the short ciliary nerves distal to the ganglion, accessory ciliary ganglia are usually found, as stated by Christensen (1935).

A connecting branch between the ciliary ganglion and the ramus maxillaris of the trigeminal nerve was recorded in several mammalian species. It was described in the ox by Mobillio (1912), in the baboon by Gasser and Hendricks (1969) and in the goat, sheep and ox by Godinho and Getty (1971). Only, Mobillio (1912) considered such a branch as a sensory root entering the ciliary ganglion, in addition to another root originating from the nasociliary branch. Schawlbé (1879) did not find any connection between the ciliary ganglion (ganglion oculomotorius) and the nervus trigeminus in several vertebrate species. Jegorow (1887), however, asserted that such a connection is constant and necessary for the existence of the ganglion, throughout the vertebrate series. On the other hand, Holtzmann (1896) found that the ciliary ganglion in amphibians, birds and mammals is more intimately connected with the nervus oculomotorius than with the trigeminal one.

From the above discussion, it is thoroughly evident that both roots; radix ciliaris brevis and radix ciliaris longa, communicate, for the most part, with the ganglion separately. This was also the case found in the bony fish *Tilapia zilli* (Dakrory, 2003). This is in contrast to the condition found in *Varanus griseus* of this study, where both the radix ciliaris brevis and radix ciliaris longa are fused just posterior to the ganglion. This is the case found in the cyprinid fish *Ctenopharyngodon idellus* (Dakrory, 2000).

In the three species studied, there is no sympathetic connection with the ciliary ganglion or with the ciliary nerves. Among reptiles this condition is variable. The present results is in agreement with the finding of Auen and Langebartel (1977) in the two colubrid snakes *Elaphe obsoleta* and *Thamnophis ordinoides*, Mostafa (1990) in the snake *Spalerosophis diadema*, Weber (1877) in the lizards *Lacerta viridis* and *Lacerta ocellata*, Lenhossék (1912) in *Lacerta muralis*, Soliman (1968) in the lizards *Acanthodactylus boskiana* and *Lacerta viridis*, Mostafa and Hegazy (1990) in the agamid *Agama sinaita* and gecko *Stenodactylus slevini*, Soliman (1964) in the chelonians *Chelydra serpentina* and *Chelone imbricata*. On the other hand, the sympathetic connection with the ciliary ganglion was found in the snake *Eryx jaculus* (Hegazy, 1976). Among Lacertilia, the same was mentioned in the lizards *Gymnodactylus kotschi* (Evans & Minckler, 1938), *Ptyodactylus hasselquistii* and *Mabuya quinquetaeniata* (Soliman, 1968), *Tarentola mauritanica* (Soliman & Mostafa, 1984) and *Eumeces schneideri* (Mostafa & Hegazy, 1990), in *Acanthodactylus boskianus* (El-Ghareeb, 1997), in *Sphenops sepsoides* and *Varanus griseus* (Dakrory, 2009). It is also found in the chelonian *Trionyx japonicus* (Ogushi, 1913). However, a sympathetic connection is established with the ciliary nerve distal to the ganglion in the ophidians *Psammophis sibilans* and *Cerastes vipera* (Hegazy, 1976). It is also mentioned in the lizards *Agama mutabilis* (Soliman, 1968) *Chalcides ocellatus* (Soliman & Hegazy, 1969), *Agama pallida* (Soliman et al., 1984), in the amphibia *Diphmetopon zarudnyi* (Dakrory, 1994) and in *Uromastix aegyptius* (Dakrory, 2009).

Among fishes, such connection, i.e., sympathetic root, appears to be found in most bony fishes (Dakrory, 2003; Ali, 2005).

In birds, there is no connection between the ciliary ganglion or the ciliary nerves and the internal carotid plexus. This was confirmed by several authors as Webb (1957), Oehme (1968), Soliman et al. (1976) and Abdel-Kader and Fathy (2000). Thus, it can be stated that the absence of the sympathetic root is a common character among birds so far described.

In this respect, the condition observed in birds is quite different from that in mammals. Kurus (1956) stated that, the sympathetic connection (Sympathetic root) between the ciliary ganglion and the carotid plexus is, generally, present in mammals. The sympathetic root of the ganglion was described by Winkler (1932) in the rhesus monkey, Taylor and Weber (1969) in the cat and by Hegazy and Mostafa (1990) in the hedgehog and the bat. However, Lenhossék (1912) mentioned that the sympathetic root may be absent in human being. This root was found to be absent in the ox (Schachtschabel, 1908) and in the goat, sheep and ox (Godinho and Getty, 1971). On the other hand, Cunningham (1931) and Kuntz (1934) mentioned that the sympathetic root of the ganglion in man may or may not be incorporated with the nasociliary branch.

In *Natrix tessellata* and *Coluber rogersi* studied, there are two ciliary nerves arising from the ciliary ganglion, while in *Malpolon monspessulana*, there is one strong nerve. The number of the ciliary nerves is variable in the vertebrates. Among reptiles, the number ranges from one to three. One ciliary nerve was found in the snakes *Psammophis sibilans* and *Eryx jaculus* (Hegazy, 1976), *Coluber elegantissimus*, *Psammophis schokari* and *Spalerosophis diadema* (Mostafa, 1991). The same was present in the lizards *Chalcides ocellatus* (Santamaria-Arnaiz, 1959; Soliman & Hegazy, 1969), *Ptyodactylus hasselquistii*, *Acanthodactylus boskiana* and *Lacerta viridis*

(Soliman, 1968) and *Uromastix aegyptius* and *Sphenops sepsoides* (Dakrory, 2009). One ciliary nerve was also found in the amphisbaenian *Diplometopon zarudnyi* (Dakrory, 1994). There are two nerves in the viper *Cerastes vipera* (Hegazy, 1976) and in the lizards *Varanus bivittatus* (Watkinson, 1906), *Anolis carolinensis* (Willard, 1915), *Mabuya quinquetaeniata* and *Agama mutabilis* (Soliman, 1968), *Tarentola mauritanica* (Soliman & Mostafa, 1984), *Agama pallida* (Soliman et al., 1984), in all the lizards examined by Mostafa and Hegazy (1990) and in *Varanus griseus griseus* (Dakrory, 2009). Also, two ciliary nerves were found in the chelonians *Chelydra serpentina* and *Chelone imbricata* (Soliman, 1964). Three nerves were present in the gecko *Gymodactylus kotschy* (Evans & Minckler, 1938).

Among birds, the number of the ciliary nerves varies from species to another. Schwalbe (1879) mentioned that the number of the ciliary nerves may vary from one (e.g., hen, owl and goose) to seven (e.g. parrots). One ciliary nerve was detected in the chick (Carpenter, 1906) and also in *Merops albicollis* (Abdel-Kader and Fathy, 2000). However, Seto (1931) found five ciliary nerves in the chick. Two ciliary nerves were present in *Streptopelia senegalensis* (Soliman et al., 1976) and in *Meleagris gallopavo domesticus* (Radzimirska, 2003) three ciliary nerves were found in *Passer domesticus* (Soliman et al., 1976) and in *Gallinula chloropus* (Abdel-Kader, 1999). Four ciliary nerves were found in the crow (Oehme, 1968) and in *Upupa epops* (Soliman et al., 1976) and five nerves were found in *Struthio* (Webb, 1957).

The number of the ciliary nerves arising from the ciliary ganglion is also variable among mammals. Two ciliary nerves were found in the cat by Taylor and Weber (1969) and in the baboon by Gasser and Wise (1972). Three ciliary nerves were found in *Hemiechinus auritus* and four ones in *Rhosettus aegypticus* arising from the ciliary ganglion as mentioned by Hegazy and Mostafa (1990). Four to five ciliary nerves were present in the rhesus monkey (Bast, 1933; Kuntz, 1933). Twelve to fifteen ciliary nerves were found in man by Cunningham (1931).

From the above mentioned discussion, it is obvious that, there are differences in the ciliary ganglion of the studied species, concerning the structural relations, the number of ciliary nerves and the number of ciliary roots. Although, there is one ciliary nerve in *Malpolon monspessulanayet* this nerve is large and stout. Thus we can conclude that, although there is a specific variation regarding the ciliary ganglion yet it is at an intermediate rank between Amphibia and fishes from one side and the birds and mammals from the other side.

REFERENCES

- Abdel-Kader, I.Y. (1990):** Anatomical studies on the cranial nerves of the lizards *Agama pallida* and *Ptyodactylus hasselquistii*. Ph.D. Thesis, Fac. Sci. Cairo Univ. Egypt.
- Abdel-Kader, I.Y. (1999):** The cranial nervus of *Gallinula chloropus*. The eye muscle nerves and ciliary ganglion. J. Union Arab Biol., 12(A): 197-216.
- Abdel-Kader, I.Y. (2006):** The cranial nerves of the cat snake *Telescopus dhara* (Colubridae, Ophidia): I.The eye muscle nerves and the ciliary ganglion. J Egypt Ger Soc Zool., 50(B): 1-16.
- Abdel-Kader, I.Y. and Fathy, S.M. (2000):** The cranial nerves of the bee eater, *Merops albicollis* (Meropidae, Coraciiformes). The eye muscle nerves and the ciliary ganglion. J. Egypt. Ger. Soc. Zool., 34: 141-163.
- Abdel-Kader, T.G. (2005):** Anatomical studies on the blind snake *Leptotyphlops cairi* (Family: Leptotyphlopidae). Ph.D. Thesis, Helwan Univ., Egypt.
- Abdel-Kader, T.G.; and Shamakh, A.A. and Dakrory, A.I. (2007):** The cranial nerves of *Mabuya quinquetaeniata*. I. The eye muscle nerves and the ciliary ganglion. Egypt J Zool., 49: 193-209.
- Ali, R.S. (2005):** Comparative anatomical studies on the cranial nerves of the embryo of *Tilapia zillii*. Ph.D. Thesis, Fac Sci, Helwan Univ.
- Ali, R.S. and A.I. Dakrory, (2008):** Anatomical studies on the cranial nerves of *Alticus kirkii magnosi*. 1- The eye muscle nerves and ciliary ganglion. Egypt J Zool., 51: 113-132.
- Auen, E.D. and Langebartel, D.A. (1977):** The cranial nerves of the colubrid snakes *Elaphe* and *Thamnophis*. J. Morph., 154: 205-222.
- Bast, T.H. (1933):** The anatomy of the rhesus monkey (*Macaca mulatta*): The eye and the ear. Hafner publishing Co., New York.

- Bonsdorff, E.J. (1952):** Symbolae ad anatomiam compartum nervorum animalium vertebratorum. 1- Nervi cerebrales *Corvi cornices*. 2- Nervi cerebrales *Gruis cinereae*. Acata. Soc. Sci. Fenn-Helsingforsiae, 3: 505-569, 591-624.
- Bullock, T.H., Orkand, R. and Grinnell, A. (1977):** Introduction to the Nervous System. W.H. Freeman and Company, USA.
- Carpenter, F.W. (1906):** The development of the oculomotor nerve, the ciliary ganglion, and the abducens nerve in the chick.. Bull. Mus. Comp. Zool., 48: 139-230.
- Chandy, M. (1955):** The nervous system of the Indian sting-ray *Dasyatis rafinesque*(Trygon cuvier). J Zool Sci India, 7(1): 1-12.
- Christensen, K. (1933):** The anatomy of the rhesus monkey (*Macaca mulatta*): The cranial nerves. Hafner publishing Co. New York.
- Christensen, K. (1935):** Sympathetic and parasympathetic nerves in the orbit of the cat. J. Anat., 70: 225-234.
- Cunningham, J. (1931):** Textbook of anatomy. Oxford Univ. Press, Oxford.
- Dakrory, A.I. (1994):** Anatomical studies on the cranial nerves of the Amphisbaenian (*Diplometopon zarudnyi*). M.Sc. Thesis, Fac. Sci. Cairo Univ. Egypt.
- Dakrory, A.I. (2000):** Comparative anatomical studies on the cranial nerves of *Rhinobatus halavi* (Class: Chondrichthyes) and *Ctenopharyngodon idellus* (Class: Osteichthyes). Ph.D. Thesis, Fac. Sci., Cairo Univ., Egypt.
- Dakrory, A.I. (2002):** The cranial nerves of *Rana bedriagie* (Amphibia, Anura, Ranidae). I. The eye-muscle nerves and the ciliary ganglion. Egypt. J. Zool., 39: 395-409.
- Dakrory, A.I. (2003):** The ciliary ganglion and its anatomical relations in some bony fishes. Egypt J Zool., 41: 1-13.
- Dakrory, A.I. (2009):** Comparative Anatomical Study on The Ciliary Ganglion of Lizards (Reptilia-Squamata-Lacertilia). Australian Journal of Basic and Applied Sciences, 3(3): 2064-2077, 2009.
- Dupas, J.H.L. (1924):** "Contribution a L'tude et histologique du ganglion ophthalmique chez L'homme et divers animaux". These, Faculte de Medecine et de Pharmacie Universte de Bordeaux, French.
- El-Bakry, A.M., Shamakh, A.A. and Dakrory, A.I. (2007):** the cranial nerves of the gecko *Tropiocolotes tripolitanus*. I. the eye muscle nerves and the ciliary ganglion. Egypt J Zool., 49: 361-379.
- El-Ghareeb, A.A. (1997) :** Anatomical studies on the cranial nerves of the lizard *Acanthodactylus boskianus* (Daud). Ph.D. Thesis, Fac. Sci., Cairo Univ., Egypt.
- Evans, L.T. and Minkler, J. (1938):** The ciliary ganglion and associated structure in the gecko, *Gymnodactylus kotschyi*. J Comp Neurol., 69: 303-314.
- Freihofer, W.C. (1978):** Cranial nerves of a percoid fish, *Polycentrus schomburgkii* (Family: Nandidae), a contribution to the morphology and classification of the order Perciformes. Occ Pap Calif Acad Sci., 128: 1-75.
- Galvao, J.M.A. (1917):** The finer structure of the ciliary ganglion of ophidians. Anat. Rec., 13: 437-442.
- Gasser, R.F. and Hendrickx, A.G. (1969):** The development of the trigeminal nerve in baboon embryos (*Papio* sp.). J. Comp. Neurol., 136: 159-182.
- Gasser, R.F. and Wise, D.M. (1972):** The trigeminal nerve in baboon. Anat. Rec., 172: 511-522.
- Godinho, H.P. (1972):** Gross anatomy of the parasympathetic ganglia of the head in domestic Artiodactyla. Arq.Esc. Vet. Univ. Fed. Minas Gerais, 22: 129-139.

- Godinho, H.P. and Getty, R. (1971):** The branches of the ophthalmic and maxillary nerves to the orbit of goat, sheep and ox. *Arq.Esc. Vet.*, 23: 229-241.
- Guyton, A.C. and Hall, J.E. (1996):** Textbook of Medical Physiology, 9th Ed., Arthur C. Guyton, John E. Hall, WB Saunders, USA.
- Haller von Hallerstein, V. (1934):** Anatomie der Wirbeltiere 2/1, herausgegeben von Bolk, Göppert, Kallius, Lubosch. Berlin und Wien
- Harrison, G. (1981):** The cranial nerves of the teleost *Trichiurus lepturus*. *J Morphol.*, 167: 119-134.
- Hegazy, M.A. (1976):** Comparative Anatomical studies on the cranial nerves of Ophidia. Ph.D. Thesis, Fac. Sci., Cairo Univ. Egypt.
- Hegazy, M.A. and Mostafa, R.H. (1990):** Studies on the ciliary ganglion and its anatomical relationships in the Hedgehog *Hemiechinus auritus* (Insectivora) and the Bat *Rhossusaegyptiacus* (Chiroptera). *Proc. Zool. Soc. A.R. E.*, 19: 51-70.
- Holtzmann, H. (1896):** Untersuchungen Über Ciliarganglion und Ciliarnerven. *Morph. Arbeit.*, 6: 114-142.
- Jegorow, J. (1887):** Recherches anatomophysiologiques sur le ganglion ophthalmique. *Arch. Slav. Biol.*, 3: 50-129, 322-345.
- Jenkin, P.M. (1928):** Note on the sympathetic nervous system of *Lepidosiren paradoxa*. *Proc Roy Soc London*, 7: 56-69.
- Kuntz, A. (1914):** Further studies on the development of cranial sympathetic ganglia. *J. Comp. Neurol.*, 24: 235-267.
- Kuntz, A. (1933):** Autonomic nervous system. Lea and Febiger, Philadelphia.
- Kuntz, A. (1934):** Nerve fibres of spinal and vagus origin associated with the cephalic sympathetic nerves. *Ann. Otol. Rhinol. and Laryng.*, 43: 50-66.
- Kurus, E. (1956):** Über die Morphologie des Ganglion Ciliare. *Klin. Monatsbl. Augenheilk.*, 129-145.
- Lenhossek, M.V. (1912):** Das Ciliarganglion der Reptilian. *Anat. Anz.*, 40: 74-80.
- Marathe, V.B. (1955):** The nervous system of *Pseudorhombus arsius* (H.B.). *J Bombay Univ* 23(B3): 60-73.
- Mobilio, C. (1912):** Ricerche anatomo-comparate Sull innervazione del muscolo piccolo obliquo dell'occhio ed appunti Sulle radici del ganglio oftalmico nei mammiferi: innervazione del muscolo accessorio del grande obliquo nell'asino. *Monit. Zool. Ital.*, 23: 80-106.
- Mostafa, R.H. (1990):** The cranial nerves of serpent, *Spalerosophis diadema*. I- Eye-muscle nerves and the ciliary ganglion. *Egypt J. Anat.*, 13 (2): 59-73.
- Mostafa, R.H. (1991):** On the ciliary ganglion of Ophidia (Squamata: Reptilia). *Proc. Egypt. Acad. Sci.*, 41: 131-142.
- Mostafa, R.H. and Hegazy, M.A. (1990):** Comparative study on the ciliary ganglion of some lizards. *Proc. Egypt. Acad. Sci.*, 40: 139-146.
- Norris, H.W. (1908):** The cranial nerves of *Amphiuma means*. *J. Comp. Neurol.*, 18: 527-568.
- Nowak, E., Kuder, T., Szczyrkowski, A. and Kushinka, G. (2004):** Anatomical and histological data on the ciliary ganglion in the Egyptian spiny mouse (*Acomys cahirinus* Desmarest). *Folia Morphol. (warsz)*. 63(3): 267-272.

- Oehme, H. (1968):** Das ganglion Ciliare der Rabenvogel (Corvidae). *Anat. Anz.*, 123: 261-277.
- Ogushi, K.C. (1913):** Zur Anatomie der Hirnnerven und des Kopfsympathicus von *Trionyx japonicus* nebst einigen kritischen Bemerkungen. *J. Morph.*, 45: 441-481.
- Osawa, G. (1898):** Beiträge zur Anatomie der *Hatteria punctata*. *Arch. F. Mikr. Anat.*, 51: 481-691.
- Paterson, N.F. (1939):** The head of *Xenopus laevis*. *Q.J. Micr. Sci.*, 81 (II): 161-234.
- Piotrowski, T.; Northcutt, R.G. (1996):** The cranial nerves of the senegal bichir, *Polypterus senegalus* (Osteichthyes: Actinopterygii: Cladistia). *Brain Behav Evol.*, 47: 55-102.
- Radzimirska, H. (2003):** The morphology, topography and cytoarchitectonics of the ciliary ganglion and the domestic turkey (*Meleagris gallopavo domesticus*). *Folia Morphol. (Warsz.)*, 62(4): 389-391.
- Ray, D.L. (1950):** The peripheral nervous system of *Lampanyctus leucopsarus*. *J Morphol.*, 87: 61-178.
- Santamaria-Arnaiz, P. (1959):** Le ganglion Ciliare chez *Chalcides ocellatus*. (Contribution à l'étude de l'anatomie comparée du système nerveux). *J. Morph.*, 101, 2: 263-278.
- Schachtschabel, A. (1908):** Der Nervus Facialis und Trigeminus des Rindes. Inaugural-Dissertation. Anatomischen Institut der Königl. Tierärztlichen Hochschule, Leipzig.
- Schwalbe, G. (1879):** Das Ganglion oculomotorii. Ein Beitrag zur vergleichenden Anatomie der Kopfnerven. *J. Z. f. Natur. W.*, 13: 173-268.
- Seto, H. (1931):** Anatomisch-histologische Studien über das Ganglion Ciliare der Vögel nebst seinen ein- und austretenden Nerven. I. Bei den erwachsenen Hühnern. *J. Oriental Med.*, 15: 123-124.
- Sinnreich, Z. and Nathan, H. (1981):** The ciliary ganglion in man (anatomical observation). *Anat Anz*, 150(3): 287-297.
- Soliman, M.A. (1964):** Die Kopfnerven der Schildkröten. *Z. F. W. Zool.*, 169: 215-312.
- Soliman, M.A. (1968):** Studies on the ciliary ganglion of Lacertilia. *Bull. Fac. Sci. Cairo Univ.*, 42: 117-130.
- Soliman, M.A. and Hegazy, M.A. (1969):** The cranial nerves of *Chalcides ocellatus*. I. The eye-muscle nerves. *Bull. Fac. Sci. Cairo Univ.*, 43: 49-62.
- Soliman, M.A. and Mostafa, R.H. (1984):** A detailed study on the cranial nerves of the gecko *Tarentola mauritanica*. I. The ciliary ganglion and eye-muscle nerves. *Proc. Zool. Soc., A.R.E.*, VII: 289-309.
- Soliman, M.A., Mahgoub, A.S., Hegazy, M.A. and Mostafa, R.H. (1976):** The ciliary ganglion and its relations in birds. *Bull. Fac. Sci. Cairo Univ.*, 48: 171-186.
- Soliman, M.A., Mostafa, R.H. and Abdel-Kader, I.Y. (1984):** Anatomical studies on the cranial nerves of *Agama pallida* (Reuss). I. The eye-muscle nerves and Ciliary ganglion. *Egypt. J. Anat.*, 8: 135-158.
- Stefani, F.H. (1972):** Further studies on "aberrant" ganglion cells in the human oculomotor nerve. *Ophthal. Res.*, 3: 46-54.
- Taylor, W.T. and Weber, R.J. (1969):** Functional mammalian anatomy (with special reference to the cat). D. van Nostrand Company, INC. Toronto, New York, London.
- Watanabe, T. (1972):** The fine structure of the ciliary ganglion of the guinea pig. *Arch. Histol. Jap.*, 34: 261-276.
- Watkinson, G.B. (1906):** The cranial nerves of *Varanus bivittatus*. *J. Morph.*, 35: 450-472.

- Webb, M. (1957):** The ontogeny of the cranial bones, cranial peripheral and cranial parasympathetic nerves, together with a study of the visceral muscles of *Struthio*. *Acta Zool.*, 38: 81-203.
- Weber, M. (1877):** Über die Nebenorgane des Auges der Reptilien. I- Die Nebenorgane des Auges der einheimischen Lacertidae. *Arch. f. Naturgesch.*, 43: 261-342.
- Willard, W.A. (1915):** The cranial nerves of *Anolis carolinensis*. *Bull. Mus. Comp. Zool.*, 59: 17-116.
- Winckler, G. (1932):** Les nerfs de l'orbite et Le ganglion ophthalmic dans la serie des mammiferes et chez l'home. *Arch. Anat. Histol. Embryol.*, 14: 301-386.