



ISSN NO. 2320-5407

Journal homepage: <http://www.journalijar.com>

INTERNATIONAL JOURNAL
OF ADVANCED RESEARCH

RESEARCH ARTICLE

Class III with Ectopically erupted canines treated by segmented T loop- A case report

Pratik Patel¹, Ravi Shanthraj², Anisha Vallakati³, Nekta Garg⁴, Bhagyalakshmi A⁵

1. Former PG student, Dept. of Orthodontics JSS Dental College and Hospital JSS University, Mysore

2. Associate professor, Dept. of Orthodontics JSS Dental College and Hospital JSS University, Mysore

3. Former PG student, Dept. of Orthodontics JSS Dental College and Hospital JSS University, Mysore

4. PG student, Dept. of Orthodontics JSS Dental College and Hospital JSS University, Mysore

5. Reader, Dept. of Orthodontics JSS Dental College and Hospital JSS University, Mysore

Manuscript Info

Manuscript History:

Received: 14 October 2015

Final Accepted: 22 November 2015

Published Online: December 2015

Key words:

T-loop, Ectopic canine, Class III,
Segmented arch technique

*Corresponding Author

Pratik Patel

Abstract

14-year old male presented with ectopically erupted upper and lower canines and unilateral Class III molar relation. First premolars extraction was planned to correct ectopic position of canines and unilateral Class III molar relation. Segmental 0.017×0.025” TMA T loop was used to retract the canines into ideal position. Post treatment results showed ectopic position of canines was corrected, bilateral Class I molar relation achieved and inclination of incisors improved. At the end of treatment, patient showed pleased smile with improved smile arc. The overall treatment took 20 months.

Copy Right, IJAR, 2015,. All rights reserved

INTRODUCTION

Ectopically erupted canines are one of the most frequently encountered conditions in orthodontic practice¹⁻². The proper position of canine shares very important role in oral function and esthetics. After the third molars, the maxillary permanent canines are the most frequently impacted or ectopically erupted teeth and reported prevalence is 1.0%–2.2%³⁻⁸. Ectopic canines are believed to occur due to wide range of systemic and local causes. Environmental factors may contribute to this anomaly due to the long, tortuous eruption path of canine. Another possible explanation is that a disturbance associated with the follicle of the unerupted tooth may influence the direction of eruption and contribute to displacement of the maxillary canine⁹. Early detection of ectopically positioned maxillary canines is important as it allows the canine to be monitored radiographically. Appropriately timed intervention could avoid root resorption on adjacent incisors. Many patients with ectopic maxillary canines show deficiency of space, extraction of premolars should be required in such cases. Segmented arch technique is found to be highly successful in treatment of such cases. It consists of multiple wires found in different portion of arch. The force system is relatively constant with long range of activation and optimum force level; thus the resultant movement is predictable¹⁰. Burstone stated that moment/force ratio; magnitude of force and force constancy determines the success of the appliance^{11, 12}. Segmented T-loop has a few important characteristics: i.e. α moment, β moment, horizontal and vertical forces¹³. Segmented retraction of canines with frictionless mechanics reduces the strain on posterior teeth¹⁴.



Fig 1: Pretreatment facial photographs

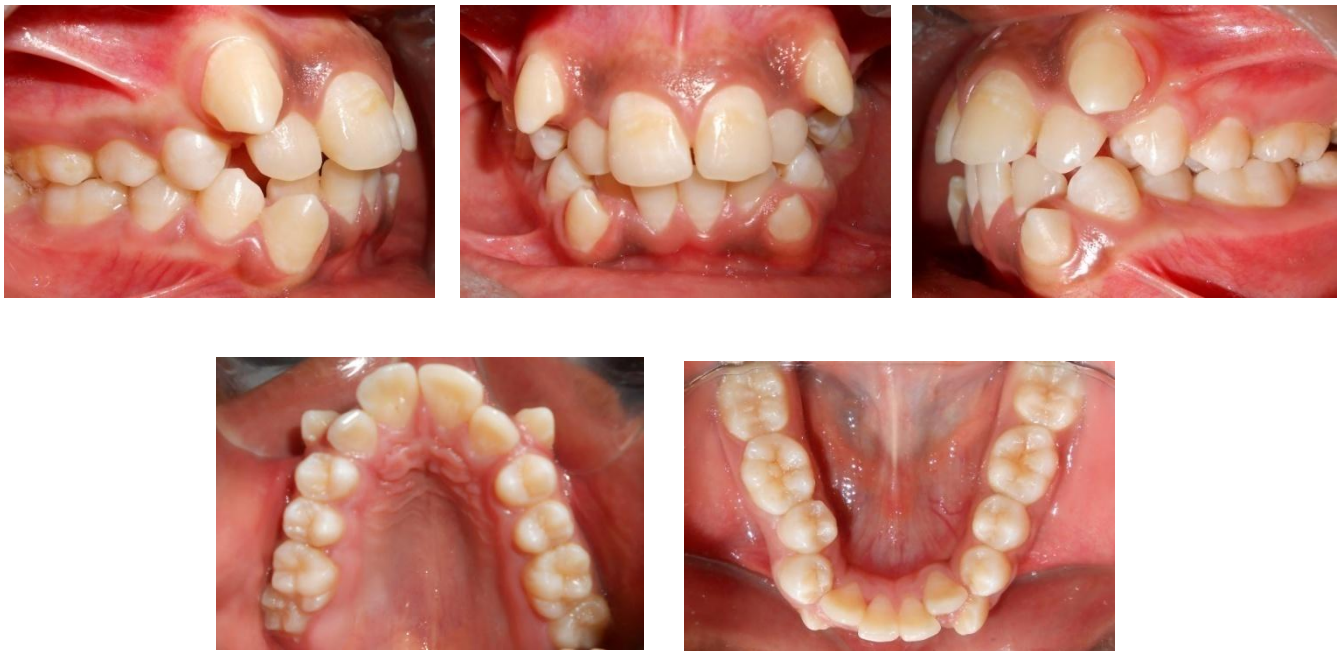

Fig 2: Pretreatment intra oral photographs

CASE PRESENTATION

14-year-old male reported with a chief complaint of irregularly placed upper and lower front teeth. The patient showed no relevant medical history. He showed skeletal Class I jaw bases, mild convex profile with average growth pattern. He had incompetent upper and lower lips, and excessive lip strain on closure (Fig 1). He showed ectopically erupted upper and lower canines and unilateral Class III molar relation. He revealed crowding of upper and lower anterior teeth, normal overjet and overbite. His lower midline was shifted to the right in relation to facial midline. (Fig 2) The panoramic radiograph showed presence of 32 teeth with no evidence of bone loss. The lateral cephalometric radiograph showed Wits appraisal of -1 mm and ANB angle of 1° , indicative of Class I skeletal jaw bases. The SN-mandibular plane angle of 32° , suggestive of average growth pattern. The patient had normally inclined maxillary and mandibular incisors with UI-NA 4 mm/ 23° and L1-NB 3.5 mm/ 22° (Fig 3).

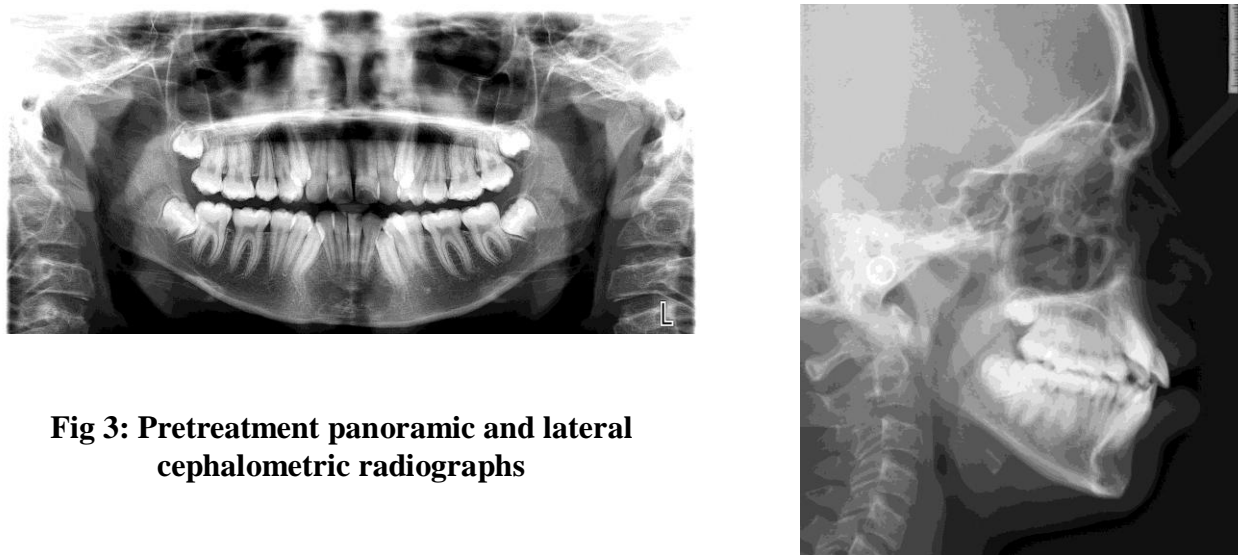


Fig 3: Pretreatment panoramic and lateral cephalometric radiographs

TREATMENT OBJECTIVES

The primary objectives were to correct ectopically erupted canines with unilateral Class III molar relation and to correct lower midline in relation to facial midline. Other objectives were to maintain the molar relation on right side, to maintain ideal overjet, overbite and achieve canine guidance with anterior disclusion.

TREATMENT PLAN

Ectopically erupted canines and unilateral Class III molar relation was the main criteria in determining the applicable treatment plan. Extraction of first premolars was planned to improve ectopic position of canines and to correct unilateral Class III molar relation. Thus group A anchorage was planned to retract the canines and prevent mesial movement of the mandibular molars. To enhance the anchorage, loop mechanics was planned along with transpalatal arch in the maxilla and lingual arch in the mandible.

Table 1. CEPHALOMETRIC FINDINGS

VARIABLE	STANDARD	PRE-TREATMENT	POST-TREATMENT
SKELETAL			
SNA	82° ± 2°	76°	76°
SNB	80° ± 2°	75°	75°
ANB	2°	1°	1°
GO GN – SN	32°	32°	32°
WITS APPRAISAL	0 mm	-1 mm	-1 mm
DENTAL			
U1 – SN	102° ± 2°	105°	104°
U1 – NA	4 mm / 22°	4 mm / 23°	4.5 mm / 26°
L1 – NB	4 mm / 25°	3.5 mm / 22°	4 mm / 24°
IMPA	92° ± 5°	89°	91°
SOFT TISSUE			
NASOLABIAL ANGLE	98 mm	91°	92°
U LIP – S LINE	0 mm	2 mm	2 mm
L LIP – S LINE	0 mm	2 mm	2 mm

TREATMENT PROGRESS

MBT appliance with 0.022×0.028" slot (Ormco, Glandora, CA) was used. A transpalatal arch in the maxilla and lingual arch in the mandible was placed on banded first molars to enhance the anchorage. Alignment and leveling of anchor teeth was done with progressive archwire change. After alignment and leveling, sectional 0.019×0.025" stainless steel archwires placed in posterior segments and Segmented 0.017×0.025" TMA T loop was employed at the bracket of ectopic canine and accessory molar tube. T loop was activated by 3 mm at subsequent appointments. The

activation was done by pulling the distal arm and cinching it distal to the first molar. The canines started moving distally. Complete retraction of individual canine was achieved in a period of 7 months. After individual canine retraction, alignment and leveling was accomplished with following sequence of archwires: (a) 0.016" heat activated nickel-titanium archwires (b) 0.018" stainless steel archwires and (c) 0.017×0.025" stainless steel archwires. The archwires were cinched distal to molar to avoid maxillary and mandibular incisor proclination. Class III elastics were used to correct unilateral left Class III molar relation on 0.017×0.025" stainless steel archwires. Simultaneously diagonal elastics were used to correct lower midline in relation to facial midline. After molar and midline correction, arches were coordinated on 0.019×0.025" stainless steel archwires. A 0.021×0.025" titanium molybdenum alloy archwire was placed for two months. Finishing and detailing was carried out by 0.021×0.025" braided stainless steel archwires. The treatment was completed in twenty months. Maxillary and mandibular anterior bondable lingual retainer was given and the case was debonded. The patient is being recalled every six months for check up.

TREATMENT RESULT

The change in the patient's smile was the most impressive part of his treatment. With extraction of the first premolars, 7 mm retraction of upper and lower canines was achieved (Fig 4). The Class III molar relation was fixed into Class I relationship, ideal overjet and overbite was maintained. The vertical dimension of face was maintained during orthodontic treatment. Post treatment intraoral photographs and lateral cephalogram (Figs 5-6) showed that the maxillary and mandibular incisors were inclined appropriately. The panoramic radiograph (Fig 6) showed adequate root parallelism in both upper and lower arches.



Fig 4: Posttreatment facial photographs

DISCUSSION

Ectopic eruption and impaction of canines is a commonly seen clinical problem. The incidence of impaction ranges between 1 % and 3%. The cause of canine impaction can be the result of localized factors or can be a polygenic multifactorial inheritance and associated with other dental anomalies¹⁰. There are a number of possible sequelae to canine impactions, ranging from loss of space in the arch to resorption of the roots of the neighboring teeth. Eighty-five per cent of impacted maxillary permanent cuspids are palatal impactions, and 15% are labial impactions^{1,4,15}. Inadequate arch space and a vertical developmental position are often associated with buccal canine impactions.¹⁵ If buccally impacted cuspids erupt they do so vertically, buccally and higher in the alveolus.¹⁵ Due to denser palatal bone and thicker palatal mucosa, as well as a more horizontal position, palatally displaced cuspids rarely erupt without requiring complex orthodontic treatment.¹⁶ Palatally erupting or impacted maxillary canines occur twice as often in females than males, have a high family association and are 5 times more common in Caucasians than Asians.^{16,17} It is not unusual for maxillary canine impaction to occur bilaterally, although unilateral ectopic eruptions are more frequent.¹⁸ Although the management of the ectopically erupting teeth necessitates the combined expertise of a number of clinicians, the orthodontist should have the primary responsibility of coordinating these efforts to provide

the patient with the optimal treatment options with the most stable and favorable outcome. Treatment options for the management of impacted teeth are separated into four categories: observation, intervention, relocation and extraction¹⁹⁻²¹.

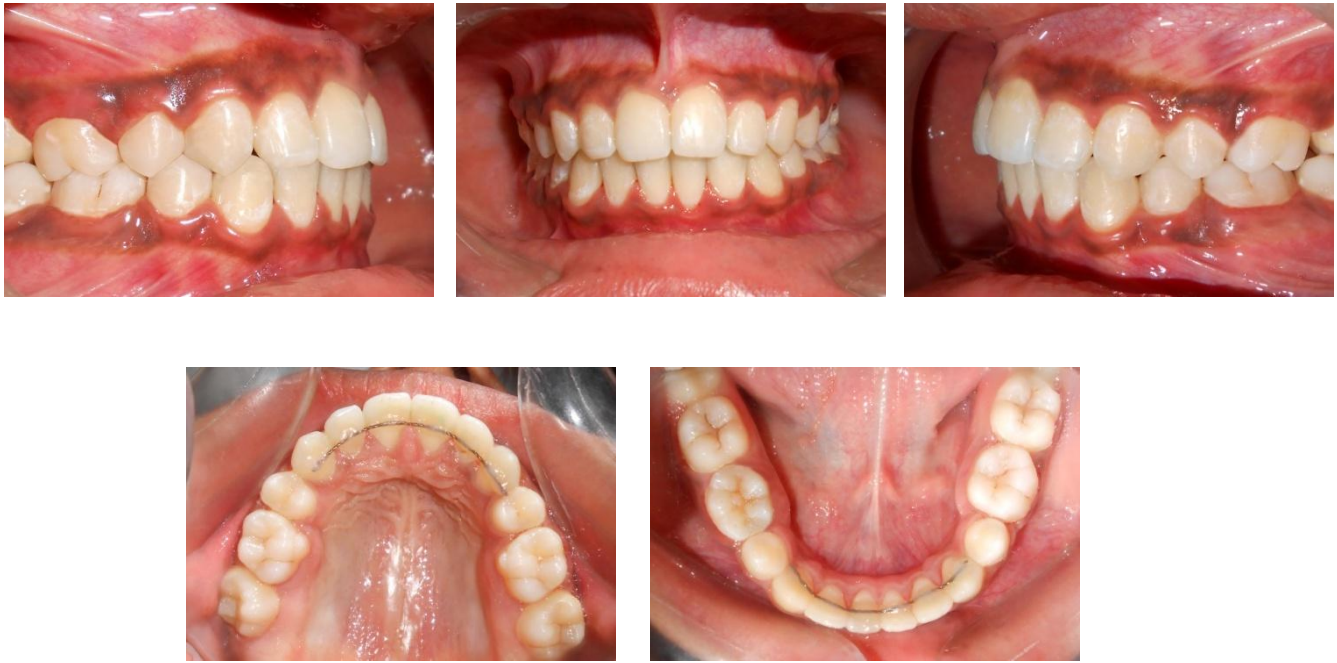

Fig 5: Posttreatment intraoral photographs

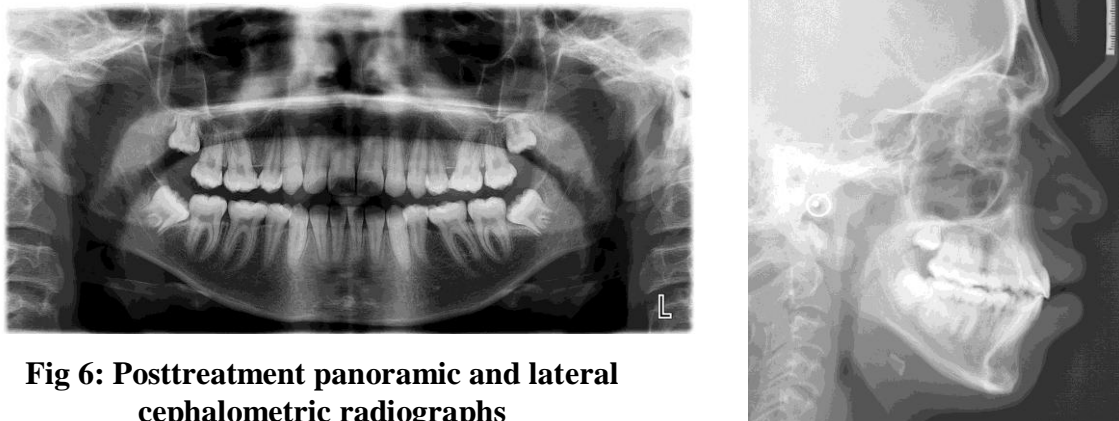


Fig 6: Posttreatment panoramic and lateral cephalometric radiographs

The segmented 0.017×0.025" TMA T-loop was used to retract ectopically positioned canines. Segmented TMA T-loop showed three dimensional controls²². Segmented T-loop served as a retraction spring, which offered not only a distal driving force on the canine but also a moment for anti-distal tipping as well as torque control of canine²³⁻²⁵. As the retraction progressed, the ectopic tooth was moved distally from root of lateral incisor. In the last stage, a vertical component of force operating on the canine became more desirable. Hence segmented T loop was adjusted to exert an extrusive force to bring the canine toward the occlusion but it produced reciprocal intrusive forces on the molar which is anticipated with 0.019×0.025" stainless steel wire in posterior segment and transpalatal arch in maxilla and lingual arch in mandible. Once the ectoically erupted canine were positioned into their ideal positioned, Class III elastics were used to correct unilateral Class III molar relation. Simultaneously, midline was corrected with diagonal elastics in relation to facial midline.

CONCLUSION

Ectopically erupted canines are frequently associated with arch length deficiency. Extraction of four first premolars is extremely successful in correcting position of ectopic erupted canines. Segmented 0.017×0.025" TMA T-loop is very useful in retraction of highly placed canines. Differential moments are generated with T loop which augment the anchorage.

ACKNOWLEDGEMENT

The authors wish to acknowledge Dr. Shivalinga BM & Dr. H. Jyothikiran Dept. of Orthodontics, JSS University, Mysore for their guidance.

REFERENCES

1. Bass TB. Observation on the misplaced upper canine tooth. *Den Pract*, 18:25-37, 1967.
2. Harry Jacoby. The etiology of maxillary canine impactions. *Am J Orthod*, 84:125-132, 1983.
3. Dachi SF, Howell FV. A survey of 3874 routine full mouth radiographs. II. A study of impacted teeth. *Oral Surg Oral Med Oral Pathol*. 1961; 14:1165-69.
4. Thilander b, jakobsson So. Local factors in impaction of maxillary canines. *Acta Odontol scand*. 1968; 26:145-168.
5. Kramer RM, Williams AC. The incidence of impacted teeth. A survey at Harlem Hospital. *Oral Surg*. 1970;29:237-41.
6. Thilander B, Myberg N. The Prevalance of malocclusion in Swedish school children. *Scand J Dent Res*.1973;81:12-20.
7. Ericson S, Kurol J. Longitudinal study and analysis of clinical supervision of maxillary canine eruption. *Community Dent Oral Epidemiol*. 1986;14:172-176.
8. Ericson S, Kurol J. Radiographic assessment of maxillary canine eruption in children with clinical signs of eruption disturbance. *Eur J Orthod*. 1986;8:133-40.
9. Fearn J, Lee RT. Favorable spontaneous eruption of severely displaced maxillary canines with associated follicular disturbance. *Br J Orthod* 1988;115:93-98.
10. Burstone CJ. Rationale of the segmented arch. *Am J Orthod* 1962 Nov;48(11):805-822.
11. Burstone CJ. Baldwin JJ. Lawless DJ. The application of continuous forces to orthodontic. *Angle Orthod* 1961;31:1-14.
12. Burstone CJ. The mechanics of segmented arch techniques. *Angle Orthod* 1966;36:99-120.
13. Burstone. Charles J, van Steenberg, Edsard. *Modern edgewise mechanics and the segmented arch technique*. USA: Farmington. Conn:University of Connecticut Health Center;1995.
14. Brandt S. Burstone CJ. JCO/interviews Dr Charles j Burstone. *J Clin Orthod* 1972 Dec;6(12):694-708.
15. Rayne J. The unerupted maxillary canine. *Dent Pract Dent Rec* 1969; 19:194-204.
16. Bishara SE. Impacted maxillary canines: a review. *Am J Orthod Dentofacial Orthop* 1992; 101:159-71.
17. Peck S, Peck L, Kataja M. The palatally displaced canine as a dental anomaly of genetic origin. *Angle Orthod* 1994; 64:249-56.
18. Shapira Y, Kuftinec MN. Early diagnosis and interception of potential maxillary canine impaction. *J Am Dent Assoc* 1998; 129:1450-4.
19. Pratik Patel, Anisha Vallakati, Ravi Shanthraj. *Management of impacted canine*. Lambert Academic Publishing; 2015.
20. Ericson, Sune, and Jüri Kurol. "Early treatment of palatally erupting maxillary canines by extraction of the primary canines." *The European Journal of Orthodontics* 1988;10, no. 1: 283-295.
21. Frank, C. A. Treatment options for impacted teeth. *Journal of the American Dental Association*. 2000;131.5: 623.
22. Burstone, Charles J., and A. Jon Goldberg. Beta titanium: a new orthodontic alloy. *American journal of orthodontics* 1980;77.2:121-132.
23. Tanne, Kazuo, Herbert A. Koenig, and Charles J. Burstone. Moment to force ratios and the center of rotation." *American Journal of Orthodontics and Dentofacial Orthopedics* 1988;94.5: 426-431.
24. Burstone, Charles J., and Herbert A. Koenig. Force systems from an ideal arch. *American journal of orthodontics* 1974;65.3:270-289.
25. Burstone, Charles J. The biomechanics of tooth movement. *Vistas in orthodontics*. Lea & Febiger Philadelphia 1962;197-213.