



ISSN NO. 2320-5407

Journal homepage: <http://www.journalijar.com>

INTERNATIONAL JOURNAL
OF ADVANCED RESEARCH

REVIEW ARTICLE

Mandibular Advancement Therapy In Obstructive Sleep Apnea- A REVIEW.

¹. Dr. Parag Deshmukh, ². Dr. Sunita Shrivastav, ³. Dr. Ranjit Kamble, ⁴. Dr. Sumita Jain

1. P.G Third Year, Department: Orthodontics and DentofacialOrthopaedics, Institute: SharadPawar Dental College and Research Centre, (DattaMeghe Institute of Medical Sciences), India.
2. Professor and Head of Department , Department: Orthodontics and DentofacialOrthopaedics, Institute: haradPawar Dental College and Research Centre, (DattaMeghe Institute of Medical Sciences), India.
3. Professor, Department: Orthodontics and DentofacialOrthopaedics, Institute: SharadPawar Dental College and Research Centre, (DattaMeghe Institute of Medical Sciences), India.
4. P.G Third Year, Department: Orthodontics and DentofacialOrthopaedics, Institute: SharadPawar Dental College and Research Centre, (DattaMeghe Institute of Medical Sciences), India.

Manuscript Info

Manuscript History:

Received: 14 October 2015
Final Accepted: 25 November 2015
Published Online: December 2015

Key words:

*Corresponding Author

Dr. ParagDeshmukh

Abstract

The snoring sound is produced by the vibration of the soft palate and other oropharyngeal tissues and there is narrowing of upper airway causing obstruction. It can become a medical concern because it is a key symptom of obstructive sleep apnea syndrome (OSA). A mandibular splint or mandibular advancement splint (MAS) is a device worn in the mouth that is used to treat OSA, snoring, and TMJ disorders. These devices are also known as mandibular advancement devices, sleep apnea oral appliances, oral airway dilators and sleep apnea mouth guards.

Copy Right, IJAR, 2015,. All rights reserved

INTRODUCTION

The snoring sound is produced by the vibration of the soft palate and other oropharyngeal tissues and there is narrowing of upper airway causing obstruction. ^{1,2}The most commonly encountered impedance of airflow is upper airway obstruction, which is most often secondary to morphologic, pathologic, or functional abnormalities of the airway. ³It can become a medical concern because it is a key symptom of obstructive sleep apnea syndrome (OSA). Cessations of breathing for ten seconds or longer are termed as apneas (from the Greek - without breath). When thirty or more apneic episodes occur in the course of seven hours of sleep, resulting in excessive sleepiness during the waking hours, a person is described as having sleep apnea syndrome. This condition may begin at any age, but the incidence increases as the age advances. Apnea results from partial or complete interference with this process.

Another factors that may reduce the airway or pharyngeal airway volume are mandibular size and position which is most commonly found in skeletal Class II vertical growers. ⁴ Lateral cephalometric studies have been used in an attempt to analyze and identify mandibular morphologic parameters like retrognathia of the mandible alone ⁵ and increased mandibular plane angle ⁶ that might be characteristic in adult patients with breathing disorders like OSA, snoring etc. The influence of reduction in size of nasopharyngeal airway leading to reduction in morphology of the mandible has been studied in the past on monozygotic twins. ⁷ The inter-relationship of mandible, tongue and airway has been studied in Pierre Robin sequence. ⁸ The airway volume is altered in such cases and all treatment modalities try to achieve proper airway functioning directly or indirectly.

Treatment modalities:

Various methods are suggested to improve the skeletal Class II pattern which will ultimately improve the caliber of airway, reducing the chances of airway related disorders. In prepubertal cases the myofunctional appliance with varying degree of advancement and vertical opening have been used to alter the growth of mandible and

associated musculature which will bring about an alteration in the airway spaces. Post pubertal this treatment modality changes to a surgical intervention like uvulopalatopharyngoplasty, advancement bilateral sagittal split osteotomy, etc. In severe obstructive sleep apnea cases continuous positive airway pressure is another treatment of choice. Now a days removable intraoral appliances directed at mandibular advancement are gaining popularity as a treatment of choice in obstructive sleep apnea. In present article we are going to discuss about MAD's.

Dental Appliances

The Continuous Positive Air Pressure (CPAP) procedure can be very effective, however many patients find the mask too uncomfortable to wear while sleeping. In addition, Continuous Positive Air Pressure (CPAP) may produce number of side effects and besides it has obvious esthetic drawbacks, as it must be worn throughout the night. All these disadvantages created a need for an alternative conservative treatment modality Differences were found in the craniofacial structure of OSA subjects and normal subjects in various studies conducted. These findings led to the promotion of dental devices as alternative, noninvasive and conservative modality for OSA.⁹ Because the objective of treatment is to increase the airway diameter and decrease airway resistance, devices are designed to increase the pharyngeal airway by protruding the mandible and increasing the vertical dimension of occlusion. Since orthodontists have experience with removable appliances they are asked to place these intraoral devices. Since Pierre Robin first described his monobloc appliance in 1902 for treatment of glossoptosis (tongue falling back and occluding the airway) in infants several appliances have been used for treatment of upper airway obstructions. The monobloc was also the precursor to many functional appliances currently used in orthodontics to modify growth and assist in the alignment of teeth.

Mechanism of Action

Dental devices produce changes in the shape and function of the upper airway during sleep. The effects of airway dimension have been assessed by cephalometric radiography which gives a two dimensional view of the airway, typically in the awake upright position, The technique is limited in its ability to fully document three-dimensional changes during sleep. Alternative approaches have included CT to MR imaging of the upper airway or video endoscopy, all of which potentially can provide more information about three-dimensional changes with therapy

There are 4 basic categories of dental appliances used in treatment of obstructive sleep apnea categorized by mode of action.

Class

1. Soft palate lifters
2. Tongue posture trainer
3. Tongue retainer
4. Mandibular repositioner

(MAA) Anterior Mandibular Positioner (AMP) / Mandibular Advancement Splint (MAS)

Although data on the efficacy of mandibular advancement appliance in treatment of snoring and OSAS are conflicting, their use in the treatment of habitual snoring and mild obstructive sleep apnea has gained increased attention and acceptance. Numerous studies exist proposing various designs of appliances for treatment of OSA.

The first kind of appliance was reported in 1987 by George P.T. NAPA (Nocturnal Airway Patency Appliance), which the author had designed, later in 1988 Rider AE reported the use of Herbst type appliance for treatment of OSA.¹⁶

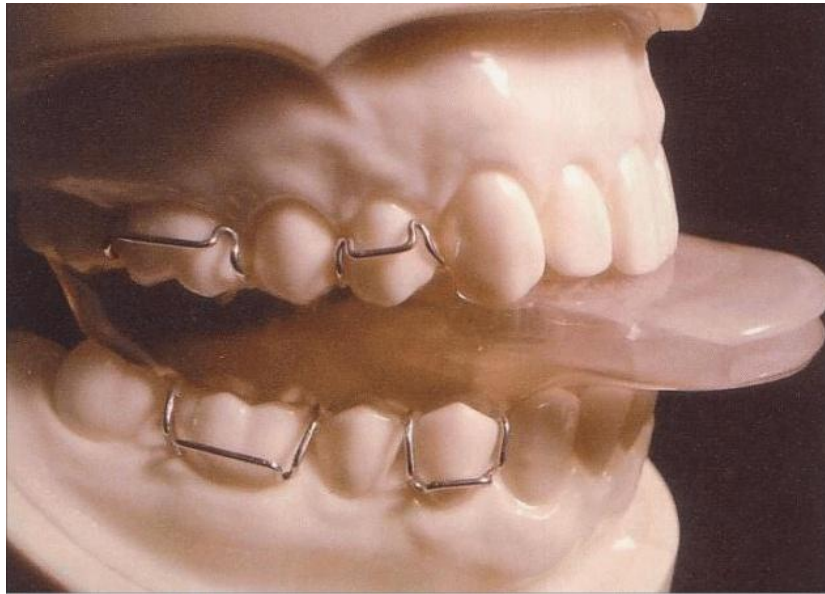


Figure 1:Nocturnal Airway-Patency Appliance

Even if there are several kinds of mandibular advancement appliances they all share a common functional mechanism. The upper airway is determined by soft tissue and skeleton factors that are also major determinants of airway patency. The effect of the oral appliance is based on creating anterior position of mandible by several millimeters while passively bringing the tongue with it thereby keeping pharyngeal air space patent during sleep.

The rationale for this movement is that the tongue is attached to the genial tubercles of the mandible, thus positioning the mandible forward moves the tongue forward. These mandibular repositioning also change hyoid bone positions and modify the lower airway space below the level of the tongue. The typical magnitude of anterior advancement is in the range of 60-90% of the patients maximum protrusive jaw motion which is usually 5-9 millimeters. Cephalometric studies, have shown that besides the above changes there is change in configuration of tongue and uvula¹⁰.

The second less endorsed theory is that the device causes stretch induced activation of Pharyngeal motor system. This motor activation provides enough stiffness to, the system to prevent collapse of the airway. This theory has been supported by the observation that electromyographic activity of the tongue has been shown to increase with AMP.

Another alteration that has been shown to occur with the mandibular advancement device is the opening of the pharyngeal orifice.

At present many models of Mandibular Advancement Devices (MAD) are available. They can be either fixed or adjustable, one piece or two piece devices. In general they consist of firm fitting trays that fit over the maxillary and mandibular teeth. The adjustable devices position the mandible forward and are secured to the maxilla by the use of thermoplastic buttons, interarch elastics, buccal tube and rod attachment (Herbst) and a screw mechanism with which to titrate the oral appliance. They are preferred to non adjustable as they can be adjusted to patient comfort. With either of them the initial position of mandible is generally 70 to 75% of maximum protrusion relative to maximum retrusion. Almost all Mandibular Advancement Devices (MAD) require that the patient have sufficient number of teeth so that the device will be highly retentive generally in one or both the arches specially the maxillary arch. Anterior breathing holes may be necessary to allow oral respiration in some patients specially those with

restricted nasal airflow¹¹

Recent innovations include combining the principals and use of CPAP with oral appliance therapy. In one instance the pressurized air is delivered through the oral appliance directly into the mouth through oral positive pressure. In another the oral appliance is used in lieu of head gear to retain the air hose as well as deliver pressurized air directly into the nares thereby reducing any leakage from the borders of the CPAP mask.

Soft palate lifter

In case the airway occlusion is posterior to the soft palate (Type I occlusion), the mandible should be postured down and forward to hypothetically allow the anterior displacement of tongue and create sufficient space for soft palate to move forward. The soft palate lifter is an intraoral device designed to lift the soft palate, or reposition the uvula (equalizer). The rationale for use of palate lifting devices is to reduce the vibration of the soft palate that causes the snoring sound.

Efficacy of Oral Appliances.

Bonham et al, Johnson et al, Battagal J.M. et al, Schmidt- Nowara et al showed an increase in the posterior air way space with the device. Eveloff et al however found no change.^{12, 13}

Battagal J.M. et al said mechanism of success of mandibular advancement devices was multifactorial. Cephalometric radiography and fluoroscopy have demonstrated that when mandible is advanced the tongue and hyoid bone also move anteriorly increasing upper airway space.

Ferguson et al have reported mandibular protrusion increased cross sectional area of hypopharynx and oropharynx whereas tongue protrusion increased cross sectional area of all three regions of the pharynx.¹⁴

American Sleep Disorders Association in 1997 commissioned a review of all the articles written about oral appliance therapy for obstructive sleep apnea and snoring. The review found that in all published studies in which snoring was assessed, snoring improved in 73% - 100% of patients using a variety of appliances.

Several studies by Eveloff SE et al, Lowe AA et al, O Sullivan et al, Schmidt Nowara et al have found that treatment success is inversely related to initial AHI, patients with severe disease did not have as good a response as those with mild to moderate disease. There does not appear to be a placebo effect with an oral appliance. The mere presence of an appliance in oral cavity does not lead to improvement in sleep apnea, forward movement of tongue or mandible must be present.

Markland et al found Mandibular Advancing devices satisfactorily treated 8% of the patients with mild apnea, 60% of those with moderate apnea, but only 25% of those with severe sleep apnea.

J.A. Parker reported success rate of 90% for those with slight to moderate disease and 60% for those with moderate to severe disease.

Design Features Of Mandibular Advancement Device (MAD):

Despite the wide variety oral appliances described most study groups have been small and very few indications as to which design features are important to success. Johal et al based on experience believes that the following principles should be adhered to for reasons given below: -

1. A healthy dentition & supporting periodontium.
2. Sufficient protrusion to maintain airway patency, that is one should aim to achieve maximum comfortable protrusion. This is often 50-75% of subject's maximum protrusion. In this respect MAD that allows incremental advancement offers clear advantage eg - removable Herbst and Silencer appliance.
3. Minimal vertical opening: A MAD which promotes mandibular opening results in downward and backward rotation of mandible with concomitant posterior movement of both tongue and soft palate. This may negate benefits to the airway from protrusion.
4. It is important that there be enough space in the pharynx to allow the appliance to work. A patient with extremely deep-set palate and long uvula and enlarged tonsils may not be a good candidate.
5. Full occlusal coverage: This should prevent any unwanted changes in the occlusion resulting from eruption of unopposed teeth.
6. Incorporation of anterior opening in the splint: This is particularly helpful for those subjects who are mouth breathers and are provided with a vacuum formed one-piece device. Generally two piece is preferred.¹⁵ Fabrication of the Mandibular Advancement Device Obtain accurate maxillary and mandibular master casts with an irreversible hydrocolloid impression material.

Method:

- 1) Block out hard and soft tissue undercuts on master casts with block out wax.
- 2) Duplicate blocked out master casts with reversible or irreversible hydrocolloid.
- 3) Make a wax interocclusal record. The wax bite should position the mandible symmetrically forward at a distance of at least 50% of the patient's maximum protrusive movement (about 5-8mm). Patients should be given at least 15 to 20 minutes to accommodate to this position so as to assess if there are any signs of temporomandibular joint discomfort.
- 4) Cephalograms may be taken at this stage to assess the spatial changes in the oropharynx.
- 5) With the wax record, the master casts are mounted and the duplicate casts with the undercut blocked out are cross-mounted on a semi adjustable articulator.
- 6) The mounted duplicate cast that has been painted with two coats of tin foil substitute is then waxed with base plate wax. The wax should overlap the incisal edges and buccal surfaces 3mm and extend into the soft tissue palatolingually. Leave 1 to 2 mm separation between maxillary and mandibular surfaces to facilitate joining the two portions after processing.
- 7) Invest by traditional flasking procedure in heat cured clear acrylic.
- 8) After deflasking, polish the appliance on the external surface and fit each portion on the master cast before joining the two pieces.
- 9) If one piece appliance design is used, labial guide plate is also suggested to ensure that the jaws do not retrude as long as the mouth is not opened wide, as clasps always don't retain the teeth together.
- 10) If two piece appliance is used labial plate is not necessary as they can be held together with tube and rod attachment or bilateral interarch elastic to keep the jaws closed.
- 11) In some design visible light curing resin is used to join the maxillary and mandibular portions on the articulator. A small orifice is kept anteriorly for ventilation.
- 12) Instruct the patient on insertion and care of the appliance.

Advantages of Mandibular Advancement Splint Therapy

1. Improvement in sleep quality and daytime.

2. Patients with bruxism may not tolerate rigid fixation of their jaws. A design alternative using a separate two piece appliance with intra arch elastics and tube and rod attachment to allow side to side movement, jaw opening and forward movement is available.
3. Relatively inexpensive compared with the costs associated with other non- surgical and surgical treatment modalities.
4. Readily accessible.
5. Non invasive and reversible in contrast to surgical treatment.
6. Overall compliance is good.
7. Mandibular positioners maintain continuous mandibular and tongue posture as they are designed to allow continuous breathing and are more esthetic than Tongue Retaining Devices Treatment

Disadvantages of Mandibular Advancement Splints

Short term side effects:

1. These include discomfort in the muscles of mastication, excessive salivation and an abnormal bite on awakening. These effects appear to be transient without any lasting complications.
2. Since mandibular positioner requires the patient to maintain a forward jaw position all night (7 to 8 hours) it could have side effects on temporomandibular joint such as a temporomandibular joint remodeling and subsequent dysfunction.
3. It is also possible for occlusal changes to occur from these appliances. However minor changes have been observed in the over jet, overbite, molar relationship and mandibular position which require further evaluation.

Conclusion:

Oral appliance therapy improves upper airway collapsibility during sleep in patients with OSA. Treatment success with MAS is not achievable in every patient, further research is needed to determine the effects of MAD on OSA and snoring. A regular follow up of the patient using MAD's is recommended as its use may lead to orthodontic problems.

References:

1. Suratt PM, Dee P, Atkinson RL, Armstrong P, Wilhoit SC; Fluoroscopic and computed tomographic features of the pharyngeal airway in obstructive sleep apnea. *Am Rev respir Dis* 1983; 127:487-92.
2. Lugaresi E, Coccagna C, Farneti P, Mantovani M, Cirignotta F. Snoring. *ElectroencephalogrClinNeurophysiol* 1975; 39:59- 64
3. Cote EF. Obstructive sleep apnea – an orthodontic concern; *Angle Orthod.* 1998 Oct; 58(4); 293-307.
4. Solow B, Skov S, Ovesen J, Norup PW, Wildschiodtz G. Airway dimensions and head posture in obstructive sleep apnoea. *Eur J Orthod.* 1996 Dec; 18(6): 571-9.

5. Jamieson A, Guilleminault C, Partinen M, Quera-Salva MA. Obstructive sleep apneic patients have craniomandibular abnormalities. *SLEEP*. 1986 Dec; 9(4): 469-77.
6. AA, Santamaria JD, Fleetham JA, Price C. Facial morphology and obstructive sleep apnea. *Am J OrthodDentofacialOrthop*. 1986 Dec; 90(6): 484-91.
7. Dunn GF, Green LJ, Cunat JJ. Relationships between variation of mandibular morphology and variation of nasopharyngeal airway size in monozygotic twins. *Angle Orthod*. 1973 Apr; 43(2): 129-35.
8. Figueroa AA, Glupker TJ, Fitz MG, BeGole EA. Mandible, tongue, and airway in Pierre Robin sequence: a longitudinal cephalometric study. *Cleft Palate Craniofac J*. 1991 Oct; 28(4): 425-34.
9. Pracharaktam N, Nelson S, Hans MG, Broadbent BH, Redline S, Rosenberg C, et al. Cephalometric assessment in obstructive sleep apnoea. *Am J OrthodDentofacorthop* 1996;109(4):410-9.
10. Robertson C, Herbison P, Hurkress M. Dental and occlusal changes during mandibular advancement splint therapy in sleep disordered patients. *Eur J Orthod*.
11. Clark GT, Sohan JW, Hong CN. Treating obstructive sleep apnea and snoring: assessment of an anterior mandibular positioning device. *J Am Dent Asso* 2000; 131:765-771.
12. Nowara WS, Lowe A, Wiegand L, Cartwright R, Guerra FP, Stuart M. Oral appliances for the treatment of snoring and obstructive sleep apnea: a review. *Sleep*.
13. Nowara WS, Meade TE, Hays MB. Treatment of snoring and obstructive sleep apnea with a dental orthosis. *Chest* 1991 ;99(6):1378-85.
14. Ferguson KA, Ono T, Lowe AA, Al-Majed S, Love LL, Fleetham JA. A short term controlled trial of an adjustable appliance for the treatment of mild to moderate obstructive sleep apnoea. *Thorax* 1997;52:362-8.
15. Bondemark L. Does two years nocturnal treatment with a mandibular advancement splint in adult patients with snoring and obstructive sleep apneas cause a change in the posture of the mandible? *Am J OrthodDentofacorthop*.
16. Warunek SP. Oral appliance therapy in sleep apnea syndromes: a review. *Seminars in Orthodontics* 2004;10(1):73-89.